

Identification of Ectoparasites and Endoparasites on Java Langurs (*Trachypithecus* sp.) and Silvery Gibbons (*Hylobates moloch*) in The Aspinall Foundation Indonesia Program

¹⁾Ghifari Lutfi Fauzi, ²⁾Endang Suprihati^{ID}, ²⁾Poedji Hastutiek, ³⁾Boedi Setiawan, ⁴⁾Retno Wulansari

¹⁾ Student, Faculty of Veterinary Medicine, Universitas Airlangga, ghifarilutfifauzi@gmail.com

²⁾ Division of Veterinary Parasitology, Faculty of Veterinary Medicine, Universitas Airlangga

³⁾ Division of Veterinary Clinic, Faculty of Veterinary Medicine, Universitas Airlangga

⁴⁾ Veterinary Internal Medicine Division, Department of Clinic, Reproduction and Pathology, Faculty of Veterinary Medicine, IPB University

Corresponding author: esuprihati@yahoo.co.id

Abstract

This study aimed to determine the prevalence rate and to identify parasites (endoparasite and ectoparasite) on Java Langur and Silvery Gibbon, these primates are rehabilitated in The Aspinall Foundation Indonesia Program. This research was conducted from February until October 2020. The fecal examination methods used in this research were native method and ovatec flotation method, while the ectoparasite examination used native method, mounting method, and scraping method. Based on a total of 68 samples examined, the result showed that 10 samples were positive infected by *Trichuris trichiura* and 2 samples were infested by *Pedicinus ancoratus*. The conclusion of this study indicated that the prevalence rate of *Trichuris trichiura* was 21.1% and *Pedicinus ancoratus* was 5.3% on 19 West Java Langurs, the prevalence rate of *Trichuris trichiura* was 3.3% and *Pedicinus ancoratus* was 3.3% on 30 East Java Langurs, the prevalence rate of *Trichuris trichiura* was 26.3% and no infestation of *Pedicinus ancoratus* was found on 19 Silvery Gibbons.

Keywords: Ectoparasite, Endoparasite, Java Langur, Silvery Gibbon, prevalence, primate

Introduction

Indonesia is a country with a high potential regarding wildlife diversity (Hanafiah *et al.*, 2018). Moreover, almost 25% of the world's primate species are found in Indonesia and 24 of them are categorized as endemic primates (Fauzi *et al.*, 2017). The distribution of primate populations in Indonesia is quite wide (Comanesi *et al.*, 2017). Java Island has various endemic primate species, including the Java Gibbon (*Hylobates moloch*) and Java Lutung (*Trachypithecus* sp.). Java langur based on differences in hair color are divided into two, namely the West Java langur (*Trachypithecus mauritius*) and the East Java langur (*Trachypithecus auratus*) (Brandon-Jones, 1995).

Hunting for wildlife, deforestation, habitat loss due to fragmentation and death caused by disease can also disrupt and affect the stability of primate populations, so efforts are needed to preserve them so that they do not become extinct in the future (Astriani *et al.*, 2015). Animal rehabilitation centers that concentrate on treating primates in Java include the Java

Primate Rehabilitation Center (JPRC) in West Java and the Java Langur Center (JLC) in East Java which organized by The Aspinall Foundation. This conservation program is generally known as The Aspinall Foundation Indonesia Program (Wedana *et al.*, 2013).

Parasitic disease is one of the diseases that can infects Primates. Joesoef *et al.* (2018) stated that parasitic transmission occurs due to interactions between humans and primates. These interactions can be established in several aspects, such as ecology, work, recreation and research. Kurniawati *et al.* (2020) stated that non-human primates including Java langur and Java gibbon can become reservoirs and potential hosts for transmitting parasitic diseases that can be found in humans. Huffman *et al.* (2013) stated that 33 species of zoonotic parasites were detected in humans in Sri Lanka and five species of them, such as *Balantidium coli*, *Plasmodium* spp., *Sarcocystis* sp., *Bertiella studeri* and *Echinococcus granulosus* were reported to originate from primates considered as reservoir hosts.



Individual body condition and health status can also be affected by the presence of ectoparasites and thus affect the health of the population. Klein *et al.* (2018) stated that high ectoparasite infestation can cause the host to get additional external stressors and have a severe impact on parasite infection. Ectoparasites also need to be watched out for because they have potential as vectors for pathogen transmission. Non-human primates have an important role because they have a phylogenetic closeness to humans, therefore it is very important to increase knowledge about parasites in wildlife.

Materials and Methods

The samples used in this study were faecal samples from 68 primates. The total number of animals in the JLC is 25 East Java langurs, while the total number of animals in the JPRC is 43 consisting of 19 West Java langurs, 5 East Java langurs and 19 Java gibbons.

Examination of fecal samples was carried out using the native method and the ovatec flotation method to detect gastrointestinal endoparasites such as protozoa and worm eggs, while the examination of ectoparasites followed the schedule of animal medical check-up. The method used for examination of ectoparasites is the mounting method without staining for lice, ticks and fleas. Moreover, if a scab lesion is found, the scraping method is carried out followed by the microscopy method for mite examination.

The observed variables were the presence or absence of gastrointestinal endoparasites and ectoparasites in Java gibbons and Java langurs, then identified. Determination of parasite

species using morphological identification keys according to Foreyt (2001), Ash and Orihel (2007), Mey (2010), Bowman (2014), Taylor *et al.* (2016) and Durden *et al.* (2020). The data obtained were then analyzed descriptively. Syukran *et al.* (2017) stated that the prevalence rate can be calculated by the following formula:

$$\text{Prevalence (\%)} = \frac{\text{Number of positive samples}}{\text{Total samples}} \times 100$$

Results and Discussion

The results of the examination of digestive tract endoparasites and ectoparasites in West Java Lutung, East Java Langur and Java Gibbon (Table 1) conducted on 68 primates rehabilitated at JLC and JPRC in February - October 2020 found nematode worm eggs in one East Java Langur. , four West Java langurs and five Java gibbons. Worm eggs were identified as the genus *Trichuris*, while ectoparasite examination found lice in one West Java Langur and East Java Langur. The tick was identified as the genus *Pedicinus*. Infestation of ticks, mites and fleas were not found on examination of ectoparasites, and no infection with gastrointestinal protozoa was found on examination of feces. All positive samples only detected for single infestation.

The results of the fecal examination using native and floating method showed that there was an infection of worm eggs with an oval shape resembling a lemon, coated with egg cell walls and there was a brownish colored embryo inside, and had symmetrical polar plugs on both ends, which indicated *Trichuris trichiura* species. The worm egg morphology can be seen in Figure 1.

Table 1 Results of examination of gastrointestinal endoparasites and ectoparasites in West Java Langurs, East Java Langurs and Java Gibbons.

No	Primate Species	Σ Sample	Examination Results	Σ Positive Sample	Prevalence (%)
1	West Java Langur	19	<i>Trichuris trichiura</i>	4	21,1
			<i>Pedicinus ancoratus</i>	1	5,3
2	East Java Langur	30	<i>Trichuris trichiura</i>	1	3,3
			<i>Pedicinus ancoratus</i>	1	3,3
3	Java Gibbon	19	<i>Trichuris trichiura</i>	5	26,3
			<i>Pedicinus ancoratus</i>	0	0

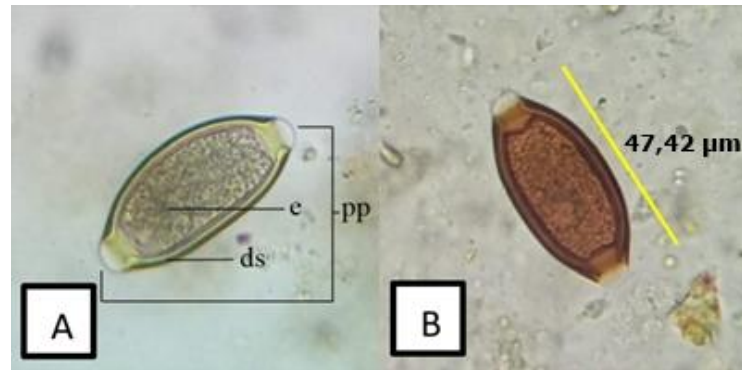


Figure 1. *Trichuris trichiura* egg based on fecal examinations (A) floatation method and (B) native method, measurement using application NIS-Elements BR 4.10.00 and the length of egg was recorded at 47.42 µm. Description: pp = polar plug, e = embryo, ds = cell wall. 640x magnification.

The results of fecal examination showed that there was infection with eggs of Nematode class, namely *Trichuris* sp., with egg morphology oval in shape, lined with cell walls, brownish-colored embryos, and equipped with symmetrical polar plug formations at both ends. In accordance with previous report by Foreyt (2001). The measurement results showed that *Trichuris* egg length was 45.44 µm, in accordance with the key to morphological identification according to Ash and Orihel (2007) which stated that *Trichuris trichiura* eggs have an egg size of about 50 µm while *Trichuris vulpis* has a much longer egg length, which is about 72-90 µm. Taylor *et al.* (2016) also stated that species from the genus *Trichuris* (whip worms) that can infect humans and NHP (Non-human primates) are *Trichuris trichiura* species. Rivero *et al.* (2020) stated that many species of *Trichuris* can infect humans, but only *Trichuris trichiura* which for many years has been considered a whipworm that is specific to primates.

In this study, only eggs of the *Trichuris trichiura* species were found as endoparasite. The results of this study in accordance with the research conducted by Tiwari *et al.* (2017) on Nilgiri Langurs (*Trachypithecus johnii*) in India with the highest prevalence of gastrointestinal parasites, namely *Trichuris trichiura*, but there was a difference such as in this study no other types of gastrointestinal parasites were found, either eggs of other species of worms or protozoa, possibly because the animals were rehabilitated when the medical check-up was already given anthelmintics so that influence the possibility of finding endoparasites. Kurniawati *et al.* (2020) stated that differences in prevalence and type of infection may depend on the life

cycle of the parasite, geographical conditions, food sources, and feeding behavior of primates.

Based on the results in this study, one type of ectoparasite was found, based on the morphology, it was included in the lice group. The results of microscopic examination showed that the ectoparasite samples had a flat-dorsoventral body shape, the outer wall of the body was lined with chitin, had a head that had two antennae and three pairs of legs equipped with hooks at the ends. The general body parts consisting of the head, thorax and abdomen can be seen in Figure 2.

The lice found in this study have a pair of antennae, each antenna has five segments. The thorax has three pairs of locomotion in the form of legs with the tibio-tarsus. The anterior paws have fairly slender claws, while the middle and posterior paws have slightly fatter claws. The abdomen has paratergal plates located in the fourth to sixth segments, the genital plate is located in the posterior part of the abdomen. Based on the results of observations and morphological identification keys according to Mey (2010) and Durden *et al.* (2020), and based on the host it can be identified that the lice species obtained is *Pedicinus ancoratus*.

The result of measuring the total body length of *Pedicinus ancoratus* in this study was 1.030 mm. The head length is 0.300 mm and the head width is 0.150 mm. The length of the thorax is 0.190 mm and the width of the thorax is 0.230 mm. Abdominal length 0.540 and abdominal width 0.480 mm, the results of these measurements have differences with research conducted by Durden *et al.* (2020) the total body length reaches 1.675 mm, the head width is 0.255 mm and the thorax width is 0.355 mm. This difference may be due to the different species of *Pedicinus* being measured.

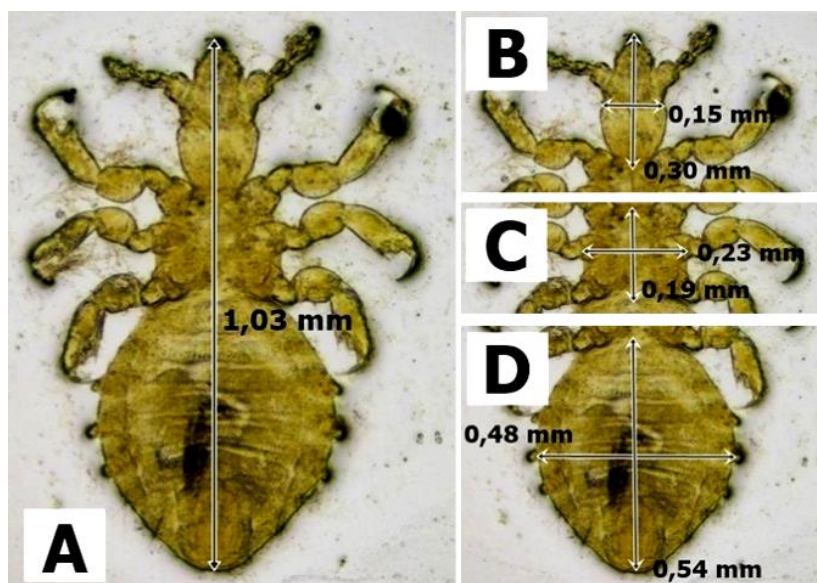


Figure 2. Morphology of *Pedicinus ancoratus*. (A) general morphology with body length 1.03 mm, consist of (B) = Head, with 0.30 mm in length x 0.15 mm in width, (C) = Thorax, with 0.23 mm length x 0.19 mm width and (D) = Abdomen, with 0.54 mm length x 0.48 mm width. Magnification of 10x using fluorescence microscope Nikon Eclipse Ci and measurement using NIS-Elements BR 4.10.00.

Based on this study, in addition to the adult stage, eggs were also found attached to the body hair of the Javan Langur in the thigh and stomach area. The egg has an operculum, is blackish white and is attached to the hair, this is in accordance with what was said by Taylor *et al.* (2016). *Pedicinus ancoratus* eggs can be seen in Figure 3.

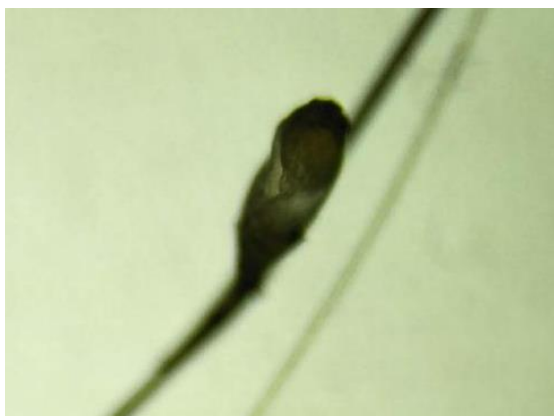

Figure 3. Egg of *Pedicinus ancoratus*. 40x magnification using a light microscope.

Schol *et al.* (2012) stated that ticks mostly move between their hosts through direct host-to-host contact and are usually host-specific (can only be transmitted to one host species). *Pedicinus ancoratus* has only ever been found to infest langur and has never been found in Java gibbons. Based on research conducted by Durden and Musser (1994) and Mey (2010) stated

that the infestation of *Pedicinus ancoratus* was found in Java langur (*Trachypithecus auratus* and *Trachypithecus mauritius*), gray langur (*Trachypithecus cristatus*), Francois langur (*Trachypithecus francoisi*) and red langur (*Presbytis rubicunda*).

Conclusion

The ectoparasites that infest the East Javan langur (*Trachypithecus auratus*) and West Java langur (*Trachypithecus mauritius*) were *Pedicinus ancoratus*, with a prevalence of 3.3% in East Java langur and 5.3% in West Java langur, while in the Java gibbon (*Hylobates moloch*) no ectoparasite infestation was found. Moreover, gastrointestinal endoparasites that found in the East Java langur (*Trachypithecus auratus*), West Java langur (*Trachypithecus mauritius*) and Java gibbon (*Hylobates moloch*) were *Trichuris trichiura* with a prevalence of 3.3% in East Java langur, 21.1% in the West Java langur, and 26.3% in the Java gibbon respectively.

Acknowledgement

Thanks to the Aspinall Foundation Indonesia Program as the manager of primate rehabilitation centers in East Java, namely the Java Langur Center and Java Primate Rehabilitation Center in West Java and also all individuals who have helped during the investigation of present study.

References

- Ash, R. L. and T. C. Orihel. 2007. Atlas of Human Parasitology. Chicago: American Society for Clinical Pathology. Hal. 50, 58, 84, 97 - 186.
- Astriani, W. I., H. Arief dan L. B. Prasetyo. 2015. Populasi dan Habitat Lutung Jawa (*Trachypitecus auratus* E. Geoffrey 1812) di Resort Balanan, Taman Nasional Baluran. J. Media Kons 20(3): 226-234
- Brandon-Jones D. 1995. A revision of the Asian pied leaf-monkeys (Mammalia: Cercopithecidae: superspecies *Semnopithecus auratus*), with a description of a new subspecies. Raffles Bulletin of Zoology. 43: 3-43.
- Bowman, D. D. 2014. Georgis' Parasitology for Veterinarians 10th Edition. St. Louis, Missouri: Elsevier Saunders. Hal. 52, 122 - 156
- Comanesi, Y. D., Erianto dan S. Rifanjani. 2017. Keanekaragaman Jenis Primata Diurnal di dalam Areal IUPHHK-HT PT. Bina Silva Nusa Kecamatan Batu Ampar Kabupaten Kubu Raya Provinsi Kalimantan Barat. J. Hutan Lestari. 5(2): 563-570.
- Durden, L.A., S. E. Kessler, L. Boundenga, B. Ngoubangoye, T. A. Tsoumbou, C. I. Mousadji-Kinga, M. Halbwax, J. M. Setchell, J. Nicholas and S. E. Greiman. 2020. A New Species of Sucking Louse from the Madrill from Gabon with a Review of Host Associations and Geographical Distributions and Identification Keys to Members of the Genus *Pedicinus* (Phthiraptera: Anoplura: Pedicinidae). Journal of Parasitology. 106(2) : 221-232.
- Durden, L.A and G. G. Musser. 1994. The Sucking Lice (Insecta, Anoplura) of the World: a Taxonomic Checklist with Records of Mammalian Hosts and Geographic Distributions. Bulletin of the American Museum of Natural History. 218: 1-90.
- Fauzi, F., R. Rahmawati dan P. Sandan. 2017. Estimation of Population Density and Food Sort of Kelasi (*Presbytis rubicunda* Muller 1838) in Nyaru Menteng Arboretum of Palangka Raya. J. Daun. 4(1):7-16.
- Foreyt, W.J. 2001. Veterinary Parasitology Reference Manual, 5th ed. Ames Iowa (US): Iowa State University Press. 181-197.
- Hanafiah, M., H. D. Alfiansyah dan A. Sayuti. 2018. Identifikasi Parasit pada Biawak Air (*Varanus salvator*). Jurnal Sains Veteriner. 36(1): 24-31.
- Huffman, M. A., C. A. D. Nahallage, H. Hasegawa, S. Ekanayake, L. D. G. G. De Silva and I. R. K. Athauda. 2013. Preliminary Survey of the Distribution of Four Potentially Zoonotic Parasite Species Among Parasites in Sri Lanka. Journal National Science Foundation Sri Lanka. 41(4): 319-326.
- Joesoef, J. A., D. Sajuthi, A. Wijaya, M. U. E. Sanam. 2018. Keragaman Endoparasit pada *Macaca fascicularis* dan Potensi Zoonotiknya dengan Cuaca Berbeda di Kota Kupang. Jurnal Veteriner. 19(4): 451-459.
- Klein, A., E. Zimmermann, U. Radespiel. G. Schaarschmidt. A. Springer and C. Strube. 2018. Ectoparasite communities of small-bodied Malagasy primates: seasonal and socioecological influences on tick, mite and lice infestation of *Microcebus murinus* and *M. ravelobensis* in northwestern. Journal Parasites and Vectors. 11(459): 1-18.
- Kurniawati, D.A., L. T. Suwanti, N. D. R. Lastuti, S. Koesdarto, E. Suprihati, M. Mufasirin dan A. Pratiwi. 2020. Zoonotic potential of gastrointestinal parasite in long-tailed Macaque *Macaca fascicularis* at Baluran National Park, Situbondo, East Java, Indonesia. Aceh Journal of Animal Science. 5(1): 47-56.
- Mey, Eberhard. 2010. The *Pedicinus* Species (Insecta, Phthiraptera, Anoplura, Pedicinidae) on Douc Langurs (*Pygathrix* spp.). Vietnamese Journal of Primatology. 4(1): 57-68.
- Rivero, J., A. M. Garcia-Sanchez, A. Zurita, C. Cutillas and R. Callejon. 2020. *Trichuris trichiura* isolated from *Macaca sylvanus*: morphological, biometrical, and molecular study. BMC Veterinary Research. 16(445): 1-4
- Scholl, K., M. A. Julie, H. L. Fabian, A. C. Colin and L. R. David. 2012. Variable Microsatellite Loci for Population Genetic Analysis of Old World Monkey Lice (*Pedicinus* sp.). Journal Parasitology. 98(5): 930-937.

- Taylor, M. A., R. L. Coop *and* R. L. Wall. 2016. *Veterinary Parasitology*. 4th Edition. Blackwell Publishing. UK. 853-886.
- Tiwari, S., D. M. Reddy, M. Pradheeps., G. S. Sreenivasamurthy *and* G. Umapathy. 2017. Prevalence and co-occurrence of gastrointestinal parasites in Nilgiri Langur (*Trachypithecus johnii*) of fragmented landscape in Anamalai Hills, Western Ghats, India. *Current Science*. 113(10): 2194-2200.
- Wedana, M., I. Kurniawan, Z. Arsan, N. B. Wawandono, A. Courage *and* T. King. 2013. Reinforcing the Isolated Javan Langur Population in the Coban Talun Protected Forest, East Java, Indonesia. *Wild Conservation*. 1(5): 31-39.