

Coen's ascending ramus fixator use for repositioning the ascending ramus during mandible reconstruction

Coen Pramono D

Department of Oral and Maxillofacial Surgery
Faculty of Dentistry, Airlangga University/Dr. Soetomo Public Hospital
Surabaya - Indonesia

ABSTRACT

The aim of mandible reconstruction using reconstruction plate after resection is to restore aesthetic and function for muscles attachment and allow mandible movement during normal function and free from joint problem. Temporomandibular joint (TMJ) is an area of concern during mandible reconstruction using reconstruction plate as misalignment on placing of the reconstruction plate may cause the joint place in distortion to the glenoid fossa. Loss large part of mandible bone structure may lead problems during mandible reconstruction procedure because the surgeon may lose in orientation during forming the reconstruction plate into a horseshoe-shaped form of the mandible as well as during plate placement. The plate can only be well adapted when the position of two distal ends of the resected mandible bone are in a stable position. Simple ascending ramus fixator (CARF) to fix the ascending ramus in its stable original position to allow easy mandible reconstruction was created. Those CARF were designed in two types which have one and two fixator stems used to stabilize one or both sites of the ascending rami and showed its effectiveness.

Key words: mandible reconstruction, ascending ramus, ascending ramus fixator, ascending ramus reposition, mandible joint angle, mandible joint prosthesis

Correspondence: Coen Pramono D, c/o: Departemen Bedah Mulut dan Maksilofasial, Fakultas Kedokteran Gigi Universitas Airlangga, Jln. Mayjend. Prof. Dr. Moestopo 47 Surabaya 60132, Indonesia. E-mail: coen_pram@yahoo.com

INTRODUCTION

The mandible bone is movable and has no bony articulation with the skull. It is the heaviest and strongest bone of the head and serves as a framework for the floor of the mouth. The mandible constructed as horizontal portion or descending ramus and two vertical portions or ascending rami which join at an obtuse angle. The articular portion of the mandible is connected with the ascending ramus at the inferior portion of the joint i.e. the neck of condyle and the superior portion or articular portion fitting into the mandibular fossa of the temporal bone articulating surface. Mandible has horseshoe-shaped form and serves the airway passage by maintaining the position of the tongue, suprahyoid muscles permitting the mastication, articulation, deglutition, and respiration, supports the teeth at the lower dental arch. It also plays an important role in defining the contour of the lower third of the face. Interruption of the mandible continuity therefore produces both functional impairment and cosmetic deformity. The result of functional disturbances after the lost part of the mandible bone due to resection may even be worst when the condyle is involved. Loss of mandibular continuity results in deviation of the mandible toward the resection site due to the unopposed pull of the remaining muscles of mastication and soft tissue contracture and scar formation. In mandible resection involving both lateral and central part of mandible (LCL = Lateral Central Lateral), the mandible may lose

its function for maintaining the position of the tongue and the suprahyoid muscles. All of the suprahyoid soft tissues will be immediately collapse posteriorly and may cause an airway obstruction after resection in this region is the possible complication should be avoided. Therefore mandible reconstruction after resection is necessary to be performed as it is important to restore the mandible contour and necessary for muscles re-attachment.

Mandible reconstruction using plates can be difficult in cases of: diminished dental occlusion; block resection which left only the ascending ramus as a free bone at the distal end; resection of the mandible involving the lateral and central part of the mandible bone or in fashion of LCL and no occlusion is available; and in edentulous jaws.

Temporomandibular joint (TMJ) is an area of concern in mandible reconstruction using reconstruction plate. A common concern is placement of the plate may torque the position of the ascending rami and the condyle relative to the glenoid fossa. Alteration of the condyle position may induce a TMJ morphology change and may adversely contribute possible problems. The risk of developing TMJ internal derangement or inducing a progression of internal derangement after mandible resection caused by the loss of ascending ramus position should always be taken as one of important considerations. In case of large resection of the mandible part which the surgery will be only left the ascending ramus section, recording of the original position of the ascending rami before resection is presumed to be

very important step. This step can be achieved by placement of fixation device of Coen's Ascending Ramus Fixator (CARF).

The CARF was designed very simple using the principle of intermaxillary splint made by acrylic and a fixator made from stainless steel used for holding the ascending ramus attached on it using screws. The position of the fixator is made according to the position of the rest healthy ascending ramus available after resection.

The present paper describes cases of mandible reconstruction after resection. Two cases of patients suffered from Ameloblastoma in the lower jaw which had grown into large dimension and had been treated with mandible resection and followed with primary reconstruction using Coen's reconstruction plates.

The large tumor dimension in these cases presented involved important structures i.e. descending ramus which necessary to maintain the anatomical position of the ascending rami, which were seen collapse immediately after resection of the descending ramus. This situation may lead difficulty for reconstruction procedure using reconstruction plate. Procedure of mandible reconstruction would be difficult when the position of the ascending ramus is in unstable position. The free or movable ascending ramus is related directly with the condyle position and this situation may lead five possible perspective condyle positions: anterior, posterior, lateral, medial and caudal, therefore recording the position of the ascending ramus in its original position become necessary to prevent the ascending ramus losing its position.

Misplacement of the ascending ramus can be related to alteration of TMJ morphology and therefore may contribute adversely possible problem in mandible kinetic movement.

CASE

Case 1: A-34 year old man asked for treatment due to mandible swelling which has been marked since five years ago and reported gradually increased in its diameter and changing his facial appearance. Panoramic radiograph shows a multicystic radiolucent lesion in the region of 37 to 47 (Figure 1-A). Histopathologic finding was reported as an Ameloblastoma with plexiform type. The treatment was planned with mandible resection from the region of 38 to 48 followed by immediate reconstruction using plate reconstruction. Difficulty during reconstruction procedure was predicted before surgery as the ascending rami will become free movable bones because no dental occlusion is available after mandible resection. Mandible reconstruction procedure was planned including the preparation of CARF. The CARF which has two fixator stems and was designed using a set of gypsum model and mandible simulation model made from transparent plastic

sheet taken by tracing from the Panoramic radiograph. The mandible model then attached in front of the gypsum model following the mandibular arch and the position of teeth as the guidance (Figure 1-C). A multi holes stainless plates were used for fixator stems and fixed into the acrylic splint had been prepared using two stainless screws in each site. The positions of those two stems were adjusted according to the position of predicted available healthy ascending rami and can be found easily when simulation model is made (Figure 1-C, D & E). The CARF was seen working properly to fix both ascending rami (Figure 1-F) facilitated an easy forming and placement of the reconstruction plate (Figure 1-E). The reconstruction plate was adapted forming the mandibular arch and fixed with five screws in each site (Figure 1-B & 1-G) and followed by releasing the CARF.

Case 2: A-16 year old boy visited our Oral and Maxillofacial Surgery Department due to enlarged mandible swelling since past few years. Panoramic radiograph shows a large unicystic lesion in the region of 38 to 43 (Figure 2-A). Histopathology examination confirmed with Ameloblastoma with Plexiform type. Resection of the mandible was planned from the region of 44 to 38. Resection a huge part of the mandible bone was done and planned with primary reconstruction using reconstruction plate (Figure 2-B). CARF with unilateral fixator stem was prepared nearly with same procedure as shown in case 1 and planned to be used only for fixing the left ascending ramus. Reposition of the right site of the ascending ramus can be

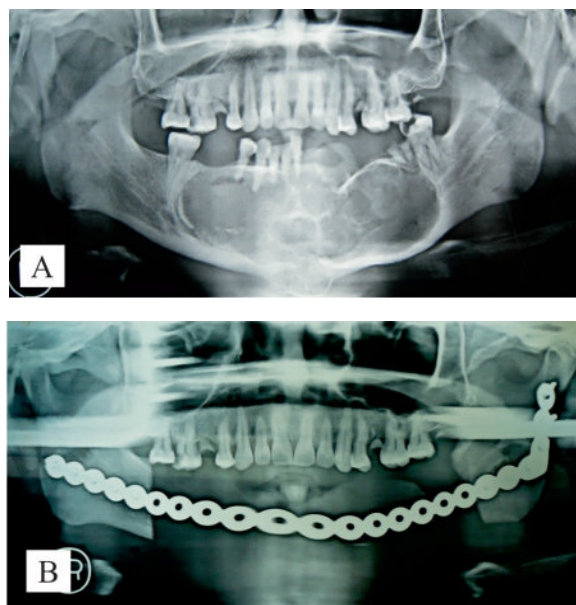


Figure 1. Panoramic radiograph of: A) A large dimension of Ameloblastoma in the mandible in LCL fashion: loss of the ascending rami position due to surgical resection was predicted. B) Postoperative Panoramic view: plate reconstruction fixed into proper available space between the mandible rami.

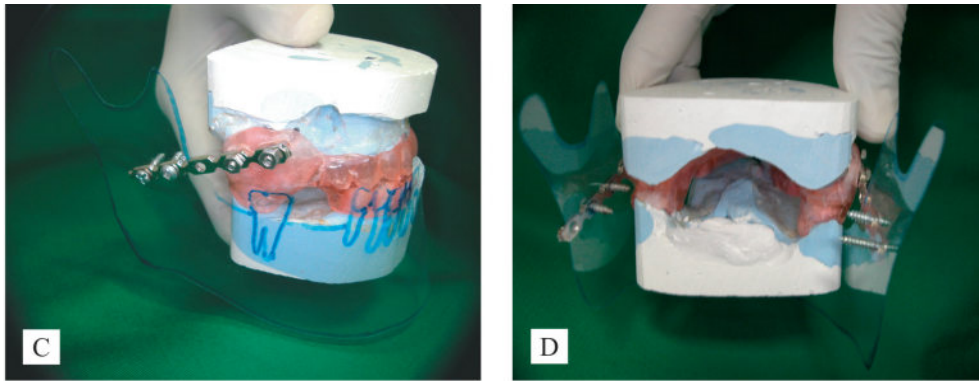


Figure 1. C) Mandible simulation model made from transparent plastic sheet taken by tracing from Panoramic radiograph used for adjusting the position of the fixator stems. D) The CARF with bilateral stems shows from posterior view.

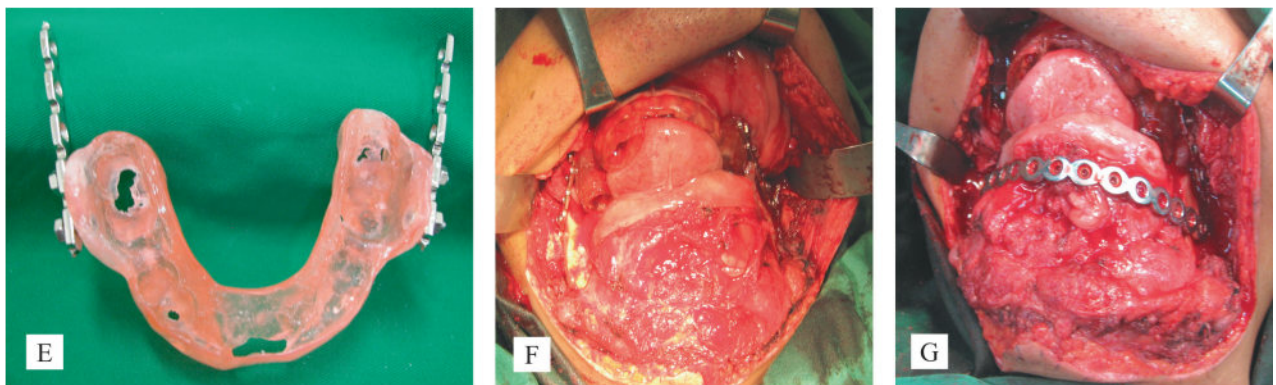


Figure 1. E) The CARF made from acrylic with intermaxillary splint principle: two stems attached using stainless steel screws. F) The CARF with bilateral stems fixed the ascending rami properly in LCL case: facilitate an easy placement of reconstruction plate. G) Reconstruction plate placed in anatomical space between two mandible rami stabilized using CARF with two stems type.

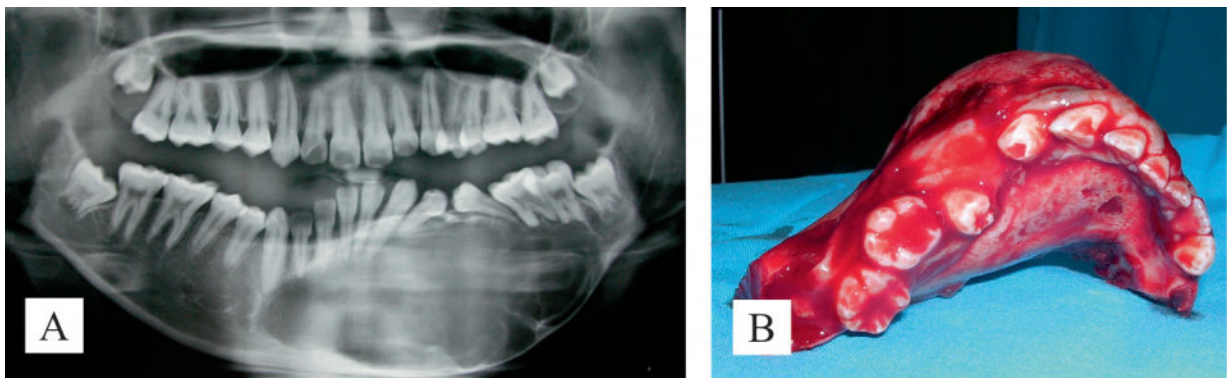


Figure 2. A) Panoramic x-ray: Ameloblastoma of the mandible in LCL fashion. The occlusion of the left mandible in the region of molar left intact. B) Resection a huge part of mandible bone: immediate reconstruction is obligatory to be proceeded.

achieved to be guided by the right side dental occlusion. Placement of CRF with unilateral stem type fixed to the left ascending ramus and the intact dental occlusion on the right side gives an adequate and stable space between two ascending rami facilitated an easy reconstruction plate adaptation and placement (Figure 2-C).

CASE MANAGEMENT

Two cases of Ameloblastoma in the mandible were treated in our Oral and Maxillofacial Surgery Department, Faculty of Dentistry, Airlangga University.

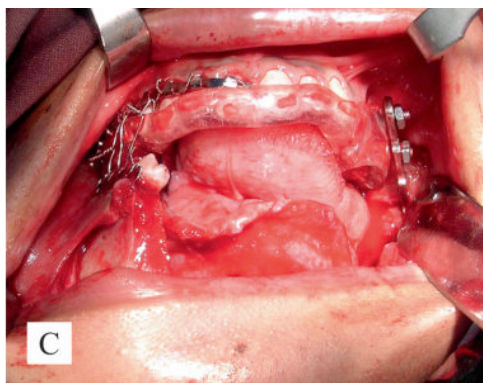


Figure 2. C) The Placement of CRF with unilateral stem type fixed to the left ascending ramus and the intact dental occlusion on the right side gives an adequate and stable space between two ascending rami.

Mandible resections followed by primary reconstruction using reconstruction plate were done in both cases. The reconstruction procedures were predicted to be difficult in both cases as the tumors had grown into large dimension and the surgical intervention may cause the ascending rami lose its connection with the horizontal portion or the descending ramus. The two vertical portions or ascending rami which actually should be joined at an obtuse angle become free portions and lose its anatomical positions after resection. Two type of ramus fixators (CARF) were used temporarily for maintaining the ascending rami positions after mandible resection and were applied in both cases respectively to allow an easy procedure during reconstruction plate forming, adaptation and placement.

DISCUSSION

The effect of mandible reconstruction on the temporomandibular joint (TMJ) is an area of concern as well as the plate position and its acceptable horseshoe-shaped form. The common concern is that the plate placement may torque the condyle position relative to the glenoid fossa. Alteration of TMJ morphology may adversely contribute possible problem in mandible kinetic movement.

Bilateral Sagittal Split osteotomy (BSSO) is the best example of surgical intervention which may contribute an alteration of TMJ morphology leading to TMJ disorders. The change of the ascending rami position after sagittally split from the descending ramus followed by setback or advancement of the descending ramus and reposition of the ascending rami including the condyle segments may introduce altered condyle segments position. Loss of a large segment of the mandible bone in the central segment due to resection may lead the same problem can be shown in BSSO procedure while the distal mandible bone segment become left unfixed and therefore it may lose its original position.

Alder *et al.*¹ analyzed short-term in condylar position changes after BSSO on 21 treated patients which had been repositioned and fixated rigidly. Pre and postoperative condyles positions were observed using a Computed Tomography as their tool for investigation. The angular angle of the condyle position after BSSO are found changing in all individuals had been investigated. They found an increased and decreased in condylar angle angulation. The majority of cases reported an increased angle, which would lead anterior movement of the medial and posterior movement of the lateral pose. Detailed data given that all condyles observed had some displacement and that movement occurred in all directions which presented as average displacements in the positive and negative direction. In the sagittal dimension, the majority of condyles moved posteriorly (67%), superiorly (60%) and demonstrated an inferior or distal distal rotation of the proximal segment (61%). The remainder were displaced anteriorly to the same average of distance, inferiorly to an average of 1.2 mm and rotated superiorly to an average of 3.2 degrees.

Rotskoff *et al.*² compared cases of BSSO and fixed with rigid internal fixation (RIF) and treated with and without a condyle proximal segment-positioning device (CPD) used at the time of surgery. A total of 20 patients were treated and analyzed with axially corrected sagittal tomography. Tracing of the TMJs taken preoperatively and one day postoperatively, were superimposed using the squamotympanic fissure, glenoid fossa, articular eminence, and posterior aspect of the condyle and ramus as constant anatomic landmark. They reported that the average condyles were displaced posteriorly, inferiorly with forward rotation of the condyle. Displaced was less pronounced in the group the CPD were used.

Stoster *et al.*³ used submentovertex radiograph to assess changes in the transverse dimension. They included fifty three samples who had undergone for BSSO and they found condyle rotation, this involved rotation of the medial aspect posteriorly and the lateral aspect anteriorly due to the segments fixation.

Schultes *et al.*⁴ also analyzed changes in angulation after ramus surgery using the technique of BSSO. Their study used 3D models of the mandible constructed from 3D CT data. The result taken from sample of 31 patients underwent ramus surgery for mandibular advancement. The result showed that the intercondylar angle was decreased by 2.5 degrees on average, which would require rotation of the medial pole posteriorly and the lateral pole anteriorly. Intercondylar distance was increased by about 2 mm.

Although the CARF can be used for maintaining the position of ascending rami in case of loss of large part of the descending ramus, the relative risk of developing TMJ internal derangement after mandible reconstruction using plate is important issue in treatment planning and in obtaining informed consent.

The philosophy of successful surgical result in mandible surgery involving the TMJs with prediction of altered joints is free from the joints problem postoperatively. Those two type of CARFs presented in these reported cases were proved to be useful in maintaining an adequate anatomical space or distance between two distal mandible bone ends or between two free ascending rami and can be made in low cost and easy to prepare preoperatively. This procedure can be used as an alternative surgical procedure as it had been proven that the stability of the ascending rami can be achieved properly and also helpful to facilitate an easy procedure during reconstruction plate forming and placement, and should be taken as consideration in a routine surgical protocol for eliminating postoperative TMJ problems.

REFERENCES

1. Alder ME, Deahl ST, Matteson SR, Van Sickles JE, Tinner BD, Rugh JD. Short-term changes of condylar position after sagittal split osteotomy for mandibular advancement. *J Oral Surg Oral Med Oral Pathol Oral Radiol Endod* 1999; 37:41–45.
2. Rotskoff KS, Herbosa EG, Villa P. Maintenance of condyle-proximal segment position in orthognathic surgery. *J Oral Maxillofac Surg* 1991; 49:2–7.
3. Stoster TG, Pangrazio-Kulbersh V. Assessment of condylar position following bilateral sagittal split ramus osteotomy with wire fixation or rigid fixation. *Int J Adult Orthod Orthognath Surg* 1994; 9:55–63.
4. Schultes G, Gaggl A, Karcher H. Changes in the dimension of milled mandibular models after sagittal split osteotomies. *Br J Oral and Maxillofac Surg* 1998; 36:196–201.