

# Mandible vertical height correction using lingual bone-split pedicle onlay graft technique

**Coen Pramono D**

Department of Oral and Maxillofacial Surgery  
Faculty of Dentistry Airlangga University  
Surabaya - Indonesia

## ABSTRACT

*As edentulous mandible become atrophic, a denture bearing area will also be reduced. Difficulty in the removable prosthesis rehabilitation will be present as well. The purpose of this paper reports an innovative surgical technique to cope a problem of unstable complete lower denture due to bone atrophy and resulted of vertical height reduction of the anterior region of the mandible necessary for denture retention. Vertical advancement of the lower jaw using lingual bone split pedicle onlay graft technique in the anterior region of the mandible and followed by secondary epithelization vestibuloplasty in achieving the vertical height dimension. The surgery was achieved satisfactorily as the vertical dimension of the mandible anterior region had increased and the denture seated more stable comparing with the previous denture worn by the patient. It concluded that the surgery was achieved with a great result as the vertical height of the anterior region of the mandible had increased positively therefore lead the denture seated more stable.*

**Key words:** mandible atrophy, alveolar vertical height correction, lingual bone split, pedicle lingual bone, bone onlay graft, vestibuloplasty

*Correspondence:* Coen Pramono D, c/o: Bagian Ilmu Bedah Mulut dan Maksilofasial, Fakultas Kedokteran Gigi Universitas Airlangga. Jln. Mayjend. Prof. Dr. Moestopo No. 47 Surabaya 60132, Indonesia.

## INTRODUCTION

The height of the alveolar process in edentulous patients gives an important contribution in prosthetic dentistry. Although the present of dental implant give a significant contribution in dental rehabilitation, correction of the vertical height in atrophis jaw to achieve a retentive removable dental prosthesis by surgery are sometimes needed to be performed in many settings.

Pre-prosthetic surgery were improved since the end of World War II, through the developments of better materials, the improved accuracy of diagnostic technique and better understanding of oral physiology, dental prosthetics has made great strides in increasing the successful use of prosthetic appliances in edentulous patients. Nonetheless, there remain a number of patients who can never be made to use denture effectively because the process of bone atrophy, soft tissue hypertrophy, or both have developed beyond the point of prosthetic accommodation. In these patients, surgery offers a significant contribution.

In case of atrophy of the alveolar process in the posterior region found with sufficient depth of the lingual sulcus and sufficient high of the vertical height of the anterior alveolar process, stable denture retention can be expected. A difficult situation would be occur when the lost of the denture bearing suffered in the anterior region of the mandible, this situation might contribute a difficulty in achieving complete denture prosthesis stabilization.

Surgical technique in oral vestibular sulcus extension in an atrophied alveolar process has a long evolutionary history of success and gives the credit for pioneering the clinical practice of pre-prosthetic surgery. Some articles have documented the clinical versatility and outcome of sulcus extension surgery<sup>1-20</sup> and those techniques till now days still uses as a basic surgical knowledge for any sulcus extension surgery. Review study from Hillerupp *et al.*<sup>20</sup> concluded that lowering of the floor of the mouth provide a substantial benefit to patients with denture problem due to alveolar ridge atrophy.

Several pre-prosthetic surgical procedures that have been used successfully are little known or applied in ours. Among these are sub-mucosal vesitybuloplasty, secondary epithelization vestibuloplasty, alveolar ridge-skin grafting vestibuloplasty, buccal sulcus-skin grafting vestibuloplasty, tubero-plasty, and upper jaw sandwich osteotomy with immediate vestibuloplasty. All of those techniques are applicable in both maxilla and mandible correction and conjunction with the oral soft manipulations.

Although some recent surgical techniques and appliances of denture rehabilitation have been developed, such as the used of dental implant and distraction osteogenesis,<sup>21-27</sup> the previous techniques of ridge correction for dental bearing enlargement which had been developed still gave a great benefit in many settings, especially in patients who can not afford of those advanced appliances.

The surgical technique for denture bearing extension basically can be done by two way basic methods, soft tissues extension, and secondly is combination of soft tissue- bone surgery. The soft tissue surgery sometimes can be done in simple way in comparing to soft tissue-bone surgery. Surgical combination of bone-soft tissue surgery usually done in two stages of surgeries, as bone advancement for the first step and followed by vestibuloplasty to built a new sulcus.

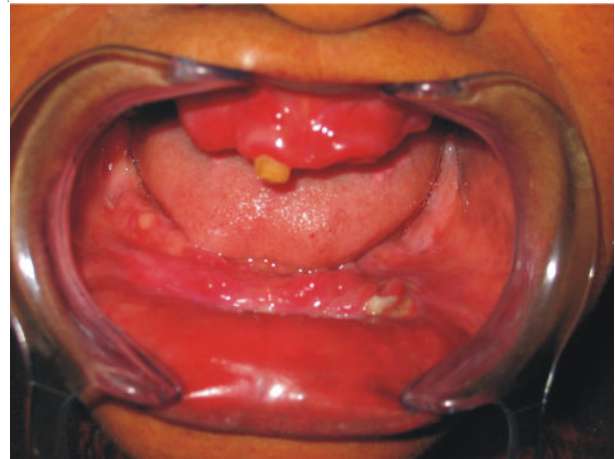The lack of bone mass associated with relatively high muscle attachments and insufficient vestibular depth complicates the prosthetic restoration of the atrophic mandible. Bell *et al.*<sup>28</sup> in his experimental studies of interpositional bone grafts to the maxilla and mandible indicate that the palatal and labio-buccal mucoperiosteum in the maxilla and lingual mucoperiosteum in the mandible provide an adequate vascular pedicle for single stage repositioning of atrophic edentulous maxilla by Le Fort I osteotomy or superior repositioning of mandibular basal bone.

Various surgical reports of ridge augmentation in the mandible by Davis *et al.*,<sup>8</sup> Sander and Cox<sup>9</sup> Ewers and Haerle,<sup>12</sup> Tideman *et al.*,<sup>15</sup> Schettler,<sup>18</sup> had shown its superiority in achieving an augmented ridge and denture stability. The complexity of the surgical methods as had been presented by some authors, therefore applying another simple modification of surgical technique in improving the vertical height of the anterior part of atrophic mandible was thought to be useful.

#### CASE

A 65 year old female was visited Department of Oral and Maxillofacial Surgery, Airlangga University referred by Department of Prosthodontic with mandible atrophic especially in the anterior region. The patient appeared in our clinic was wearing her upper and lower complete dentures, but she was complaining of unstable lower jaw denture, therefore she expected for a new dental prosthesis. The Prosthodontist also reported the difficulty to arrange a stable denture due to the insufficient vertical height of the mandible anterior region. The patient was observed and planned with new full denture replacement both upper and lower jaws. The denture bearing in the upper jaw was found with sufficient ridge height, differed from what given in the lower jaw.

The lingual sulcus in posterior region and buccal sulcus were found in between acceptable depth for placing a removable denture, but she had lost the alveolar process, labial sulcus depth in the region of canine to canine. Flabby and movable soft tissue also presented, increasing the denture seated unstable. A labial depth correction was presumed to be necessary to perform by increasing the vertical height and sulcus depth. Panoramic radiography showed a mark atrophied of the anterior region therefore a vestibuloplasty alone would not be enough to ensure the



**Figure 1.** Preoperative situation: the anterior region of the lower jaw presented with flat ridge and narrowed labial sulcus.

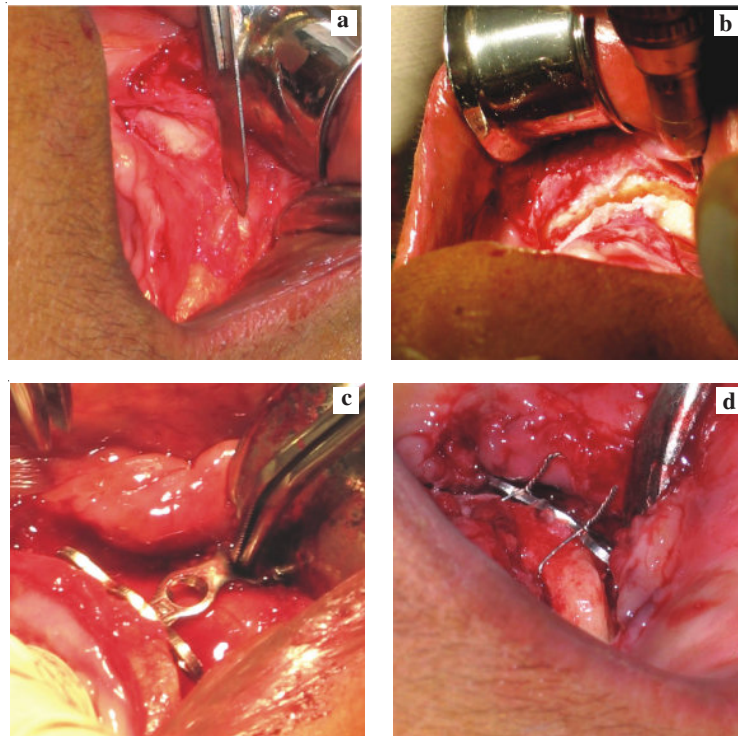
sulcus depth as the vertical bone height had been lost (Figure 1). Combination of bone augmentation and vestibuloplasty were planned in two stages.

A vertical bone osteotomy of the lingual part of the mandible was done and the bone fragment was onlayed above the mandible bone and fixed with T-miniplate in combination with wire osteosynthesis (Figure 2-a, b, c and d). Three months after the surgery, the T plate was removed and followed by immediate secondary epithelization vestibuloplasty in the region of canine to canine in the labial side (Figure 3-a). Two weeks after the vestibuloplasty, the vertical height of the anterior part of the mandible shown increased and the lower jaw impression was taken for a definitive complete denture prosthetic (Figure 3-b, c). The stability of the denture was reported by the prosthodontist with satisfactory (Figure 3-d).

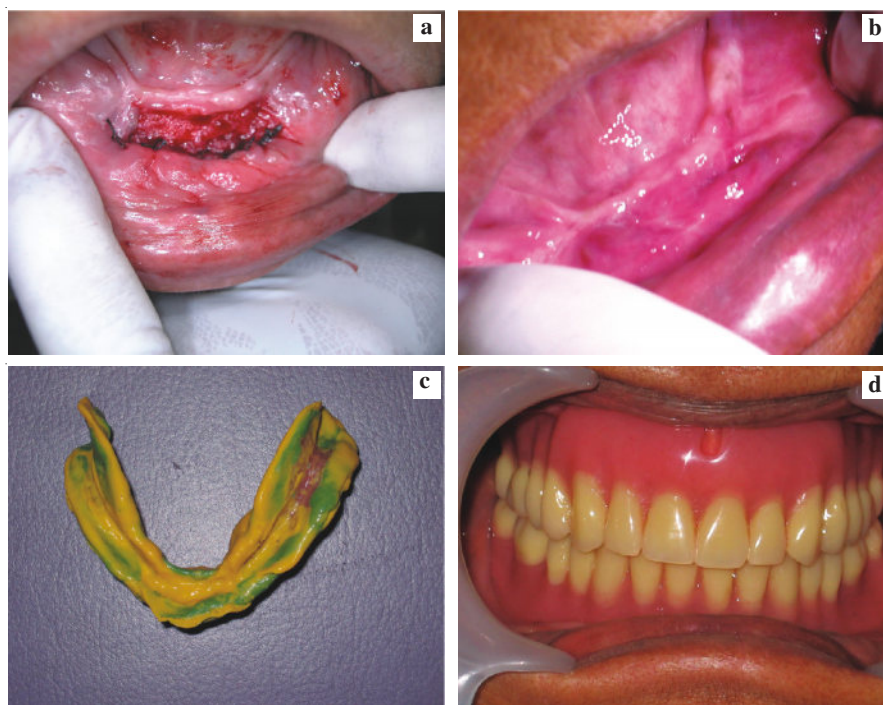
#### CASE MANAGEMENT

In atrophic edentulous mandible, advancement of the vertical height is necessary as the mouth had failed its denture bearing for placement of the denture. A new method of mouth rehabilitation using dental implant is now widely used, otherwise that method is still difficult to be proceeded in many setting as that technique of dental implant need of a highly cost, therefore correction of the alveolar process height using bone split technique can be use as an alternative method to cope problem of unstable denture due to alveolar atrophy.

The basic idea of this surgical technique is done by creating a new vertical height of the anterior region of the mandible. The lingual part of the mandible in the region from left to right first premolar was osteotomized vertically and followed by bone separation from the mandible with the lingual mucoperiosteum and muscles preserved on its attachment. The osteotomized bone is than extended



**Figure 2.** (a) Vertical and horizontal osteotomy the anterior part of the mandible in the lingual region from right first premolar to left first premolar; (b) The lingual bone separated from mandible; (c & d) The osteotomized lingual bone raised and placed above labial bone and fixed with bended T miniplate and stainless steel wires.



**Figure 3.** (a) Immediate secondary epithelization vestibuloplasty simultaneously done after the T plate removal; (b) Six months after surgery, anterior region of the mandible shows with vertical height and labial sulcus depth improvement, facilitated to a good denture retention; (c) The result of lower jaw impression shows a positive ridge improvement in the anterior region; (d) The lower jaw denture fitted nicely as well as the upper denture.

(Figures c and d published under the courtesy of Drg. Roestiny and Drg. Mefina from The Department of Prosthodontic, Faculty of Dentistry, Airlangga University).

superiorly and onlayed above the mandible bone as a pedicle bone graft to create a new alveolar process. T form miniplate osteosynthesis can be used as an alternate method for bone graft fixation. The plate can be removed 3 months after the first surgery and an immediate vestibuloplasty using secondary epithelization technique is done following the plate removal.

## DISCUSSION

Extensive changes may occur in the morphology of the jaw after tooth loss. The jaws are consisted of alveolar and basal bone. The alveolar bone and periodontal tissues supported the teeth, but neither have any physiological function once the teeth lost, and are therefore resorbed.<sup>29</sup>

Three disadvantage problems simultaneously existed in this case, as: a) lost of vertical height of the anterior region, b) a flabby tissue arose following the atrophied alveolar bone and c) unstable denture due to muscles activities.

The activity of the orbicularis oris and mentalis muscles interfered strongly in the anterior region of the mandible. Many of fibers that are contained entirely within orbicularis oris pass obliquely through the thickness of the lips from the dermis of the skin on outer labial surface to the mucous membrane on inner aspect. Contraction of the orbicularis oris compresses the lips against the teeth as well as closing the oral cavity. Another small slip of muscle, the mentalis, passes from front of the mandible near to midline to be inserted into the skin of the chin. It lies just to the side of the frenulum of the lower lip.<sup>30</sup> In patient with atrophied mandible who wearing a lower complete denture prosthesis, the activity of 2 muscles, the lower part of the orbicularis and mentalis muscles might be easily dislodge the denture. Ridge augmentation, sulcus extension, and muscle release are three major surgical objectives should be done to achieve denture stability.

Augmentation of the atrophic edentulous mandibular ridge has long been a problem for the oral and maxillofacial surgeon. Various types of transoral onlay bone grafting techniques in the mandible have been tried.<sup>8-9,12,15</sup> Davis *et al.*<sup>31</sup> have reported the use of autogenous transoral onlay rib grafting. In long term follow-up, these authors reported of excessive resorption of 30% to 50% of the bone had been grafted.<sup>8</sup> Ewers and Haerle in year 1980 reported an absolute elevation of the ridge in which the mandible had osteotomized vertically and displaced like a visor. The five-year results of 10 patients observed were reported. The Average of bone grafting resorption shown of 18 % of the elevation of the alveolar ridge in the first year, 10 % in second year, 8 % (i.e 0.6 mm), in the third year and 3% (i.e 0.2 mm) in the fourth and fifth years.<sup>12</sup>

The sources of bone had grafted as reported by Davis<sup>8</sup> and Ewers and Haerle<sup>12</sup> were different, which Davis used an autogenous rib as a bone sources and Ewers and Haerle used an autogenous bone which taken from the part of the

mandible and placed like a visor, therefore it might be the reason why the rate of bone resorption as reported by Davis<sup>31</sup> found higher than given by Ewers and Haerle.<sup>8</sup>

Mandible bone resorption in the anterior region in this case leads the difficulty in the complete denture prosthetic rehabilitation. An augmentation of the anterior region was proved to be possible using lingual bone split pedicle onlay graft technique. This surgical method was ensured based on two considerations, the bone used for this grafting procedure was an autogenous bone type as it was taken from the same mandible and applied by maintaining its vascularity through muscle attachment and lingual mucoperiosteum, means that the bone had been grafted to the recipient site in a pedicle form of bone graft. Application of this pedicle bone graft method expecting of minimum of bone resorption and would be adequately accepted by the recipient as it has a same type of intramembranous bone.

In short observation of eight months period after surgery concluded that this technique of alveolar process augmentation in the anterior region of lower jaw had augmented nicely, the anterior sulcus depth shown had been maintained and the lower jaw prosthesis stability is achieved successfully. This surgical technique lingual bone split pedicle onlay graft technique might be used as an alternative surgical technique for correction of atrophy in the anterior region of the mandible. Further observations are needed to determine the long-term results of this surgical technique.

## REFERENCES

- Schuchardt Von K. Die Epidermistransplantation bei der Mundvorhofplastik. Dtsch Zahnärztl Z 1952; 32:132–35.
- Trauner R. Die Alveoloplastik im Unterkiefer auf der lingualen Seite zur Lösung des Problems der unteren Prothese. Dtsch Zahnärztl Z 1952 March; 7(1):256–369.
- Obwegesser HL. Die Submuköse Vestibulumplastik. Dtsch Zahnärztl Z 1959; 14:629–35.
- Obwegesser HL. Die Totale Mundbodenplastik. Schweiz Mschw Zahnheilk 1963; 73(7): 565–72.
- Obwegesser HL. Surgical preparation of maxilla for prosthesis. J Oral Surg 1964; 22:127–34.
- MacIntosh RB, Obwegesser HL. Preprosthetic surgery: a scheme for its effective employment. J Oral Surg 1967; 25:397–413.
- Steinhauser EW. Vestibuloplasty-skin grafts. J Oral Surg 1971 November; 29:777–85.
- Davis WH, Delo RI, Waard WB, Terry B, Patakas B. Long term ridge augmentation with rib graft. J Max Fac Surg 1975; 3:103–6.
- Sanders B, Cox R. Inferior-border rib grafting for augmentation of the atrophic edentulous mandible. J Oral Surg 1976; 34:897-900.
- Obwegesser HL. Der atrophische Kiefer aus der Sicht des Kieferchirurgen. Schweiz Mschw Zahnheilk 1977; 87(9):946–58.
- Bell WH, Buckles RL. Correction of the alveolar ridge by interpositional bone grafting: a progress report. J Oral Surg 1978; 36:693–700.
- Ewers Von R, Haerle F. Langezeitresultate nach Visierosteotomi. Dtsch Zahnärztl Z 1980; 35: 1046–47.
- Haerle F. Indikation, Methoden und Ergebnisse zur absoluten Alveolarkammerhoehung des Unterkiefers. Dtsch Zahnärztl Z 1982; 37:121–26.
- Schwenzer Von N. Prinzipien und Standardverfahren zur operativen Verbesserung des Prothesenlagers. Dtsch Zahnärztl Z 1982; 37:127–31.

15. Tideman Von H, Stoelinga PJW, de Koomen de. Die Erhoehung des atrophierten Unterkiefers mit Beckenknochen transplantat. Erweitertes Autoreferat. Dtsch Zahnaerzl Z 1980; 35:1011–13.
16. de Koomen Von H, Stoelinga PJW, Tideman, Hendricks FHJ. Resultate bei der Erhoehung des atropischen Unterkiefers mit Beckenknochen transplantat. Dtsch Zahnaerzl Z 1980; 35:1014–16.
17. Tesch Von P, Jacobi-Hermanns E. Die Indikation zur relative Alveolarkammerhoehung des Unterkiefers. Dtsch. Zahnaerzl Z 1980; 35:1046–47.
18. Schettler Von D. Spaeterergebnisse der absoluten Kieferkammerhoehung im atropischen unterkiefer durch die "Sandwichplastik". Dtsch Zahnaerzl Z 1982; 37:32–135.
19. Schmelzle Von R, Schwenzer N. 10jaehrige klinische Erfahrung mit Cialit® konserviertem Stuetzgewebe in der praeprotischen Chirurgie. Dtsch Zahnaerzl Z 1982; 37:136–38.
20. Hillerupp S. Preprosthetic mandibular vestibuloplasty with split-skin graft. A 2-year follow-up study. Int J Oral Maxillofac Surg 1987; 16:270–78.
21. Lew D, HinkleR, Unhold G. Reconstruction of the severely atrophic edentulous mandible by means of atogenous bone grafts and simultaneous placement of osseointegrated implants. J Oral Maxillofac Surg 1991; 49: 228.
22. Jensen J, Sindet-Pendersen S, Oliver AJ. Varying Treatment Strategies for Reconstruction of Maxillary Atrophy with Implants: Result in 98 Patients. J Oral Maxillofac Surg 1994; 52:210–16.
23. Keller EE, Eckert SE, Tolman E. Maxillary antral and nasal one-stage inlay composite bone graft: Preliminary report on 30 recipient sites. J Oral Maxillofac Surg 1994; 52:438–47.
24. Betts NJ, Miloro M. Modification of sinus lift procedure for septa in the maxillary antrum. J Oral Maxillofac Surg 1994; 52:332–33.
25. Donovan MG, Dickerson NC, Hanson LJ, Gustafson RB. Maxillary and mandibular reconstruction using calvarial bone grafts and branemark implants: A preliminary report. J Oral Maxillofac Surg 1994; 52:558–94.
26. Sawaki Y, Ohkubu H, Hibi H, Ueda M. Mandibular lengthening by distraction osteogenesis using osseointegrated implants and an intraoral device: A preliminary report. J Oral Maxillofac Surg 1996; 54:594–600.
27. Carlson ER, Marx RE. Mandibular reconstruction using cancellous cellular bone graft. J Oral Maxillofac Surg 1996; 54:889–97.
28. Bell WH. Bone healing and vascularization after maxillary osteotomy. J Oral Surg 1975 April; 33–7.
29. Matthew IR, Frame JW. Surgical aids to prosthodontic, including osseointegrated implants. In: Pedlar J, Frame JW, editors. Oral and maxillofacial surgery: An objective-based textbook. 3<sup>rd</sup> ed. Churchill Livingstone: Printed in Spain; 2004. p. 143–62.
30. Johnson DR, Moore WJ. Anatomy for dental student. Hongkong: Oxford University Press; 1997. p. 144.
31. Davis WH. Transoral bone graft for atrophy of the mandible. J Oral Surg 1970 October; 28: 760.