

Epulis and pyogenic granuloma with occlusal interference

Widowati Witjaksono* and Ban Tawfeek Shareff Al Ani**

* Department of Periodontic, School of Dental Sciences University Science Malaysia and Faculty of Dentistry Airlangga University

** Department of Oral Pathology School of Dental Sciences, University Science Malaysia

ABSTRACT

In dental clinic of Hospital University Science Malaysia (HUSM), there were cases with Localized Gingival Enlargement (LGE) in the oral cavity with occlusal interference. In this study, three cases were observed. They were a 13 - year- old female with fibrous lge around 31 and 32 with occlusal interference in protrusive movement due to X bite, a 15 - year – old female with pyogenic granuloma near 11 & 21 with occlusal interference due to deep bite; and a 24 – year – old female who was eight months in pregnancy with pyogenic granuloma on the 34-35 and severe generalized pregnancy gingivitis with occlusal interference in centric occlusion and lateral movement. Clinical and histopathological diagnosis of the first case showed fibrous epulis, whereas the second and third cases disclosed pyogenic granuloma. Chronic trauma of the gingiva due to occlusal interference was assumed to be the cause of those LGE in case 1 and 2, while in case 3 poor oral hygiene and chronic trauma were assumed to be the etiologic factors.

Key words: localized gingival enlargement, fibrous epulis, pyogenic granuloma, occlusal interference

Correspondence: Widowati, Department of Periodontic, School of Dental Sciences University Science Malaysia, Health Campus 16150 K. Kerian, K. Bharu, Kelantan, Malaysia.

INTRODUCTION

The term epulis means tumor or a lump localized on the gum. The best describes as chronic inflammatory hyperplasias. The tumor can be fibrous epulis, pyogenic granuloma and giant-cell granuloma.¹

Fibrous epulis usually arises from an interdental papilla in a firm, pink nodule or varying shape. Fibrous epulis usually associate with a source of chronic irritation such as traumatic occlusion, calculus or the rough edge of a restoration.

Histopathologically the lesion consists of hyperplastic connective tissue, can be ulcerated and covered by stratified squamous epithelium.¹⁻³

Pyogenic granuloma usually arises from the interdental papilla. It appears as an elevated, pedunculated or sessile mass with a smooth or lobulated surface. It is deep red or reddish-purple in colour, and the surface maybe ulcerated. It also has tendency to bleed, either spontaneously or on provocation with slight trauma. It may develop rapidly to a variable size and then remain stable for an indefinite period.^{2,4} The lesion appears as a result from local irritation, but in some cases there may be a hormonal conditioning factors, such as in the lesions occurring in pregnancy and at puberty.¹⁻⁴

CASE

Some cases of Localized Gingival Enlargement (LGE) with occlusal disharmony often come to Dental Clinic Hospital University Science Malaysia (HUSM). Three

cases of LGE in the patients with occlusal interference will be discussed in this article

CASE 1 MANAGEMENT

A 13-year-old female was referred from a general practitioner to Klinik Pakar Perubatan (KPP) of Dental Clinic HUSM. Her main complaint was non-painful annoying of gingival swelling on the lower left anterior region. Gingiva was starting to lump since 6 months ago. Extra orally, no abnormality was detected.

Intra oral examination, there was a gingival swelling between teeth 31 and 32, pink and fibrous consistency (1a), its diameter was around 7 mm, with fair oral hygiene.⁵ Tooth 31, mesial pocket 3 mm, distal 8 mm, buccal 2 mm, and lingual 3 mm respectively, whereas tooth 32 mesial pocket 8 mm, distal 3 mm, buccal 4 mm, and lingual 5 mm with 1 degree of mobility. Occlusal relationship in the anterior region was mild cross bite or X bite.

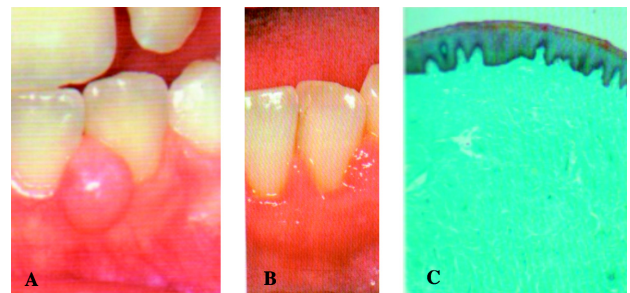


Figure 1. a) Before treatment; b) 4 weeks after treatment; c) Histological feature.

There was occlusal interference on 31 and 32 in the protrusive movement, no bone loss was detectable in the radiograph.

In the initial therapy, scaling and prophylaxis must be done, and the patient had to perform daily home plaque control. After oral hygiene was satisfying, then we proceeds to adjust the occlusal on particular teeth. Later, surgical excision was done from this LGE. Four weeks after the surgical intervention, intra oral examinations revealed that particular gingivae were inflammation free and exhibit a generally physiologic morphology. A very slight recurrence of gingival hyperplasia can be detected between 31 and 32 papillae (1b). Histopathologically the lesion consist of accumulation of fibrous connective tissue (1c). The diagnosis based on clinical examination and histopathological view is fibrous epulis.

CASE 2 MANAGEMENT

A 15-year-old female came to KPP of Dental Clinic HUSM with the main complaint of gingival swelling in the maxillary anterior region. She had used an orthodontic appliance and it was removed one week before her attendance to Dental Clinic. Gingiva had starting to lump approximately one year ago and gradually increasing it's size. There was no abnormality detected on the extra oral examination. From the intra oral examination, there was a gingival swelling around teeth 11 and 21, it was red and fluctuant consistency (2a), its diameter around 7 mm, with fair oral hygiene.⁵ Occlusal relationship in the anterior region was deep bite, with occlusal interference in protrusive movement in the central incisive region. Pocket depth 3 mm around tooth 11. Tooth 12, mesial pocket 3 mm, distal 3 mm, buccal 5 mm, and lingual 3 mm.

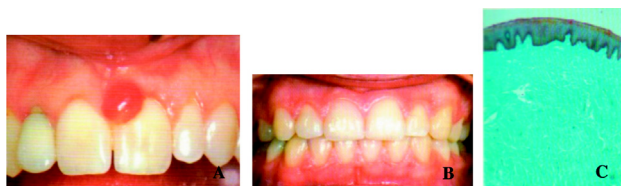

Figure 2. a) Before treatment; b) 4 weeks after treatment; c) The histologic view.

Similarly, in this case scaling and prophylaxis must be done, and the patient had to perform daily home plaque control. After oral hygiene was satisfying, then proceeds to adjust the occlusal on particular teeth. Later, surgical excision was done from this lge. Four weeks after the excision of the lesion, the gingivae were totally inflammation-free and exhibit a generally physiologic morphology (2b).

Radiographic examination showed no widening of periodontal space and no bone destruction. Histopathologically the excised lesion showed a loose granulation tissue filled with blood (2c). Clinical and

histopathological investigations assumed that its diagnosed as pyogenic granuloma.

CASE 3 MANAGEMENT

A 24-year-old female was eight months pregnant. The patient presented to KPP of Dental Clinic HUSM with a complaint of biting the swollen gum on the left side of her mouth, and profuse bleeding after brushing her teeth. According to the history, present illness, the onset of gum bleeding was long time ago whereas the lumpness on the gum had started in the first three semester. From extra oral examination, no abnormality was detected.

Intra orally revealed a severe generalized gingivitis as well as the swollen fluctuant localized growth between 34 and 35 with $7 \times 6 \times 3$ mm in size (3a), and poor oral hygiene.⁵ Occlusal relationship in the anterior region is normal Class I, but there was an open bite in the lateral side.

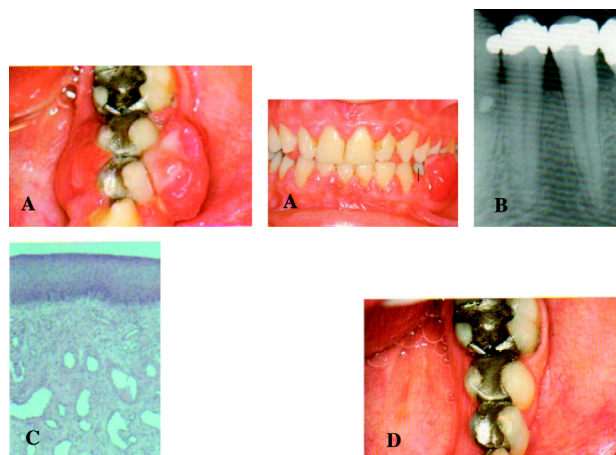


Figure 3. a) Before treatment (from lateral and anterior site); b) The radiograph of 34 and 35; c) The histologic section of gingivae; d) Three months after gingivoplasty (two months post partum).

There was occlusal interference in protrusive and lateral movements. Pocket depth was 7 mm around teeth 34 and 35, otherwise generally 4 mm. Radiographic examination depicts some horizontal loss of the crestal compact bone of the interdental septa (3b).

This case have similarity with other two cases (case 1 and 2), however it was take longer time to decide surgical intervention. During the pregnancy, motivation, repeated oral hygiene instruction, plaque and calculus removal and adjustment of particular teeth were done. In this case the redundant tissue have to be removed by gingivoplasty also during pregnancy, because the epulis was ulcerated (3a left) since the patient's maxillary teeth bite into the tissue during mastication. The histologic section (of gingiva, not the epulis) showed normal oral epithelium, a relatively mild inflammatory infiltrate and widely dilated vessels (3c).

The patient suggested to come again after given birth. Two months post partum/and three months after gingivoplasty the gingivae look pale pink in colour, the margin is knife edged and scalloped showing physiological morphology (3d). The patient suggested to come again after breast feeding is terminated for re-evaluation and further treatment planning (for restorative work).

From the clinical and pathological examinations, it was assumed as pyogenic granuloma near 34 and 35 with severe generalized pregnancy gingivitis.

DISCUSSION

Gingival enlargement may result from chronic or acute inflammatory changes. The former is by far the more common, and these cases similarly have the same history of chronic experienced. In addition, inflammatory enlargements commonly are a secondary complication to any of other types of enlargement, creating a combined gingival enlargement. In these cases it is important to understand the double etiology and treat them adequately.

These three localized gingival enlargement is caused by prolonged exposure to dental plaque. Factors that favor plaque accumulation and retention⁶ include poor oral hygiene, as well irritation by anatomic abnormalities such as occlusal interference in these cases and improper orthodontic appliances in case 2.

Based on the etiological factors, a thorough removal of dental plaque must be performed initially before proceeds to surgical therapy or excision of the gingiva. Many research, clinical trials and project in different geographical and settings have confirmed that effective removal of dental plaque is essential to dental and periodontal health throughout life.⁷ We also encourage patients to do plaque control by removing dental plaque and prevent its accumulation on the teeth and adjacent gingival surfaces by perform tooth brushing and flossing. Daily removal of dental plaque lead to resolutions of the gingival inflammation in just a few days,⁸ and carefully performed daily home plaque control, has been demonstrated to reduce supragingival plaque, decrease the total number of microorganisms in moderately deep pockets, and greatly reduce the number of subgingival sites with *Porphyromonas gingivalis*, which is a significant periodontal pathogen.⁹

After all prophylaxis/plaque control have been done, the next step was to adjust the probable irritating factors. Thinking about local irritating factor, is important to understand what kind of irritating factor presented in these cases. As stated before these three cases have similar irritating factors that favor plaque accumulation that is, occlusal interference. Interference that was happened during occlusion and produces such injury is called a traumatic occlusion.¹⁰ The dentition may be anatomically

and aesthetically acceptable but functionally injurious. Although trauma from occlusion is reversible under such conditions, it does not always correct itself, nor is it therefore always temporary and of limited clinical significance. The injurious force must be relieved for repair to occur.¹¹ We have done occlusal adjustment to remove such traumatic occlusion based on the conclusion that occlusal adjustment resulted in a more favorable attachment level.¹²

Finally after we have controlled all of the etiological and the irritating factors, the whole lesions had been carefully excised with care, placed in formal saline fixative and sent for histological confirmation of the diagnosis. Lack of care in these respects can lead to recurrence of the lesion.¹

These three cases great possibility that there may be a hormonal conditioning factor such as in the lesions occurring in the 24 year-old-female with 8 months pregnant and the other two cases with puberty 13 and 15 years-old-female. During pregnancy there is an increase in levels of both progesterone and estrogen, which, by the end of the third trimester, reach 10 and 30 times of the levels during the menstrual cycle, respectively.¹³ These hormonal changes induce changes in vascular permeability leading to gingival edema and an increased inflammatory respons to dental plaque. The subgingival microbiota may also undergo changes, including an increase in *Prevotella intermedia*.^{14,15} This condition is not observed clinically in every pregnant women, however, with poor oral hygiene like in this case a pronounced enlargement can be developed.

Concerning the other two cases, the oral hygiene of the patient is only on the average or not too bad like in the pregnancy case, but showing an increases in gingival inflammation. According with Nakagawa *et al.*¹⁶ there is statistically significant increases in gingival inflammation and in the proportions of *P. intermedia* and *Prevotella nigrescens* in puberty gingivitis.

Based on these three cases, it can be concluded that clinical periodontal therapy must be includes an understanding of our role in the total health and well-being of our patients. Female patients in there cases may present with periodontal and systemic considerations that alter conventional therapy. The cyclic nature of the female sex hormones often reflect in the gingival tissues as the initial signs and symptoms. Medical histories and dialogues should include deep investigation of the individual patient's problem and needs. Questioning should reflect hormonal stability and medications associated with regulation. Patients should be educated regarding the profound effect the sex hormones may play on periodontal and oral tissues as well as the consistent need for home and office removal of local irritants. Further informative study, regarding specific management and etiology of sex hormon-mediated infections will enhance our ability to provide quality care to our patients.

ACKNOWLEDGEMENT

These cases were presented in the 9th National Conference on Medical Sciences 22nd–23rd May 2004 in Kelantan, Malaysia. We are grateful to Prof. Ab. Rani Samsudin, Dean School of Dental Sciences for his encouragement to our participation in the conference.

REFERENCES

1. Manson, Eley. Outline of periodontics. 4th ed. New York: Wright; 2000. p. 364–5.
2. Sapp JP, Eversole LR, Wysocki GP. Contemporary oral and maxillofacial pathology. Toronto; 1997. p. 278–81, 305–7.
3. Regezi AJ, Sciubba J. Clinical pathologic correlations. 2nd ed. Philadelphia: WB Saunders Co; 1985. p. 194–6.
4. Buchner A, Calderon S, Ramon Y. Localized hyperplastic lesion of gingivae: A clinicopathological study of 302 lesion. *J Periodontol* 1997; 48(2): 125.
5. Greene JC, Vermillion JR. Oral hygiene index: a method for classifying oral hygiene status. *J Am Dent Assoc* 1960; 61: 172.
6. Thomason JM, Seymour RA, Ellis JS, et al. Determinants of gingival overgrowth severity in organ transplant patients. *J Clin Periodontol* 1996; 23: 628.
7. Lang NP, Attstrom R, Loe H, et al. Proceedings of the European workshop on mechanical plaque control. Chicago: Quintessence; 1998. p. 54.
8. Loe H, Theilade E, Jensen SB. Experimental gingivitis in man. *J Periodontol* 1965; 36: 177.
9. Hellstrom M-K, Ramberg P, Krok L, et al. The effects of supragingival plaque control on subgingival microflora in human periodontitis. *J Clin Periodontol* 1996; 23: 934.
10. Bhaskar SN, Orban B. Experimental occlusal trauma. *J Periodontol* 1995; 26: 270.
11. Polson AM, Meitner SW, Zander HA. Trauma and progression of marginal periodontitis in squirrel monkeys IV. Reversibility of bone loss due to trauma alone and trauma superimposed upon periodontitis. *J Periodont Res* 1976; 11: 290.
12. Burgett FG, Ramfjord SP, Nissle RR, et al. A randomized trial of occlusal adjustment in the treatment of periodontitis patients. *J Clin Periodontol* 1992; 19: 381.
13. Amar S, Chung KM. Influence of hormonal variation on the periodontium in women. *Periodontology* 2000; 1994. 6: 79.
14. Kornman KS, Loesche WJ. The subgingival microbial flora during pregnancy. *J Periodont Res* 1980; 15: 111.
15. Raber-Durlacher JE, van Steenberghe TJM, van der Velde U, et al. Experimental gingivitis during pregnancy and post partum: Clinical, endocrinological and microbiological aspects. *J Clin Periodontol* 1994; 21: 549.
16. Nakagawa S, Fuji H, Machida Y, et al. A longitudinal study from prepuberty to puberty of gingivitis. Correlation between the occurrence of *Prevotella Intermedia* and sex hormones. *J Clin Periodontol* 1994; 21(10): 658.