

## The thickness of odontoblast-like cell layer after induced by propolis extract and calcium hydroxide

Irfan Dwiandhono,<sup>1</sup> Ruslan Effendy,<sup>2</sup> and Sri Kunarti<sup>2</sup>

<sup>1</sup>Faculty of Medicine, Universitas Jenderal Soedirman, Purwokerto - Indonesia

<sup>2</sup>Department of Conservative Dentistry, Faculty of Dental Medicine, Universitas Airlangga, Surabaya - Indonesia

### ABSTRACT

**Background:** Propolis is a substance made from resin collected by bees (*Apis mellifera*) from variety of plants, mixed with its saliva and various enzymes to build a nest. Propolis has potential antimicrobial and antiinflammatory agents with some advantages over calcium hydroxide ( $\text{Ca}(\text{OH})_2$ ).  $\text{Ca}(\text{OH})_2$  has been considered as the “gold standard” of direct pulp-capping materials, but there are still some weakness of its application. First, it can induce pulp inflammation which last up to 3 months. Second, the tissue response to  $\text{Ca}(\text{OH})_2$  is not always predictable. Third, the tunnel defect can probably formed in dentinal bridge with possible bacterial invasion in that gap. **Purpose:** This study was aimed to determine and compare the thickness of odontoblast-like cells layer after induced by propolis extract and  $\text{Ca}(\text{OH})_2$  in rat's pulp tissue. **Method:** Class 1 preparation was done in maxillary first molar tooth of wistar mice until the pulp opened. The  $\text{Ca}(\text{OH})_2$  and propolis extract was applied to induce the formation of odontoblast-like cells, the cavity was filled with RMGIC. The teeth were extracted (after 14 and 28 days of induction). The samples were then processed for histological evaluation. **Result:** There were significant differences between the thickness of odontoblast-like cells after induced by propolis extract and  $\text{Ca}(\text{OH})_2$ . **Conclusion:** The propolis extract as the direct pulp capping agent produces thicker odontoblast-like cell layer compared to  $\text{Ca}(\text{OH})_2$ .

**Keywords:** odontoblast-like cells; propolis; calcium hydroxide

**Correspondence:** Irfan Dwiandhono, Faculty of Medicine, Universitas Jenderal Soedirman. Jl. Dr. Gumbreg No. 1 Purwokerto 53123, Jawa Tengah, Indonesia. E-mail: irfandrg@gmail.com Telp. +62 281 643744.

### INTRODUCTION

The aim of direct pulp capping treatment is to maintain the pulp's vitality, by protecting the pulp from bacterial penetration and inducing dentinal bridge formation. The success of the pulp capping procedure greatly depends upon the capacity of the capping material to perfectly seal the tubuli, non irritative, protect the pulp from the mechanical, chemical, and bacterial irritation, induce fibroblast and odontoblast cell to form reparative dentin and dentinal bridge.<sup>1</sup>

Calcium hydroxide [ $\text{Ca}(\text{OH})_2$ ] is the most accepted and commonly used pulp capping material. It stimulates the pulp tissue on the formation of dentinal bridge and inhibits

bacterial growth. Nevertheless, application of calcium hydroxide in direct pulp capping has some drawbacks. The high pH (12.5) of  $\text{Ca}(\text{OH})_2$  suspensions causes liquefaction necrosis at the surface of the pulp tissue with the formation of a necrotic layer at the material-pulp interface. The toxicity of  $\text{Ca}(\text{OH})_2$  reduced in deeper pulp layer, causing coagulation necrosis to the average degree of irritation. In this zone of coagulation necrosis, the differentiation of odontoblast-like cells and the formation of dentinal bridge occurred.<sup>2</sup>

Several studies related to pulp capping materials had been conducted to determine the most appropriate pulp capping material with good biocompatibility. The success

rate of calcium hydroxide as pulp capping material were 80,1% after a year, 68,0% after 5 years, and 58,7% after 9 years.<sup>3</sup>

The drawbacks of  $\text{Ca}(\text{OH})_2$  as pulp capping material are: (1) it can induce pulp inflammation which last up to 3 months, (2) unpredictable tissue response, (3) the reparative dentin formed below  $\text{Ca}(\text{OH})_2$  is irregular, the and the tunnel defect can probably formed. The defect is formed because of the tissue inclusion on the dentinal bridge. This resulted in increasing dentinal bridge's permeability for possible bacterial invasion.<sup>4</sup>

Propolis is a substance made from resin collected by bees (*Apis mellifera*) from variety of plants, mixed with its saliva and various enzymes to be a whole different kind of resin, and used by bees to build a nest.<sup>5</sup> The color of this whole new resin is brown to dark brown. It is sticky at room temperature, but hard and fragile at low temperature. Propolis has broad-spectrum biological and pharmacological activity, anti-bacterial, anti-virus, anti-oxidant, and anti-inflammation material. Propolis consists of 55% resin, 30% bee's wax and aromatic oils, 5% bee pollen, and 10% other substances (amino acid, minerals, ethanol/alcohol, vitamin A, B complex, E, and bioflavonoid).<sup>6</sup>

Many studies related to propolis extract as direct pulp capping material has been conducted, but the exact mechanism of action remains unclear. Propolis extract with flavonoid was proven to reduce inflammation and to form dentinal-bridge in 4th weeks after pulp capping treatment on Sprague-Dawley rats.<sup>7</sup>

Direct pulp capping treatment with propolis and mineral trioxide aggregate (MTA) in human was succeed to form dentinal bridge on the 15th day, whereas in the group treated with  $\text{Ca}(\text{OH})_2$  the dentinal bridge was not found.<sup>8</sup> In other study, MTA and novel endodontic cement (NEC) in dog's teeth after 8 weeks was giving better result in pulp capping and dentinal bridge formation compared to calcium hydroxide.<sup>9</sup>

The aim of this study was to analyze histological process of dentinal bridge formation by measuring the thickness of the odontoblast like cells on the pulp of Wistar rats' teeth after pulp capping treatment using propolis and  $\text{Ca}(\text{OH})_2$ .

## MATERIALS AND METHODS

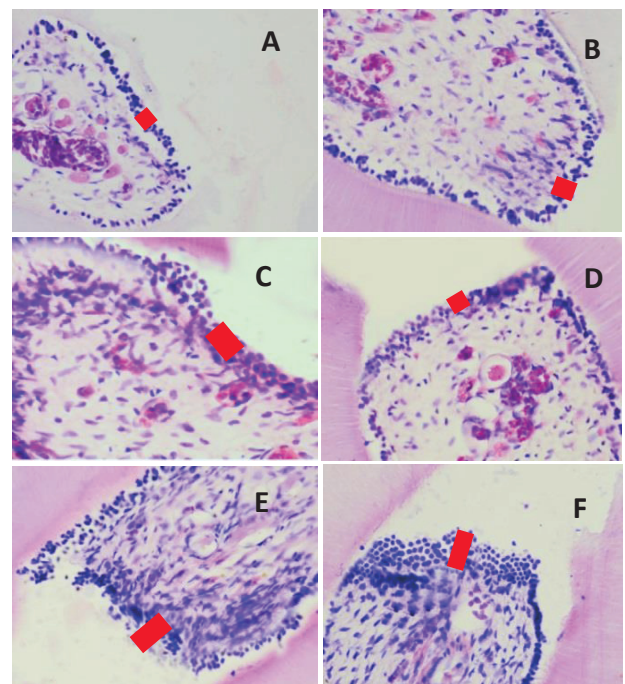
This research was an experimental laboratory study, with 42 male Wistar rats as samples (healthy, weighing 200-250 gr, 8-16 month-old, with fully erupted molars). The adaptation time given was 2 weeks. The samples were divided into 6 groups as follow: Group I (Control Group I/the pulp was perforated, filled with GIC, observed on the 14th day), Group II (Control Group II/ the pulp was perforated, filled with GIC, observed on the 28th day), Group III (the pulp was perforated, applied with propolis

extract, filled with GIC, observed on the 14th day), Group IV (the pulp was perforated, applied with propolis extract, filled with GIC, observed on the 28th day), Group V (the pulp was perforated, applied with calcium hydroxide, filled with GIC, observed on the 14th day), and Group VI (the pulp was perforated, applied with calcium hydroxide, filled with GIC, observed on the 28th day). The pulp capping material amount was 0,5 mg for each application.

The euthanasia process was performed, followed by decapitation and maxilla separation. Rat's molars were sectioned parallel to the axis using microtome to  $7\mu\text{m}$ . The samples were then stained with hematoxylin and eosin. Assessment of the normality of the data was determined with Kolmogorov smirnov test. Assessment of the homogeneity of the data was determined with Levene test. The statistically significant differences were determined with Independent T-test.

## RESULT

The histological examination to see the thickness of odontoblast-like cells was done at 200x magnification. The thickness of odontoblast-like cells was defined as the thickness of the new cells found below the perforation area. The result of the thickness of the dentin can be seen in Figure 1.



**Figure 1.** The thickness of the odontoblast-like cells in rats' teeth (at 200x magnification). The red marked area shows the thickness of the odontoblast-like cells. A. Control group on the 14<sup>th</sup> day, B. Control group on 28<sup>th</sup> day, C.  $\text{Ca}(\text{OH})_2$  group on the 14<sup>th</sup> day, D.  $\text{Ca}(\text{OH})_2$  group on the 28<sup>th</sup> day, E. Propolis extract group on the 14<sup>th</sup> day, F. Propolis extract group on the 28<sup>th</sup> day.

Kruskall-wallis revealed that there was significant difference in the thickness of odontoblast-like cells after 14 days and 28 days of treatment ( $p < 0,05$ ) on Table 1. Independent t-test revealed that there was significant difference ( $p < 0,05$ ) between  $\text{Ca(OH)}_2$  groups and propolis extract groups.

Table 2 shows that on the 14<sup>th</sup> day, there was significant difference ( $p < 0,05$ ) between the three groups (positive control group,  $\text{Ca(OH)}_2$  group, and propolis extract group). The thickness of odontoblast-like cells in positive control group was thinner than the propolis extract group. The significant difference was also found between  $\text{Ca(OH)}_2$  group and propolis extract group, it shows that the thickness of odontoblast-like cells in  $\text{Ca(OH)}_2$  group was thinner than the propolis extract group

Independent t-test revealed that on the 28<sup>th</sup> day, there was significant difference ( $p < 0,05$ ) between the three groups (positive control group,  $\text{Ca(OH)}_2$  group, and propolis extract group). The thickness of odontoblast-like cells in positive control group was thinner than the  $\text{Ca(OH)}_2$  group and propolis extract group. The significant difference was also found between  $\text{Ca(OH)}_2$  group and propolis extract group, it shows that the thickness of odontoblast-like cells in  $\text{Ca(OH)}_2$  group was thinner than the propolis extract group.

Table 3 shows that there were significant differences

**Table 1.** Mean and standard deviation of odontoblast-like cells thickness in 14<sup>th</sup> and 28<sup>th</sup> day

Groups		Mean (mm)	Std. Deviation
14 <sup>th</sup> day	Positive Control	0,022	0,005
	$\text{Ca(OH)}_2$	0,035	0,013
	Propolis	0,084	0,012
28 <sup>th</sup> day	Positive Control	0,032	0,005
	$\text{Ca(OH)}_2$	0,056	0,015
	Propolis	0,104	0,012

**Table 2.** Independent t-test result of odontoblast-like cells thickness on the 14<sup>th</sup> and 28<sup>th</sup> day

Groups	$\text{Ca(OH)}_2$		Propolis	
	14 <sup>th</sup> day	28 <sup>th</sup> day	14 <sup>th</sup> day	28 <sup>th</sup> day
Positive Control	14 <sup>th</sup> day	0,037*	0,000*	
	28 <sup>th</sup> day	0,004*		0,000*
$\text{Ca(OH)}_2$	14 <sup>th</sup> day	-	0,000*	
	28 <sup>th</sup> day	-	0,000*	

\*  $p < 0,05$  = there was significant difference

**Table 3.** Independent t-test result of odontoblast-like cells thickness on the 14<sup>th</sup> and 28<sup>th</sup> day

Groups	Positive Control 28 <sup>th</sup> day	$\text{Ca(OH)}_2$ 28 <sup>th</sup> day	Propolis 28 <sup>th</sup> day
Positive Control 14 <sup>th</sup> day	0,010*		
$\text{Ca(OH)}_2$ 14 <sup>th</sup> day	0,017*		
Propolis 14 <sup>th</sup> day	0,030*		

\*  $p < 0,05$  = there was significant difference

in the thickness of odontoblast-like cells between 14th day and 28th day of positive control group,  $\text{Ca(OH)}_2$  group, and propolis extract group. Kruskal-wallis revealed that there were significant differences between all groups. Independent t-test revealed that there that there were significant differences in the thickness of odontoblast-like cells between 14th day and 28th day of positive control group,  $\text{Ca(OH)}_2$  group, and propolis extract group.

**DISCUSSION**

The basic principle of conservation treatment is to maintain the condition and function of the dentin-pulp complex, especially in the case when the pulp is perforated. Like the other connective tissues, pulp tissue has the capacity to repair themselves. The characteristic of healing process of the perforated pulp tissue is the reorganization of the damaged soft tissue, fibroblast cell differentiation into odontoblast-like cells, and the reparative dentin formation on the perforated soft tissue.<sup>10</sup>

The damage in the pulp tissue will resulted in inflammation reaction to eliminate the substance that endanger the tissue or to avoid further destruction of the pulp tissue. The inflammation reaction is the early step of the healing process. At the time when tissue is injured, the fibroblasts would soon migrate toward the wound, proliferate and produce large amounts of collagen matrix that will help to isolate and repair the damaged tissue.<sup>11</sup>

Growth factor plays an important role in responding to the injury and tissue repair.<sup>12</sup> Caries is estimated to trigger the odontoblast activity to increase the expression of TGF- $\beta$ 1. The TGF- $\beta$ 1 that was dissolved in matrix is released.<sup>13</sup> TGF- $\beta$ 1 is an important regulator in proliferation and differentiation of the human’s pulp cells during the formation and dentin repair process.<sup>14</sup> TGF- $\beta$ 1 binds to TGF- $\beta$ R, the TGF- $\beta$ 1 receptor, which then activates the cell cycle to proliferate. TGF- $\beta$ 1 will regulate the proliferation process, the cell cycle running normally, and ready for the next step. The cell undergo the mitosis process to differentiate into odontoblast-like cells, characterized by

the type I collagen and dentin matrix protein (DMP1), as well as an increase in activity of alkaline phosphatase (ALP). Increased ALP activity stimulates the release of minerals from the cell to start mineralization, then the process of mineral formation occurs. The hydroxy-apatite deposits and merge into collagen matrix in mineralization process. The synthesis of DMP1 increases, interact with type 1 collagen to form a sequence and undergo mineralization, and the reparative dentin formation occurs.<sup>15</sup>

The results of this study showed that the dead odontoblast was only found below the perforated area. In the intact dentin at the edge of the perforated area the damaged odontoblast was found. The growth area of the odontoblast-like cells was presumably derived from the differentiation process of fibroblasts in the pulp tissue. There are three possible sources of forming odontoblast-like cells. First, odontoblast-like cells formed by progenitor cells of odontoblast, known as undifferentiated mesenchym. These cells are located in the cell-rich zone of Hohl. Second, odontoblast-like cells derived from pulp fibroblasts, as fibroblasts belongs to stable cell that can differentiate when there is injury or stimuli. The third is the de-differentiation of odontoblasts. Although odontoblasts belongs to postmitosis, but the possibility of differentiation is still open even if it's small.<sup>16</sup>

All primary odontoblasts is an irreversible injury in the area of perforation. Post-mitotic, a terminal cell differentiation can not proliferate to replace dead or damaged odontoblasts. As the result, this primary odontoblasts should be replaced by a new generation of cell odontoblast-like cells. New odontoblast-like cells proliferate from other pulp cells and migrate to perforated area, the place where the reparative dentin secreted. Progenitor cells of new odontoblast-like cells assumed as cells from the subodontoblast layer or pulp fibroblasts.<sup>17</sup>

In the de-differentiation process, the odontoblast cell is not turned young and pluripotent, but still unipotent and just divide from the cell with the same structure and function with the related cell. There are two mechanisms of reparative dentinogenesis. First, the direct differentiation induced by dentin matrix, and second, the odontoblast-like cells differentiation through fibrodentin matrix that acts as the basal lamina for the differentiation of odontoblast-like cells for tooth repair.<sup>18,19</sup>

The thickness of the odontoblast-like cells layer in Ca(OH)<sub>2</sub> group in 14th and 28th day is thinner than the propolis extract's. The high pH (12.5) of calcium hydroxide suspensions causes liquefaction necrosis at the surface of the pulp tissue, causing coagulation necrosis in the area between necrotic pulp and vital pulp. When the pure form of Ca(OH)<sub>2</sub> is applied on the pulp, it actually will destroy some of the pulp's tissue, causing a persistent inflammation. Molecularly, the calcium ions released by Ca(OH)<sub>2</sub> stimulates the synthesis of fibronectin and glycoproteins tenascin in dental pulp, triggering differentiation of dental pulp cells into cells forming minerals that are the main cells

to form dentin bridge. Ca(OH)<sub>2</sub> also stimulates the release of adrenomedullin and TGF-β1 of human dentin matrix, both are pluripotent growth factors.<sup>4,16</sup>

Propolis extract has known to have antibacterial activity, anti-inflammatory, antioxidant and immunomodulator. The prevention of infection and the promotion of cell regeneration ease the the healing process in the dental pulp that begins with the collagen fibers formation.<sup>7</sup> Flavonoids and caffeic acid in propolis extract can reduce the inflammatory response by inhibiting arachidonic acid lipoxigenase pathway. As antibacterial agent, propolis destroys the bacteria's cell wall and prevents bacterial cell division.

Propolis extract was more effective to form dentin compared to calcium hydroxide or zinc oxide.<sup>7,20</sup> Propolis extract inhibits the translation of NFκβ into the nucleus to prevent the apoptosis. The inhibition of apoptosis result in prevention of drastic decreasing amount of fibroblast in the pulp and activation of NFκβ. The activation of NFκβ inhibits the transcription of genes that secrete TNF-α.

The increase of TGF-β1 expression is a host defense mechanism. Dentin formation after pulp capping involves differentiation of odontoblast-like cells that form reparative dentin and the biosynthetic activity of the components around the primary odontoblast. It requires an interaction between extra cellular matrix molecules and TGF-β1, which is a growth factor that is known to play an important role in the differentiation of odontoblast-like cells.

Propolis extract enhances the formation of odontoblast-like cells and stimulates the production of TGF-β1.<sup>7</sup> TGF-β1 stimulates the proliferation of fibroblasts, a fibrogenic substance that stimulates the fibroblasts chemotaxis to increase the formation of collagen, fibronectin, and proteoglycans.<sup>21</sup>

This ability of propolis extract to inhibit inflammation, suppress apoptosis, stimulates the production of TGF-β1 and differentiation of fibroblasts explains the result of this study, where the thickness of odontoblast-like cells layer in perforated rat's pulp after the application of propolis extract is significantly thicker than the calcium hydroxide group. The conclusion, the propolis extract as the direct pulp capping agent produces thicker odontoblast-like cell layer compared to Ca(OH)<sub>2</sub>.

## REFERENCES

1. Torabinejad M, Walton RE. Endodontics: principles and practice. 4th ed. Missouri: Saunders; 2009. p. 9-14.
2. Hargreaves KM, Berman LH, Cohen S. Cohen's pathways of the pulp expert consult. 10th ed. St. Louis: Mosby; 2011. p. 490, 518, 626, 812.
3. Willershausen B, Willershausen I, Ross A, Velikonja S, Kasaj A, Blettner M. Retrospective study on direct pulp capping with calcium hydroxide. Quintessence Int 2011; 42(2): 165-71.
4. Janebodin K, Horst OV, Osathanon T. Dental pulp response to pulp capping materials and bioactive molecules. CU Dent J 2010; 33: 229-48.

5. Bankova V, Castro SD, Marcucci M. Propolis: recent advances in chemistry and plant origin. *Apidologie*, Springer Verlag 2000; 31(1): 3–15.
6. Almas K, Dahlan A, Mahmoud A. Propolis as a natural remedy: an update. *Saudi Dent J* 2001; 13(1): 45-9.
7. Sabir A, Tabbu CR, Agustiono P, Sosroseno W. Histological analysis of rat dental pulp tissue capped with propolis. *J Oral Sci* 2005; 47(3): 135-8.
8. Parolia A, Thomas MS, Kundabala M, Mohan M. Propolis and its potential uses in oral health. *Int J Med Med Sci* 2010; 2(7): 210-5.
9. Asgary S, Eghbal MJ, Parirokh M, Ghanavati F, Rahimi H. A comparative study of histologic response to different pulp capping materials and a novel endodontic cement. *Oral Surg Oral Med Oral Pathol Oral Radiol Endod* 2008; 106(4): 609-14.
10. Tziafas D, Smith AJ, Lesot H. Designing new treatment strategies in vital pulp therapy. *J Dent* 2000; 28(2): 77-92.
11. Hargreaves KM, Goodis HE. Seltzer and Bender's dental pulp. Hanover Park: Quintessence Publishing Co, Inc; 2002. p. 247-79.
12. About I, Bottero MJ, de Denato P, Camps J, Franquin JC, Mitsiadis TA. Human dentin production in vitro. *Exp Cell Res* 2000; 258(1): 33-41.
13. Sloan AJ, Perry H, Matthews JB, Smith AJ. Transforming growth factor-beta isoform expression in mature human healthy and carious molar teeth. *Histochem J* 2000; 32(4): 247-52.
14. Shirakawa M, Shiba H, Nakanishi K, Ogawa T, Okamoto H, Noshiro M, Kato Y. Transforming growth factor-beta-1 reduces alkaline phosphatase mRNA and activity and stimulates cell proliferation in cultures of human pulp cells. *J Dent Res* 1994; 73(9): 1509-14.
15. Widjiastuti I, Yuanita T, Hutagalung J, Rukmo M, Safitri I. 2014. East java propolis inhibits cytokine pro-inflammatory in odontoblast-like cells human pulp. *Journal of Agricultural Science and Technology A* 2014; 4(1): 27-32.
16. Kunarti S. Pulp tissue inflammation and angiogenesis after pulp capping with transforming growth factor  $\beta$ 1. *Dent J (Majalah Kedokteran Gigi)* 2008; 41(2): 88-90.
17. Murray PE, Windsor LJ, Smyth TW, Hafez AA, Cox CF. Analysis of pulpal reactions to restorative procedures, material, pulp capping, and future therapies. *Crit Rev Oral Biol Med* 2002; 13(6): 509-20.
18. Yatim W. *Biologi sel lanjut*. Bandung: Tarsito; 2003. p. 1-84.
19. Goldberg M, Smith AJ. Cell and extracellular matrices of dentin and pulp: a biological basis for repair and tissue engineering. *Crit Rev Oral Biol Med* 2004; 15(1): 13-27.
20. Ahangari Z, Naseri M, Jalili M, Mansouri Y, Mashhadiabbas F, Torkaman A. Effect of propolis on dentin regeneration and the potential role of dental pulp stem cell in Guinea pigs. *Cell J* 2012; 13(4): 223-8.
21. Kumar, Abbas, Fausto, Robbins & Cotran *Dasar Patologis Penyakit*. 7th ed. Jakarta: EGC; 2010. p. 101.