

Expression of CD133 in various premalignant and proliferative lesions

Rahmi Amtha,¹ Indrayadi Gunardi,² Ferry Sandra,³ and Diah Savitri Ernawati⁴

^{1,2}Department of Oral Medicine, Faculty of Dentistry, Universitas Trisakti, Jakarta - Indonesia

³Laboratory of BioCore, Faculty of Dentistry, Universitas Trisakti, Jakarta - Indonesia

⁴Department of Oral Medicine, Faculty of Dental Medicine, Universitas Airlangga, Surabaya - Indonesia

ABSTRACT

Background: In Jakarta, oral squamous cell carcinoma (OSCC) usually detected in late stage with very low survival rate of about 1.1 years. OSCC may be preceded by premalignant lesion, so that early detection of the lesion may decrease the mortality rate due to oral malignancy. CD133 is a hematopoietic stem cell that play role in tissue regeneration, inflammation and tumor. Upregulated of CD133 was reported on tumor progression. **Purpose:** The aim of study is to determine circulating CD133 expression on premalignant (PML) and proliferative (PL) lesion. **Method:** Observational research was carried out on patients who seek treatment of PML and PL at Oral Medicine clinic. CD133 was taken from peripheral blood serum, examined using PCR. Data was analyzed by Chi square test. **Result:** 15 subjects (each of five subjects for PML, PL and control) consist of 40% male and 60% female. Age group of above 41 years old was most affected PML and PL (66.7%). Tongue is common site for oral lesion (40%). There is a significant different of circulating CD133 rate among all groups lesion ($p=0.039$). **Conclusion:** CD133 express differently in premalignant and proliferative lesions.

Keywords: CD133; premalignant; proliferative

Correspondence: Rahmi Amtha, c/o: Departemen Penyakit Mulut, Fakultas Kedokteran Gigi Universitas Trisakti. Jl. Kyai Tapa No. 1 Grogol, Jakarta Barat, Indonesia. E-mail: rahmi.amtha@gmail.com

INTRODUCTION

Squamous cell carcinoma (SCC) is one of the most common cancers found in the oral cavity. It occurs almost 90% of all other types of cancer in the body.¹ The number of oral cancer in the world increases annually, including in Indonesia. The risk factors of oral SCC are multifactorial. One of them are tobacco use, alcohol drinking and betel quid chewing habit.² Each country has different number of prevalence of SCC, depend on their most risk factors applied in their society. It is also found that clinically SCC can be developed from lesions in the mouth called premalignant lesion.

Oral lesions can be found either in the form of a normal variant or pathologic lesions. Variants of the normal oral lesions such as torus, fissure tongue, geographic tongue, linea alba, frictional keratosis, Fordyce spots, pigmentation physiological, lingual tonsils, and median rhomboid glossitis. The pathological lesions can be as benign lesion

of the oral cavity is including benign tissue growth (such as papilloma, fibroma, epulis, cysts etc.) and pathologic lesions such as premalignant lesions, infections, hypersensitivity, autoimmune, systemic disease manifestations, as well as lesions caused by the treatment of systemic manifestations.² Premalignant lesions that usually found are leukoplakia, erythroplakia, oral lichen planus, lichenoid reaction, and submucous fibrosis.

Most of SCC patients in Jakarta population who come and need treatment was already in advanced/ late stage. Its survival rate was very short, that was only about 1.1 years. This is likely due to lacking of early detection system of premalignant lesions that are clinically symptomless but microscopically already have dysplasia cell that potentially turn to malignant transformation.³

One of the factors that can affect changes in cells, which end up to uncontrolled cells, was involving the environment. In the human body, there are known as stem cells that can be transformed into the desired cell. In its

development stem cell itself is also strongly influenced by external factors and internal cells. External factors such as the environment or habits that lead individuals exposed to substances that are carcinogenic, systemic disease, drugs, etc.⁴ Whereas internal factors are including the factors, which are found in the body such as the genetic, hereditary carried by each individual, the cancer stem cell (CSC) and growth factors that exist in the surrounding environment such as cells and other hormone.⁵ CSC defines as a small subpopulation of cancer cells that form a pool of autonomous cell with the exclusive ability to make the heterogeneous lineages of cancer cells that comprehend the tumor.⁶ There are three main characteristic of CSCs. First, the cell must show ability of initiation of tumor formation and it can revive the tumor that it was derived from a limited number of cells. The second, cells should show self-renewal in-vivo, which is practically observed through the regrowth of phenotypically indistinguishable and heterogeneous tumor following serial transplantation of relocated CSCs in secondary and tertiary recipients. The third, cells must show a differentiation capacity allowing them to give rise to a heterogeneous progeny which represent a phenocopy of the original tumour.⁷

Recently, CSC study is widely done, because a lot of indications and prognostic value can be generated and useful to the clinician in determining the management of malignancy. The existence of CSC is considered to be one of the factors which led to a pathologic lesion may become more aggressive, more resistant to cancer treatment and the possibility of metastasis. The prognostic value of the finding can change the paradigm of cancer management by controlling the CSC population. CSC can be found in the area where the tumor lesions were obtained and in the bloodstream that are called circulating cancer stem cell (CCSC). CCSC have been found in some cancer in the human body such as breast cancer, brain and blood cancer. The types of CCSC are CD133, CD24, CD44, CD26, ALDH, and others.^{8,9}

CD133 is a hematopoietic stem cell that is cholesterol interacting penta-span transmembrane glycoprotein (120kd), play a role in tissue regeneration, inflammation and tumors.^{10,11} The function of CD133 is unknown, but is expressed in biological stress. CD133 can be found on cancer stem cells.¹² Disorders of the cell mitosis that causes asymmetric cell tumors associated with the expression of CD133 positive. CD133 may enrich the CSC to 200 times in human tumor tissues.¹³ By evaluating CD133 in the peripheral blood, the clinical output can be predicted and the success of the treatment can be improved. Although the function of CD133 is unknown but previous study demonstrated that CD133 is a marker of CSCs in various tumors.¹⁴⁻¹⁸ Research on the expression of one of the CSC in premalignant lesions and benign lesions in the oral cavity is still very rare, especially that drawn from the population of Indonesia. Therefore, it is deemed to know how the presence of circulating CD133 in premalignant lesions and benign lesions of the oral cavity. It can be

useful as a baseline data to look for the correlation of CSC expression in the tumor tissue. It is finally useful to predict the prognostic of lesions and treatment planning to prevent malignancy earlier.

CD133 (Prominin-1) is derived from prominin family found on hematopoietic stem cells, called AC133.¹⁹ Therefore, CD133 is cholesterol interacting penta-span transmembrane glycoprotein (120kd), then carried by circulating CD133 endothelial progenitors (CEP) and plays a role in tissue regeneration, inflammation and tumors.^{10,11} Until now, there are three isoforms, namely CD133-1, CD133-2 and CD133-3. The function of CD133 is unknown, but it is expressed in the change process including biological stress. It is known that by eliminating CD133 from the tissue, there will be no formation of new CD133, but this condition will stimulate the mammary glands to form new branching. While CD133 mutation (R733C) will cause retinal disorders.¹²

CD133 can be found on cancer stem cells.¹² Disturbances in embryo cell division that causes asymmetric cell associated with the expression of the CD133 (+) tumor cells. The cancer that have a high concentration of CD133 (+), associated with cancer resistant to radiation and chemotherapy treatments. CD133 high concentration is also associated with poor prognosis of some solid tumors such as lung, colon, and prostate.^{12,17,18}

Although the function of CD133 is unknown but it can be demonstrated that CD133 is a marker of cancer stem cells in various tumors.¹⁴⁻¹⁸ Relative to CD133, a number of studies have demonstrated the expression of CD133 on a subpopulation of cancer cells from the brain, colon, lung, melanoma and other tumors. This indicates that the assumption that these cells have the ability of stem cells or progenitors and CD133 is considered as a marker of cancer stem cells.^{18,20-22}

Premalignant lesions are oral lesions that have a potential to turn to malignant or oral cancer. These lesions are including: leukoplakia, erythroplakia, lichen planus and submucous fibrosis. Many literature reported that the premalignant lesions has tendency to become oral cancer in about 1-5.6 % depend on the country and risk factors applied in their community.² Besides the premalignant lesions, it is also known benign lesion that have no potencies to turn to malignant or oral cancer. These lesions including: mucocel, papilloma, fibroepitelial polyp and epulis.^{4,25}

MATERIALS AND METHODS

A cross sectional observational research was carried out on patients who have suffered premalignant lesion (PML: leukoplakia, erythroplakia, oral lichen planus, lichenoid reaction, and submucous fibrosis.) and proliferative lesion (PL) such as papilloma, fibroma, epulis, and cysts that seek treatment to oral medicine clinic under informed consent. Based on sample size calculation, fifteen of patients are needed in this research that will represent each of group of

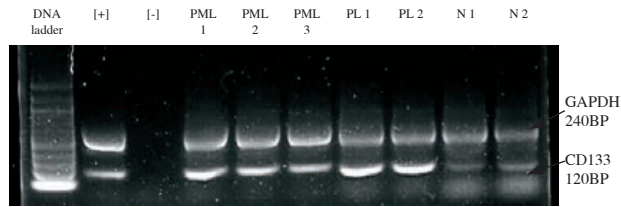


Figure 1. Expression of CD133 and GAPDH (control gene) is positive in all samples of the study.

Note: PML: premalignant lesions, PL: proliferative lesions, N: no lesions.

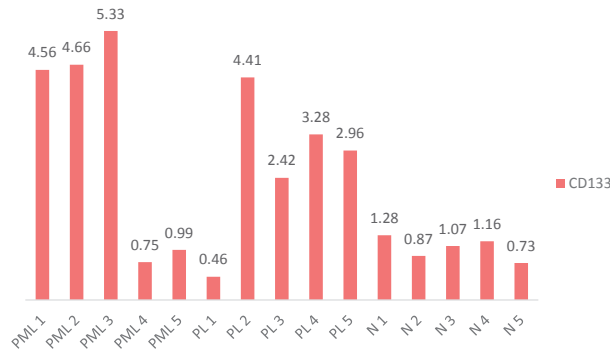


Figure 2. CD133 ratio on different lesions.

PML, PL and normal as a control. CD133 was taken from peripheral blood serum of 15 patients. The expression of CD133 was examined by using PCR and data was analyzed by Chi square test.

RESULTS

The study was conducted at the Dental Hospital of Faculty of Dentistry Universitas Trisakti from September 2013 to July 2014, obtained sample of 15 subjects were then divided into 3 groups of premalignant lesions (33.3%), proliferative lesions (33.4%) and normal lesions (33.5%). Table 1 showed that most of the sample was female (60%), older than 41 years (66.7%) and 40% most of the location is in the area of the tongue. From each sample, 5 mL of blood were taken and CD133 expression examined using PCR technique with followed by glyceraldehyde 3-phosphate dehydrogenase (GAPDH) as a guardian gene to confirm the presence of CD133 genes (Figure 1). CD133 was express at 120 bp and GAPDH was expressed at 240 bp. CD133 and GAPDH were found expressed at all samples with different quantity (Figure 2). There was a significant different ($p=0.039$) of CD133 expression of three groups (PML, PL and normal samples) as shown at Table 2.

DISCUSSION

Based on the literature, premalignant lesions are lesions that have the potential to malignant transformation or squamous cell carcinoma. The changes varied from

0 to 5.6% within 1 to 10 years. Socio-demographic characteristics of this study showed that premalignant lesions are more common in women than men, aged over 40 years and this is in accordance with many other studies.^{24,26} Tongue is the most common predilection of PML compared to other area. This result is also the same with many other studies.²⁷ Tongue as the most predilection site of PML and PL may be due to the nature of the tongue that prone to get trauma during mastication, speaking and other activities. Besides that tongue has different texture of epithelium compared to buccal mucosa and other area in the mouth. The papillae of the tongue makes specific texture that predisposes the trap of food and increases the exposure of microorganism to the epithelium that may induce the inflammation. CD133 is a transmembrane glycoprotein that has 865 amino acids with a total molecular weight of 120kDa.²⁸ CD133 gene expression seen in conjunction with the guardian gene called GAPDH on 120 bp and 240 bp respectively. CD133 ratio was obtained from a comparison between CD133 and GAPDH quantitative calculations. The ratio helped to assay the consistency of PCR mix reaction. The quantity of expression (ratio) of CD 133 was calculated from the mean of both of them (GAPDH and CD 133).

This study found an increase in CD133 expression (Figure 1) that circulate in the peripheral blood sample with premalignant lesions and proliferative lesions compared to normal samples (no lesions). CD133 ratio increased on premalignant lesions and proliferative lesions (Figure 2) compared to normal. It demonstrates that CD133 is a cell that circulates in the peripheral blood circulation and the amount increase when one part of oral tissue stimulated/irritated or undergoing cells proliferation. This is consistent with the function of progenitor cells that will adjust depending on the environment they entered. The above-

Table 1. Socio-demographic characteristics of the sample

	n	%	SD
Age			
20-30	3	20	
31-40	2	13.3	0.843
>41	10	66.7	
Sex			
Male	6	40	0.507
Female	9	60	
Oral lesions			
Premalignant	5	33.3	0.845
Proliferative	5	33.4	
Normal	5	33.5	
Location			
Tongue	6	40	0.516
Buccal mucosa	4	26.7	
o thers	5	33.3	

Table 2. CD133 expression on different lesions

Lesion	CD133			p
	Low n(%)	Middle n(%)	High n(%)	
PML	2(40)	0(0)	3(60)	0.039*
Proliferative	1(40)	0(0)	3(60)	
Normal	2(40)	3(60)	0(0)	

Note: p<0.05

mentioned conditions are categorized that the increased CD133 is normal cell or not a cancer stem cell. However, if the CD133 increased in premalignant lesions, which later histopathologically proved the presence of dysplasia, then the type of this CD133 is most probably a cancer stem cell. It is suitable with the characteristic of CD133 that expression more biological stress conditions.¹⁰ CD133 was found to increase up to 200 times of the amount of CSC in human tumor tissues.¹¹ Therefore, ideally the histopathological examination of CD133 on the tissue is required to be observed to see the correlation and also confirm by other marker of CDs groups such as CD44. The results of this preliminary study was also supported by several other studies that showed a significant increase (p=0.002) of CD133 in lichen planus lesions that turn into squamous cell carcinoma.²⁸ The existence of a variety of gene expression and chemical mediators/cytokines in premalignant lesions have been studied and proved a meaningful relationship. The discovery of chronic inflammatory cells in all premalignant lesions is assumed to contribute significantly to changes in these lesions into oral cancer. Inflammatory process is able to create a microenvironment that can affect the growth, proliferation and differentiation of cells that end up on the condition of genetic mutations.²⁶ Mutated cells will lead to uncontrolled proliferation and known malignancy (cancer). Stem cells are also influenced by micro-environmental conditions surrounding and under certain conditions can be transformed into stem cells, called cancer stem cells.⁶ The existence of cancer stem cells have been widely demonstrated to see the prognosis of a disease, effects of therapy and even help to see the prognosis of malignant transformation in some diseases.^{10,11} Until now there is absence of study discuss about the association of expression of CD133 in above lesions. This study found that CD133 is expressed in premalignant and proliferative lesions as well as normal conditions differently. So that it may be useful as basic information for further study to see their correlation in carcinogenesis.

REFERENCES

1. Thompson P. Oral precancer: diagnosis and management of potentially malignant disorders. First edition. Oxford: John Wiley & Sons, John Wiley; 2012. p. 1-12.

- Scully C. Oral and maxillofacial medicine the bases of diagnosis and treatment. 2nd ed. Edinburgh: Churchill Livingstone; 2008. p. 289-90.
- Amtha R. Risk factor and genetic polymorphism of oral cancer in Jakarta population. Case Control Studies. Dissertation. Kuala Lumpur: University of Malaya; 2007.
- Bourseau-Guilmain E, Griveau A, Benoit JP, Garcion E. The importance of the stem cell marker prominin-1/CD133 in the uptake of transferrin and in iron metabolism in human colon cancer Caco-2 cells. *PLoS One* 2011; 6(9): e25515.
- Yunoue S, Arita K, Kawano H, Uchida H, Tokimura H, Hirano H. Identification of CD133+ cells in pituitary adenomas. *Neuroendocrinology* 2011; 94(4): 302-12.
- Major AG, Pitty LP, Farah CS. Cancer stem cell markers in head and neck squamous cell carcinoma. *Stem Cells Int* 2013; 2013: 319489.
- Chen Z. The cancer stem cell concept in progression of head and neck cancer. *J Oncol* 2009; 2009: 894064.
- Greaves M. Cancer stem cells as 'units of selection'. *Evol Appl* 2013; 6(1): 102-8.
- Ewald PW, Swain Ewald HA. Toward a general evolutionary theory of oncogenesis. *Evol Appl* 2013; 6(1): 70-81.
- Asahara T, Murohara T, Sullivan A, Silver M, van der Zee R, Li T, Witzenbichler B, Schatteman G, Isner JM. Isolation of putative progenitor endothelial cells for angiogenesis. *Science* 1997; 275(5302): 964-7.
- Shaked Y, Ciarrocchi A, Franco M, Lee CR, Man S, Cheung AM, Hicklin DJ, Chaplin D, Foster FS, Benezra R, Kerbel RS. Therapy-induced acute recruitment of circulating endothelial progenitor cell to tumors. *Science* 2006; 313(5794): 1785-7.
- Yu CC, Lo WL, Chen YW, Huang PI, Hsu HS, Tseng LM, Hung SC, Kao SY, Chang CJ, Chiou SH. Bmi-1 regulates snail expression and promotes metastasis ability in head and neck squamous cancer-derived ALDH1 positive cells. *J Oncol* 2011; 2011. pii: 609259.
- Ricci-Vitiani L, Lombardi DG, Pilozzi E, Biffoni M, Todaro M, Peschle C, De Maria R. Identification and expansion of human colon-cancer-initiating cells. *Nature* 2007; 445(7123): 111-5.
- Collins AT, Berry PA, Hyde C, Stower MJ, Maitland NJ. Prospective identification of tumorigenic prostate cancer stem cells. *Cancer Res* 2005; 65(23): 10946-51.
- Eramo A, Lotti F, Sette G, Pilozzi E, Biffoni M, Di Virgilio A, Conticello C, Ruco L, Peschle C, De Maria R. Identification and expansion of the tumorigenic lung cancer stem cell population. *Cell Death Differ* 2008; 15(3): 504-14.
- Ma S, Chan KW, Hu L, Lee TK, Wo JY, Ng IO, Zheng BJ, Guan XY. Identification and characterization of tumorigenic liver cancer stem/progenitor cells. *Gastroenterology* 2007; 132(7): 2542-56.
- O'Brien CA, Pollett A, Gallinger S, Dick JE. A human colon cancer cell capable of initiating tumour growth in immunodeficient mice. *Nature* 2007; 445(7123): 106-10.
- Singh SK, Hawkins C, Clarke ID, Squire JA, Bayani J, Hide T, Henkelman RM, Cusimano MD, Dirks PB. Identification of human brain tumour-initiating cells. *Nature* 2004; 432(7015): 396-401.
- Yin AH, Miraglia S, Zanjani ED, Almeida-Porada G, Ogawa M, Leary AG, Olweus J, Kearney J, Buck DW. AC133, a novel marker for human hematopoietic stem and progenitor cells. *Blood* 1997; 90(12): 5002-12.
- Harper LJ, Piper K, Common J, Fortune F, Mackenzie IC. Stem cell patterns in cell lines derived from head and neck squamous cell carcinoma. *J Oral Pathol Med* 2007; 36(10): 594-603.
- Ieta K, Tanaka F, Haraguchi N, Kita Y, Sakashita H, Mimori K, Matsumoto T, Inoue H, Kuwano H, Mori M. Biological and genetic characteristics of tumor-initiating cells in colon cancer. *Ann Surg Oncol* 2008; 15(2): 636-48.
- Bertolini G, Roz L, Perego P, Tortoreto M, Fontanella E, Gatti L, Pratesi G, Fabbri A, Andriani F, Tinelli S, Roz E, Caserini R, Lo Vullo S, Camerini T, Mariani L, Delia D, Calabrò E, Pastorino U, Sozzi G. Highly tumorigenic lung cancer CD133+ cells display stem-like features and are spared by cisplatin treatment. *Proc Natl Acad Sci* 2009; 106(38): 16281-6.

23. Lavanya N, Jayanthi P, Rao UK, Ranganathan K. Oral lichen planus: an update on pathogenesis and treatment. *J Oral Maxillofac Pathol* 2011; 15(2): 127–132.
24. Sun LI, Feng J, Ma L, Liu W, Zhou Z. CD133 expression in oral lichen planus correlated with the risk for progression to oral squamous cell carcinoma. *Ann Diagn Pathol* 2013; 17(6): 486-9.
25. Scully C, Felix DH. Oral medicine—update for dental practitioner: red and pigmented lesions. *Br Dent J* 2005; 199(10): 639-45.
26. Otero-Rey EM1, Suarez-Alen F, Peñamaria-Mallon M, Lopez-Lopez J, Blanco-Carrion A. Malignant transformation of oral lichen planus by a chronic inflammatory process. Use of topical corticosteroids to prevent this progression?. *Acta Odontol Scand* 2014; 22: 1-8.
27. Krishna Rao SV, Mejia G, Roberts-Thomson K, Logan R. Epidemiology of oral cancer in Asia in the past decade—an update (2000-2012). *Asian Pac J Cancer Prev* 2013; 14(10): 5567-77.
28. Li Z. CD133: a stem cell biomarker and beyond. *Exp Hematol Oncol* 2013; 2(1): 17.