

Case Report

Burning mouth syndrome caused by xerostomia secondary to amlodipine

Tengku Natasha Eleena binti Tengku Ahmad Noor

Dental Officer of 609 Armed Forces Dental Clinic, Kuching, Sarawak, Malaysia

ABSTRACT

Background: Xerostomia, generally referred to as dry mouth, has been identified as a side effect of more than 1,800 drugs from more than 80 groups. This condition is frequently unrecognised and untreated but may affect patients' quality of life and cause problems with oral and medical health, including burning mouth syndrome (BMS). **Purpose:** The purpose of this case is to discuss how to manage a patient with BMS caused by xerostomia secondary to medication that has been taken by the patient. **Case:** We reported that a 45-year-old male military officer from the Royal Malaysian Air Force came to Kuching Armed Forces Dental Clinic with dry mouth and a burning sensation since he started taking 10 mg of amlodipine due to his hypertension. After a thorough physical and history examination, we made a diagnosis of burning mouth syndrome (BMS) caused by xerostomia secondary to amlodipine. **Case Management:** Oral hygiene instructions, diet advice and prescription of Oral7 mouthwash has been given to reduce the symptoms of BMS. The patient has been referred to the general practitioner to reduce his amlodipine dosage from 10 mg to 5 mg (OD) in order to prevent xerostomia, and oral hygiene instructions have been given. A review after two weeks showed significant changes in the oral cavity, and the patient was satisfied as he is no longer feeling the burning sensation and can enjoy his food without feeling difficulty in chewing and swallowing. **Conclusion:** Adverse drug events are normal in the oral cavity and may have a number of clinical presentations such as xerostomia. Xerostomia can cause many implications as saliva helps in maintaining oral mucosa and has a protective function. The signs of adverse drug incidents in the oral cavity should be identified to oral health care professionals.

Keywords: amlodipine; burning; dry mouth; military officer; xerostomia

Correspondence: Lieutenant (Dr) Tengku Natasha Eleena binti Tengku Ahmad Noor, Malaysian Armed Forces Dental Officer, 609 Armed Forces Dental Clinic, Kem Semenggo, Kuching, Sarawak, Malaysia. Email: tengkumatashaeleena@gmail.com

INTRODUCTION

Burning mouth syndrome (BMS) is a benign disorder that presents as a burning sensation in the absence of any apparent findings in the mouth and in irregular blood tests. The underlying BMS aetiology remains unclear and is typically characterised by a feeling of burning, itching, or tingling, preferentially at the tip and sides of the tongue, lips, and anterior palate.¹ The manifestations of BMS are usually bilateral but in some cases may prove unilateral.² According to Cerchiari et al.,³ BMS can be classified according to the associated risk factors: idiopathic, psychogenic, local, and systemic. Psychopathological processes such as anxiety, depression, and certain phobias are among the psychogenic risk factors. In essence, local causes include infectious processes, allergic reactions, and irritative phenomena,

while the systemic aetiological factors include salivary secretion changes, endocrine disorders, neurological changes, dietary factors, and drug substance.²

It is estimated that more than 400 drugs affect the salivary gland function and contribute to hyposalivation.^{4,5} Drugs with anticholinergic activity, including antihypertensive drugs, can cause hyposalivation by reducing the acetylcholine released by the parasympathetic nerves.^{6,7} Amlodipine, which is an antihypertensive agent that acts as a calcium channel blocker, can cause xerostomia through the muscarinic M3 receptor, which results in reduced salivary flow.^{8,9} Diagnosis is based on the history and chronology of oral adverse reactions that are usually identified within weeks or months of the drug being administered.

Xerostomia is a concomitant symptom in patients with burning mouth syndrome, with prevalence varying between

34 and 39%.^{8,9} Saliva offers a protective function as well as an antimicrobial, buffering, and lubricating feature to help cleanse and eliminate food debris within the mouth. Patients will begin to develop oral problems before experiencing dryness, such as a burning mouth sensation, when the protective environment created by saliva is altered. The purpose of this case is to discuss how to manage a patient with BMS caused by xerostomia secondary to medication that has been taken by the patient.

CASE

A 45-year-old male military officer from the Royal Malaysian Air Force came to Kuching Armed Forces Dental Clinic with complaints of a burning sensation and dryness throughout his mouth for the past two months. The patient claimed that he feels hot and sharp and has been on a cold food diet as he cannot swallow any spicy or hot food.

A clinical examination was performed to rule out any pre-existing pathology other than dry mouth. The patient

is fit, conscious and has no other underlying medical diseases besides hypertension. The patient admitted feeling the changes in his mouth since taking anti-hypertensive medication, which was 10 mg of amlodipine per day given by the general practitioner in the last two months. Further inquiry into the patient's social history revealed no tobacco or alcohol use. The patient is happily married with three children, and after a deeper investigation, the patient claimed that he feels neither stress nor any psychological disturbances related to his daily life. However, he had not been able to eat well during the past two months due to the burning sensation he was having, and since then he had started to drink lots of cold water and apply lip balm on his cracked lips (Figure 1).

An intraoral examination demonstrated that both the buccal and palatal sides of the mouth were reddish, dry, and inflamed, while the tongue appeared scalded and burnt (Figure 2). The patient is not wearing any dentures and has relatively good oral hygiene, with no teeth restored.

Subsequently, the patient was referred to a medical for a full blood count (FBC) with differential analysis to check for any possible relationship with diabetes or Sjögren's Syndrome and deficiencies of iron, folate, zinc, and group B vitamins. The results came out that the patient was fit and well without any abnormality or deficiencies. Besides, the swab test showed the absence of candidiasis infection, although there is a severe decrease in unstimulated salivary flow rate (0.1 mL per minute) and stimulated salivary flow rate (0.5 mL per minute) according to the spit test that was done. The Challacombe scale of clinical oral dryness shows a score of 6, which indicates moderate dryness of the patient's mouth. Based on the overall clinical and laboratory findings, the differential diagnosis of this patient is BMS secondary to xerostomia due to amlodipine.

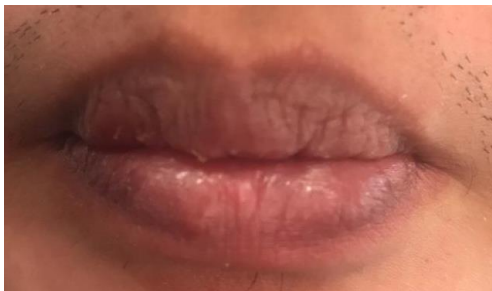

Figure 1. Photograph showing the patient's cracked and peeled lips.

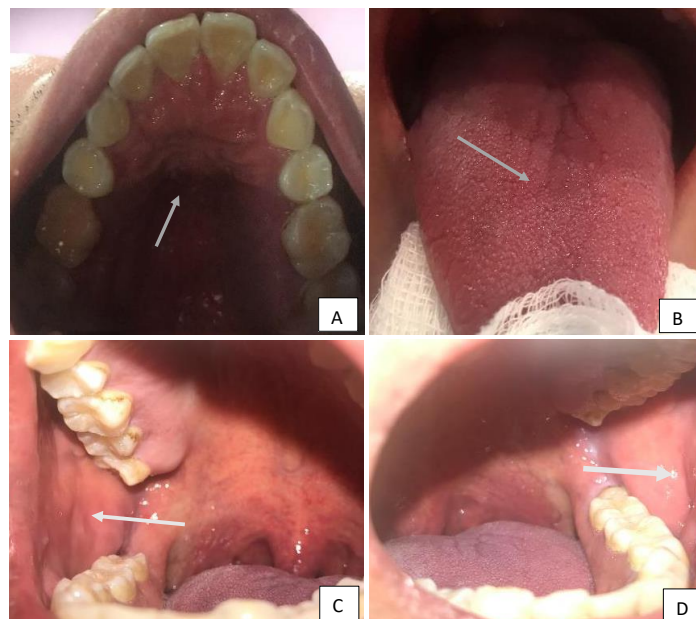


Figure 2. Pre-treatment photographs showing dry and inflamed palatal side (A), scalded tongue (B), and inflammation of both sides of the buccal region (C and D).

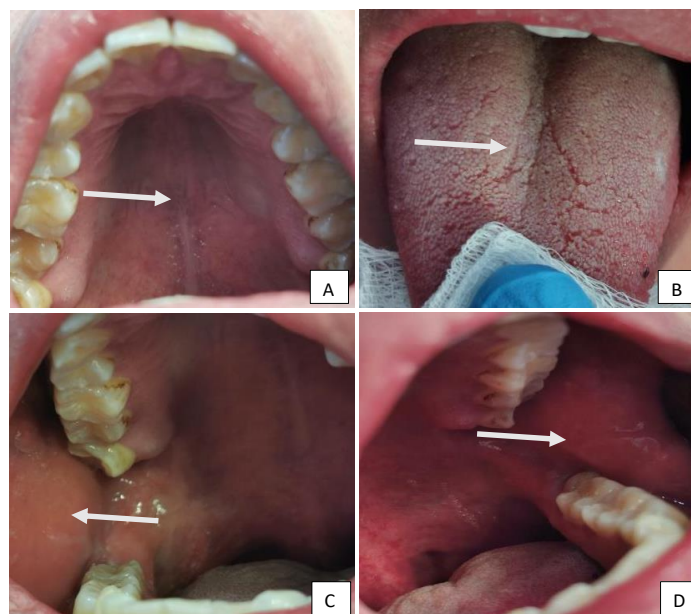


Figure 3. Two weeks later, follow-up treatment shows improved mucosa appearance, which is not dry or sticky (A, C, and D) and includes the non-scalded appearance of the tongue (B).

CASE MANAGEMENT

The patient was referred to the general practitioner for advice about lowering his dose of 10 mg of amlodipine or replacing it with other types of antihypertensive drug that can reduce xerostomia leading to burning mouth syndrome. Besides prescribing a hydrating mouthwash, oral hygiene advice has been given to the patient, including on how to relieve his burning and dry mouth symptoms, such as frequent sucking on ice cubes, increasing the intake of water and watery fruits, avoiding hot and spicy food, and chewing gum.

A follow-up appointment was given 14 days after the initial treatment. The patient claimed absence of burning sensation and dry mouth and said he can enjoy his food well without feeling difficulty in swallowing. Intraoral examination revealed an improved mucosa appearance without dry and sticky appearance or scalded appearance of the tongue (Figure 3). The dosage of 10 mg of amlodipine has been reduced to 5 mg, which has less effect in drying the mouth.

DISCUSSION

This clinical report described the BMS caused by xerostomia secondary to amlodipine. Initial management focused on eliminating the cause of xerostomia in order to treat the burning mouth syndrome. After establishing a diagnosis, a step-wise management approach should be implemented. This includes alleviating symptoms, the implementation of preventive measures, the treatment of oral diseases, the enhancement of salivary function, and the management of any underlying systemic condition.¹⁰

Initial treatments of this case include changing or lowering the dose of 10 mg of amlodipine by referring the patient to the general practitioner. The dry mouth side effects of medications may be alleviated or reduced by substituting the problem medications with similar drugs that have lesser side effects.¹⁰ In addition, alteration in the timing or dosing schedule of medication doses at night-time, when salivary flow is usually at its lowest, can maximise the dry mouth effects.

The diagnosis of burning mouth syndrome caused by dry mouth is based on clinical findings, with the characteristic of burning and itching sensation located bilaterally in the mouth, including the palate and tongue, with the absence of any oral mucosal pathology.¹¹ According to Millsop et al.,¹² patients with dry mouth have clinical manifestations of difficulty in swallowing, chewing, and/or speaking and present with burning mouth, halitosis, dry buccal mucosa, cracked and peeled lips, and oral candidiasis. This patient encountered burning mouth sensation together with dry mouth, difficulty in swallowing, and cracked lips, without any presence of other oral pathology, after taking an antihypertensive drug, and he was diagnosed with burning mouth syndrome caused by dry mouth secondary to amlodipine.

Persistent hyposalivation leading to dry mouth can lead to infections, such as candidiasis and dental caries, as well as bacterial sialadenitis.¹³ Lubrication loss can also result in erythema and mucosal susceptibility to frictional damage to the teeth, causing the patient to feel discomfort.¹⁴ The more commonly used agents for dry mouth can be categorised into chewing gums, salivary stimulants, and saliva substitutes.¹² Chewing gums or candies should be sugar-free to prevent dental caries. The patient has been prescribed with a hydrating mouthwash to minimise the dry

mouth effect as well as to stimulate the production of saliva, which helps to eliminate the burning sensation. Saliva substitutes that commonly contain carboxymethylcellulose, xanthan gum, mucins, hydroxyethylcellulose, polyethylene oxide, or linseed oil may help to increase salivary viscosity by resembling natural saliva.¹⁵

Very clearly, amlodipine can cause dry mouth, leading to burning mouth syndrome. Antihypertensive agents are the drugs most often associated with the appearance of symptoms compatible with burning mouth syndrome because they can act upon the angiotensin-renin system.² Salivary secretion depends on parasympathetic and sympathetic signalling, and parasympathetic activation leads to increased Ca^{2+} release and water fluxing out of the cell.¹⁶ Thus, taking a calcium channel blocker such as amlodipine, which acts as a Ca^{2+} antagonist, may cause dry mouth by inhibiting the voltage-dependent Ca^{2+} channels that are activated by depolarisation to cause resting salivation.¹⁶ Of the worldwide cases of medication-induced BMS, 33% were known to be dose-dependent phenomena, as the burning sensation only occurred when the medication dose was increased in pursuit of therapeutic efficacy.²

BMS can be managed easily with adequate diagnosis and treatment planning, or it can give discomfort to the patient psychologically; in the worst case scenario, other oral diseases might arise, such as dental caries and fungal infections. The first phase is an acute treatment to prevent the progression of burning mouth syndrome and to provide pain relief. The second phase is the amelioration of pre-existing conditions such as dry mouth, where symptoms would be improved after the initial acute phase. This included intense oral hygiene instruction and control of systemic factors such as smoking, diet, and stress. The alteration of medication that causes the burning mouth syndrome comes in the third phase and is considered only if it is confirmed to be the cause of BMS. The fourth and final treatment phase proceeds through supportive therapy to maintain oral hygiene and control of systemic and local factors.¹⁵

The patient discussed in this report went through the first and second phases of treatment, where we managed to treat the acute phase, and the patient was compliant with the treatment. For the third phase, of altering the patient's medication, the general practitioner has been consulted, and the patient is under review every three months as part of oral condition maintenance. In this case, as discussed in this report, a proper diagnosis was followed by improvement of the patient's condition.

Xerostomia or dry mouth is the result of reduced or absent salivary flow. It may occur as a result of ongoing drug use and happen concurrently with BMS. There are over 500 widely used medications, including various antidepressants, antipsychotics, antihistamines, diuretics, and sedatives, which list xerostomia as a side effect. Temporary relief options include oral mouthwashes, gels and sprays, lozenges, and change of dietary habit; however,

more prolonged treatment options will be medication such as pilocarpine or saliva substitutes with longer mucosal surface retention.

ACKNOWLEDGEMENT

The author would like to thank Lt Col (Dr) Sophia Ann Murray for her guidance in managing this case and the Dental Service of the Malaysian Armed Forces for this case write-up.

REFERENCES

- López-Jornet P, Camacho-Alonso F, Andujar-Mateos P, Sánchez-Siles M, Gómez-García F. Burning mouth syndrome: Update. *Med Oral Patol Oral Cir Bucal*. 2010; 15(4).
- Jääskeläinen SK, Woda A. Burning mouth syndrome. *Cephalalgia*. 2017; 37(7): 627–47.
- Cerchiari DP, De Moricz RD, Sanjar FA, Rapoport PB, Moretti G, Guerra MM. Burning mouth syndrome: Etiology. *Rev Bras Otorrinolaringol*. 2006; 72(3): 419–23.
- Thomson WM. Dry mouth and older people. *Aust Dent J*. 2015; 60(S1): 54–63.
- Turner MD. Hyposalivation and xerostomia. Etiology, complications, and medical management. *Dent Clin North Am*. 2016; 60(2): 435–43.
- Saleh J, Figueiredo MAZ, Cherubini K, Salum FG. Salivary hypofunction: An update on aetiology, diagnosis and therapeutics. *Arch Oral Biol*. 2015; 60(2): 242–55.
- Ristevska I, Armata RS, D'Ambrosio C, Furtado M, Anand L, Katzman MA. Xerostomia: Understanding the diagnosis and the treatment of dry mouth. *J Fam Med Dis Prev*. 2015; 1(2): 1–5.
- Mayer T, Haefeli WE, Seidling HM. Different methods, different results - How do available methods link a patient's anticholinergic load with adverse outcomes? *Eur J Clin Pharmacol*. 2015; 71(11): 1299–314.
- Nishtala PS, Salahudeen MS, Hilmer SN. Anticholinergics: theoretical and clinical overview. *Expert Opin Drug Saf*. 2016; 15(6): 753–68.
- Femiano F, Rullo R, di Spirito F, Lanza A, Festa VM, Cirillo N. A comparison of salivary substitutes versus a natural sialogogue (citric acid) in patients complaining of dry mouth as an adverse drug reaction: a clinical, randomized controlled study. *Oral Surgery, Oral Med Oral Pathol Oral Radiol Endodontology*. 2011; 112: e15–20.
- Tiisanoja A, Syrjälä AMH, Kullaa A, Ylöstalo P. Anticholinergic burden and dry mouth in middle-aged people. *JDR Clin Transl Res*. 2020; 5(1): 62–70.
- Millsop JW, Wang EA, Fazel N. Etiology, evaluation, and management of xerostomia. *Clin Dermatol*. 2017; 35(5): 468–76.
- Lavanya N, Jayanthi P, Rao U, Ranganathan K. Oral lichen planus: An update on pathogenesis and treatment. *J Oral Maxillofac Pathol*. 2011; 15(2): 127–32.
- Yuan A, Woo S Bin. Adverse drug events in the oral cavity. *Oral Surg Oral Med Oral Pathol Oral Radiol*. 2015; 119(1): 35–47.
- Vissink A, Mitchell JB, Baum BJ, Limesand KH, Jensen SB, Fox PC, Elting LS, Langendijk JA, Coppes RP, Reyland ME. Clinical management of salivary gland hypofunction and xerostomia in head-and-neck cancer patients: Successes and barriers. *Int J Radiat Oncol Biol Phys*. 2010; 78(4): 983–91.
- Mizuhashi F, Koide K, Taya S, Nashida T. Oral dryness caused by calcium blocker -Comparison with saliva of healthy elderly persons and patients with Sjögren's syndrome-. *Med Res Arch*. 2017; 5(9): 1–12.