

Original article

## Malocclusion with posterior unilateral crossbite affects superficial masseter and anterior temporal muscle activity during mastication

Yona Pricilia Anggi Siregar, Christnawati and Darmawan Soetantyo

Department of Orthodontics, Faculty of Dentistry, Universitas Gadjah Mada (UGM), Yogyakarta, Indonesia

### ABSTRACT

**Background:** Mastication patterns due to malocclusion with unilateral posterior crossbite may permanently change. **Purpose:** This study aimed to examine the effect of malocclusion with unilateral posterior crossbite of the superficial masseter and anterior temporal muscles on the crossbite and non-crossbite sides during mastication. **Methods:** Thirty subjects (8 males and 22 females) between the ages of 17 and 30 years who were students of the 2017–2019 Dentistry and Dental Hygiene Study Program, Faculty of Dentistry, UGM and who had at least two posterior teeth with unilateral posterior crossbite were divided into 10 subjects with Angle's class I, 10 subjects with class II and 10 subjects with class III malocclusions. The amplitude of the superficial masseter and temporal anterior muscles was performed during mastication using surface electromyography (sEMG). The mean difference between the groups of malocclusion on the crossbite and non-crossbite sides of the superficial masseter and temporal anterior was analysed by a two-way analysis of variance (ANOVA). **Results:** The results indicated a difference in amplitude mean between the malocclusion types on the crossbite sides and non-crossbite sides of the superficial masseter and temporal anterior muscles ( $p < 0.05$ ). This study confirmed there was a decrease in superficial masseter and anterior temporal muscle activity on the crossbite side rather than in the non-crossbite side in Angle's class I and class II. However, there was an increase in activity of the superficial masseter and anterior temporal muscles on the crossbite side for class III. **Conclusion:** Malocclusion with unilateral posterior crossbite affects masticatory activity of the superficial masseter and temporal anterior muscles on the crossbite side.

**Keywords:** malocclusion; masseter muscle; posterior crossbite unilateral; sEMG; temporal muscle

Correspondence: Christnawati, Department of Orthodontics, Faculty of Dentistry, Universitas Gadjah Mada. Jl. Denta Sekip Utara, Bulaksumur, Yogyakarta 55281, Indonesia. Email: christnawati\_fkg@ugm.ac.id

### INTRODUCTION

Dental and skeletal malocclusions can occur in a sagittal, vertical or transverse direction. In the sagittal direction they can occur in anterior crossbite, deep bite or open bite. Vertical and transverse directions can occur in scissor bite or posterior crossbite.<sup>1</sup> Occlusal interference due to malocclusion abrupt the effectiveness of mastication on each side of the jaw causing changes in masticatory patterns as individuals employ a more effective and comfortable side.<sup>2</sup>

Angle's classification divides dental malocclusions into three categories. Angle class I malocclusions are defined by the mesiobuccal cusp of the permanent maxillary first

molar coming into contact with the mesiobuccal groove of the permanent mandibular first molar. Angle class II malocclusions are specified when the mesiobuccal groove of the permanent mandibular first molar is distal when compared to the mesiobuccal cusp of the permanent maxillary first molar. Angle class III malocclusions are denoted by the mesiobuccal groove of the permanent mandibular first molar being more medially located than the mesiobuccal cusp of the permanent maxillary first molar.<sup>3</sup>

The presence of one or more posterior group teeth in an irregular bucco-lingual or bucco-palatal relationship with one or more opposing teeth in centric occlusion is defined as posterior crossbite. Posterior crossbite, especially unilateral

posterior crossbite, can cause mandibular shift, postural changes and has a possible link to temporomandibular joint (TMJ) disorders.<sup>4</sup>

The most common type of posterior crossbite is unilateral and bilateral posterior crossbite. Several factors causing posterior crossbite were found in this study such as tooth loss, maxillary contraction, persistence of deciduous teeth, occlusal disorders, hereditary factors, delayed eruption and premature loss.<sup>5</sup> In Brazil, 8–22 % of orthodontic patients and 5–15 % of the general population have posterior crossbite in the primary and early mixed dentition.<sup>6</sup>

Soft tissue is crucial in relation to orthodontic treatment because it has an effect on the dental arch shape that is the etiology of malocclusion, and this can affect the stability of the treatment. Facial muscles develop at birth and are the earliest muscles of the body to form to allow airways to be maintained. At the same time, tooth eruption, mastication, facial expressions, swallowing and speech are also developing.<sup>7</sup> Facial muscles are associated with relapse. In addition, unstable muscles from orthodontic treatment can lead to a relapse.<sup>8</sup>

Electromyography (EMG) is used to diagnose facial muscles during orthodontic treatment by using a neuromuscular approach. EMG can be recorded in two ways: surface and intramuscular. Surface electromyography (sEMG) is typically used to assess muscle function by recording activity from the skin's surface over the muscle using a pair of electrodes. Surface EMG allows for the noninvasive study of the bioelectrical phenomena of muscular contraction.<sup>9</sup> Kinematic patterns and muscle activity changes in the adjustment of the chewing load capacity can be observed through neuromuscular characteristics using sEMG.<sup>10</sup> Mastication is the most essential function of the stomatognathic system. Muscles, ligaments, bones and tooth structures are responsible for mastication function and control of the central nervous system. When the muscle is activated, electric signals are generated by ions crossing the muscle cell membrane and this is recorded and presented for EMG analysis. The masseter muscle is a thick and intensely strong muscle mass. It is rectangular-shaped originating from the temporal bone and extending to the angle of the mandible.<sup>11</sup> The masseter muscle serves as an elevator of the mandible in the protrusive movement and stabilises the condyle of the articular eminence. The temporal muscle is a large, fan-shaped muscle that fills the temporal fossa. The temporal muscle functions as an elevator of the mandible.<sup>12</sup>

Muscle examination and evaluation at the orthodontic clinic, such as accurate muscle activity measurements using sEMG, has not been widely developed as a diagnostic procedure. The purpose of this research is to examine the effect of malocclusion with unilateral posterior crossbite of the superficial masseter and anterior temporal muscles on the crossbite and non-crossbite sides during mastication.

## MATERIALS AND METHODS

This is an analytical cross-sectional research study. The subjects in this study were dentistry and dental hygiene students from the Faculty of Dentistry at UGM, who met the following inclusion criteria: the correct type of dental malocclusion, including class I, II and III and unilateral posterior crossbite involving at least two posterior teeth in centric relation and centric occlusion (maximum intercuspation); had no mandibular shift when opening and closing the mouth; complete number of teeth except for the third molars; no accidental trauma to the face and jaw; no clicking, crepitus or pain in the TMJ when opening and closing the mouth; did not use dentures and/or occlusal splints; had never had orthodontic or orthognathic treatment before and who had no history of systemic disease manifestations in the oral cavity. In this study, 30 subjects were selected from the selection consisting of 55 research subjects with unilateral posterior crossbite who did match the inclusion requirements. Research was then carried out using a purposive sampling technique, namely the selection inclusion criteria of the 30 suitable subjects were adjusted to comprise of 10 subjects with Angle's class I malocclusion, 10 subjects with Angle's class II malocclusion and 10 subjects with Angle's class III malocclusion. The 30 participants were separated into two groups: crossbite with class I, class II and class III malocclusions, and non-crossbite with class I, class II and class III malocclusions.

This research has been approved by the ethical commission of UGM number 00682/KKEP/FGK-UGM/EC/2021. The research subject selection has been qualified by the Faculty of Dentistry, UGM Ethics Committee. Eligible subjects received an explanation of the research procedure after filling out a written informed consent form.

Subjects who met the inclusion criteria signed the written informed consent form and after having their history of malocclusion assessed were scheduled to visit the electromedical outpatient unit at Dr. Sardjito General Hospital, Yogyakarta. Each research subject spent 20 minutes at the electromedical unit. The subject's details were registered in the EMG device system and electrodes were attached. This study employed sEMG using three electrodes. The electrodes were attached to the masseter and/or temporal muscles, nose (reference) and forehead (ground) using lubricants and adhesive tape above the skin that had been cleaned with a special scrub. EMG electrodes have no side effects or risks and since it is not an invasive method it was considered safe to implement it in this study. The initial stage of the study did not record muscle activity. Subjects were directed to chew four peanuts on each side of their mouth one by one following a sequence of muscle measurements. Measurements were performed respectively through EMG recordings on the crossbite side of the superficial masseter (MC), the anterior temporal of the crossbite side (TC), the non-crossbite side

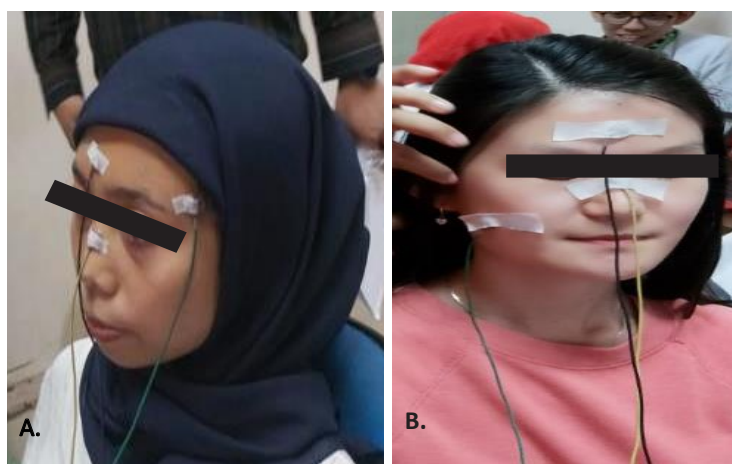of the superficial masseter (MN) and the non-crossbite side of the anterior temporal (TN) (Figure 1). The study course was initiated by delivering instructions to the participants for relaxation of the mind, facial muscles and lips. Participants were required to sit upright on a chair. The measurement of muscle activity started with the right-side of the superficial masseter muscle. Subjects were required to rest for two minutes before being instructed to chew nuts for 20 seconds during measurements. This treatment was repeated by measuring activity of the left superficial masseter muscle, right side anterior temporal muscle and left side temporal muscle. Electrodes were removed after all the measurements had been completed.<sup>13</sup>

An interpretation of the results was conducted by an electromyographer by synchronising the measurement area based on observation time intervals of 0–5 seconds, 5–10 s, 10–15 s and 15–20 s and discovering the highest amplitude during that time interval. The classification of these time intervals is a result of the motor unit potential (MUP), which records muscle action potentials, having only four assessment windows on the device monitor. The observation area is measured not only for the highest amplitude in each interval but also at one screen per interval.<sup>14</sup>

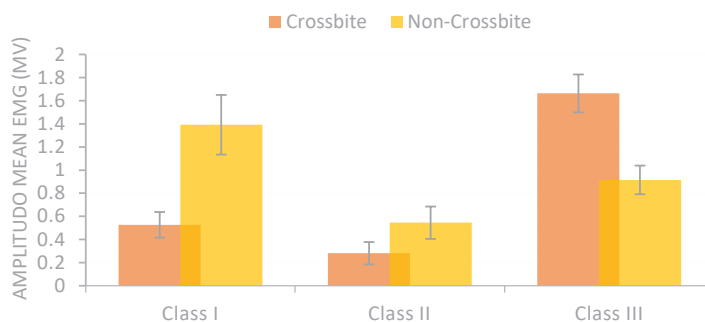
All statistical analysis data obtained were examined by averages using the Statistical Package for the Social Sciences (SPSS) 24.0 version (IBM Corporation, Illinois, Chicago, US). A two-way analysis of variance (ANOVA) ( $p < 0.05$ ) was carried out to examine the significant difference between the groups.

## RESULTS

Angle's class I and II malocclusions had lower crossbite side superficial masseter muscle activity than the non-crossbite side. In contrast, class III malocclusion had higher crossbite side superficial masseter muscle activity than the non-crossbite side. In class I and II malocclusions, anterior temporal muscle activity was lower on the crossbite side than on the non-crossbite side. Conversely, anterior temporal muscle activity was higher on the crossbite side than on the non-crossbite side in the class III malocclusion. The masticatory activity of class I malocclusion in the superficial masseter muscle average activity is displayed in Figure 2. The mean anterior temporal muscle activity presented lower amplitude on the crossbite side than the non-crossbite side in class I and class II malocclusions (Figure 3).



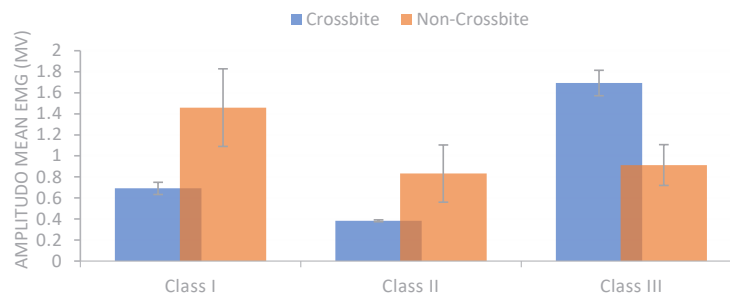
**Figure 1.** (A) Electrode and subject position during temporal muscle examination; (B) Electrode and subject position during masseter muscle examination.



**Figure 2.** Mean and standard deviation of superficial masseter muscle activity in Angle's class I, II and III with posterior unilateral crossbite.

The results of the two-way ANOVA test (Tables 1 and 2) indicated significant differences in the activity of anterior superficial and temporal masseter in the crossbite groups and between the malocclusions, and in the interaction of the crossbite and malocclusion groups ( $p < 0.05$ ). The post hoc least significant difference (LSD) test results between the groups (Tables 3 and 4) revealed significant variations in the activity of the anterior superficial and temporal masseter muscles between class I, II and III malocclusions in the crossbite side and the non-crossbite side ( $p > 0.05$ ).

In class I malocclusion groups on the crossbite side and class II on the non-crossbite side, the activation of the superficial masseter muscle was not substantially different across the groups ( $p > 0.05$ ). The anterior temporalis muscle activity was not significantly different between class I malocclusion groups on the crossbite side and class II groups on the non-crossbite side ( $p > 0.05$ ), nor between the groups in class II malocclusions on the non-crossbite side and class III malocclusions on the non-crossbite side ( $p > 0.05$ ).



**Figure 3.** Mean and standard deviation of temporal muscle activity in Angle’s class I, II and III malocclusions with posterior unilateral crossbite.

**Table 1.** Two-way ANOVA test of superficial masseter muscle activity in Angle’s class I, II and III malocclusions with posterior unilateral crossbite

Variables	p-value
Crossbite Side (Masseter)	0.003*
Malocclusion	$\leq 0.001^*$
Crossbite Side* Malocclusion	$\leq 0.001^*$

Notes: \* significant at  $p < 0.05$

**Table 2.** Two-way ANOVA test of temporal masseter muscle activity in Angle’s class I, II and III malocclusions with posterior unilateral crossbite

Variables	p-value
Crossbite Side (Masseter)	0.011*
Malocclusion	$\leq 0.001^*$
Crossbite Side* Malocclusion	$\leq 0.001^*$

Notes: \* significant at  $p < 0.05$

**Table 3.** Post hoc LSD test of superficial masseter muscle activity in Angle’s class I, II and III malocclusions with posterior unilateral crossbite

Group	Class1N	Class2N	Class3N	Class1X	Class2X	Class3X
Class1N						
Class2N	$< 0.001^*$					
Class3N	$< 0.001^*$	$< 0.001^*$				
Class1X	$< 0.001^*$	0.797	$< 0.001^*$			
Class2X	$< 0.001^*$	$< 0.001^*$	$< 0.001^*$	$< 0.001^*$		
Class3X	$< 0.001^*$	$< 0.001^*$	$< 0.001^*$	$< 0.001^*$	$< 0.001^*$	

Notes: \* significant differences  $p < 0.05$ ; Class1X: class I malocclusions crossbite side; Class2X: class II malocclusions crossbite side; Class3X: class III malocclusions crossbite side; Class1N: class I malocclusions non-crossbite side; Class2N: class II malocclusions non-crossbite side; Class3N: class III malocclusions non-crossbite side

**Table 4.** Post hoc LSD test of temporal masseter muscle activity in Angle’s class I, II and III malocclusions with posterior unilateral crossbite

Group	Class1N	Class2N	Class3N	Class1X	Class2X	Class3X
Class1N						
Class2N	$< 0.001^*$					
Class3N	$< 0.001^*$	0.406				
Class1X	$< 0.001^*$	0.148	0.025*			
Class2X	$< 0.001^*$	$< 0.001^*$	$< 0.001^*$	0.002*		
Class3X	0.018*	$< 0.001^*$	$< 0.001^*$	$< 0.001^*$	$< 0.001^*$	

Notes: \* significant differences  $p < 0.05$ ; Class1X: class I malocclusions crossbite side; Class2X: class II malocclusions crossbite side; Class3X: class III malocclusions crossbite side; Class1N: class I malocclusions non-crossbite side; Class2N: class II malocclusions non-crossbite side; Class3N: class III malocclusions non-crossbite side

## DISCUSSION

The results reported low activity of the superficial masseter muscle on the crossbite side during mastication in class I malocclusions throughout sEMG recordings. The masticatory activity of class I malocclusion in the superficial masseter muscle revealed that the mean crossbite side had less activity than the non-crossbite side. The low activity of the superficial masseter muscle on the side of the crossbite during mastication was influenced by the surface chewing area, the duration, and the strength of each individual.<sup>13</sup> The EMG results of class I malocclusion subjects measured on the crossbite side of the superficial masseter muscle during mastication reported a wide and short amplitude. The recorded amplitude value was lower than the maximum value limit (2mV calibration). The normal amplitude of the manual MUP EMG is 100  $\mu$ V–2 mV. At the non-crossbite side, the surface EMG results presented narrower peak amplitude. The shape and height of the different amplitudes between the crossbite and non-crossbite sides were influenced by muscle contraction due to masticatory movements.<sup>14</sup> Increasing amplitude on the non-crossbite side was caused by maximal muscle contractions that simultaneously occurred in the absence of occlusal disturbances. Meanwhile, the minimal chewing area of the affected teeth, influenced by the decrease in crossbite muscle activity and the size and thickness of the masticatory muscles, were examined.<sup>2</sup>

Occlusal disturbances decrease masticatory strength on the side of the crossbite and affect the activity of the superficial masseter muscle during a contraction. The presence of occlusal disturbances results in a smaller surface chewing area, thereby reducing the duration and strength of mastication.<sup>10</sup> The action potential that occurs during mastication contractions is influenced by the surface chewing area, the duration of mastication and the texture of the food.<sup>15</sup> The section of chewing area is represented by molars and premolars that have crossbite, and by the position of molars that do not occlude normally. The electromyogram on the monitor displayed frequencies with high and low amplitudes on the crossbite, while on the non-crossbite side there were several amplitude peaks that increased with an attenuated shape as they approached the calibration limit.<sup>14</sup>

The class II malocclusion had a molar disocclusion relationship that slowed down muscle contraction while the acceleration of muscle contraction during mastication of hard food was influenced by linear works of duration and the surface chewing area.<sup>15</sup> These results indicated that the non-crossbite side had greater occlusal stability, thereby causing pressure sustained by the muscles during mastication to be greater than the crossbite of the class II malocclusion. The results of this research are supported by Sandhu et al.<sup>13</sup> who studied the class II masseter and anterior temporal muscles of patients in a relaxed state with no movement to support the mandible. This was in contrast to the class III malocclusion study. Patients with

class II malocclusions associated with a high lip line and no stiffness factor in the perioral muscles resulted in decreased masticatory muscle activity.<sup>16</sup>

The study demonstrated an increasing superficial masseter muscle activity on the crossbite side during mastication in class III malocclusions through sEMG recordings. The masticatory activity in class III malocclusions of the superficial masseter muscle suggested that the average crossbite side was more active than the non-crossbite side. Class III malocclusion with unilateral posterior crossbite had an influence on the activity of the superficial masseter muscle during mastication, including greater activity on the crossbite side compared to the non-crossbite side. Class III malocclusions were determined by mandibular length, mesiocclusion molar relation and muscle hyperactivity to prevent forward mandibular movement.<sup>13</sup>

The study's findings indicated a decrease in anterior temporal muscle activity on the crossbite side in class I and class II malocclusions during mastication compared to the non-crossbite side. In class I and class II malocclusions, the mean anterior temporal muscle activity had a smaller amplitude on the crossbite side compared to the non-crossbite side. Activity in the anterior temporal muscle on the side of the crossbite during mastication differed significantly between class I and class II malocclusions. This finding revealed that the effect of class I malocclusions with unilateral posterior crossbite on anterior temporal muscle activity during mastication caused decreased activity in the anterior temporal muscle on the crossbite side compared to the non-crossbite side. Similarly, activity in the class II malocclusion anterior temporal muscle on the crossbite side decreased compared to the non-crossbite side.<sup>14</sup> There was a decrease in anterior temporal muscle activity caused by occlusal disturbances that occurred due to posterior crossbite with class I and class II malocclusions. This was due to a decreased acceleration of the anterior temporal muscle contraction during jaw closure that affected the amplitude frequency and was in contrast with the non-crossbite side.<sup>10</sup>

A study on the type of class III malocclusions indicated increased muscle activity during mastication in the anterior temporal part of the crossbite compared to the non-crossbite. The mean anterior temporal muscle activity in class III malocclusions presented a higher amplitude on the crossbite side than the non-crossbite side. There was a significant difference between the activity of the anterior temporal muscle on the side of the crossbite during mastication in class III. This finding suggested that class III malocclusions with unilateral posterior crossbite affects the activity of the anterior temporalis muscle during mastication. This includes increased anterior temporal muscle activity during mastication in class III with unilateral posterior crossbite, which has a higher activity on the crossbite compared to the non-crossbite side. An increase in anterior temporal muscle activity was due to the class III malocclusions displaying higher activity compared to class I and class II. In class III cases, the superficial and anterior temporal masseter

muscles are hyperactive to resist the forward movement of the mandible.<sup>13</sup>

Mastication of food in the premolar area is less efficient compared to the molar area due to its narrow surface. The efficiency of mastication is not only determined by strength and pattern but also by the occlusal conditions that receive the chewing load. In addition, the size and morphology of teeth in each individual is different which can affect the chewing area during the mastication process.<sup>15</sup> The number of unilateral posterior crossbite samples with unequal sex distribution may affect the study result. The imbalance of sex distribution can affect the masticatory strength during mastication on both the crossbite and non-crossbite sides.<sup>3</sup>

There were significant differences in superficial masseter muscle activity in all types of malocclusions on the crossbite and non-crossbite sides, meanwhile the activity of the superficial masseter muscle was not significantly different between groups in class I malocclusion on the crossbite side and class II malocclusion on the non-crossbite side. These results indicated that the non-crossbite side class II malocclusion had the same muscle activity as the crossbite side class I malocclusion but with lower than normal activity on the non-crossbite side of the class I malocclusion. The influencing factor of these results was the distocclusion of the molar relationship and the high lip line, which caused perioral muscle weakness in the class II malocclusion on the non-crossbite side.<sup>16</sup>

The activity of the anterior temporal muscles was significantly different in all types of malocclusions on the crossbite and non-crossbite sides. Exceptions included the activity of the anterior temporal muscle between the class I malocclusion on the crossbite side and class II malocclusion on the non-crossbite side, and the class II malocclusion on the non-crossbite side with the class III malocclusion on the non-crossbite side. These results confirmed that both the cross-bite side in class I malocclusions and class II malocclusions on the non-crossbite side had the same influencing factors as the masseter muscle. Class II malocclusions in the non-crossbite side along with class III malocclusions at the non-crossbite side had the same muscle activity caused by occlusal disturbances that interfered with the outcome of muscle activity.<sup>2</sup>

In this study, significant differences between crossbite and non-crossbite sides during mastication in class I, II and III malocclusion types have highlighted how important utilising an sEMG is. To evaluate the asymmetry activity of the superficial masseter muscle and anterior temporal muscle during mastication with types of malocclusions among cases of unilateral posterior crossbite during mastication, an sEMG is necessary to assist the diagnosis process and to promote successful orthodontic treatment. Evaluation of muscle activity disharmony since the beginning of orthodontic treatment using sEMG provides accurate data in the management of orthodontic treatment combined with effective masticatory muscle therapy.<sup>17</sup> The limitation of this study used a cross-sectional approach

with the aim of obtaining a relationship between exposure (type of malocclusion with unilateral posterior crossbite) and risk factors (activity of the superficial and anterior temporal masseter muscles during mastication). This type of research is analytical; therefore, confounding factors, such as skeletal factors, mastication, muscle shape and anatomy, morphology and teeth size, and bad habits during mastication, are not controlled.

Class I malocclusions with unilateral posterior crossbite displayed reduced activity on the side of the crossbite on the superficial masseter muscle and anterior temporal muscle during mastication. The superficial masseter muscle and the anterior temporal muscle on the side of the crossbite were less active in class II malocclusions with unilateral posterior crossbite. Class III malocclusions with unilateral posterior crossbite had a higher activity of superficial masseter muscle and anterior temporal muscle on the crossbite side during mastication. Furthermore, there was interaction between class I, II and III malocclusions with unilateral posterior crossbite toward the activity of the superficial masseter muscle and the anterior temporal muscle during mastication. Further research on malocclusion with unilateral posterior crossbite by controlling masticatory factors, morphology and size of the teeth, area of mastication, sex distribution, bad habits and involvement of skeletal factors on muscle activity both at rest, biting food and during mastication, is needed.

## REFERENCES

1. Premkumar S. Textbook of orthodontics. New Delhi: Elsevier; 2015. p. 89, 102–9.
2. Zamanlu M, Khamnei S, Salarilak S, Oskoe SS, Shakouri SK, Houshyar Y, Salekzamani Y. Chewing side preference in first and all mastication cycles for hard and soft morsels. *Int J Clin Exp Med*. 2012; 5(4): 326–31.
3. Nishi SE, Basri R, Alam MK, Komatsu S, Komori A, Sugita Y, Maeda H. Evaluation of masticatory muscles function in different malocclusion cases using surface electromyography. *J Hard Tissue Biol*. 2017; 26(1): 23–8.
4. Iodice G, Danzi G, Cimino R, Paduano S, Michelotti A. Association between posterior crossbite, skeletal, and muscle asymmetry: a systematic review. *Eur J Orthod*. 2016; 38(6): 638–51.
5. Sultana N, Hassan GS, Jha D, Nashrin T, Nahar L, Naim MA. Prevalence of cross bite among the orthodontic patients in Bangabandhu Sheikh Mujib Medical University. *Bangladesh J Med*. 2015; 26(1): 9–12.
6. de Sousa RV, Ribeiro GLA, Firmino RT, Martins CC, Granville-Garcia AF, Paiva SM. Prevalence and associated factors for the development of anterior open bite and posterior crossbite in the primary dentition. *Braz Dent J*. 2014; 25(4): 336–42.
7. Mitchell L. An introduction to orthodontics. 4th ed. Oxford: Oxford University Press; 2013. p. 11, 34–5, 44.
8. Alam MK. A to Z orthodontics: Retention and relapse. Kota Bharu: PPSP Publication; 2012. p. 14.
9. Nishi SE, Basri R, Alam MK. Uses of electromyography in dentistry: An overview with meta-analysis. *Eur J Dent*. 2016; 10(3): 419–25.
10. Woźniak K, Piątkowska D, Lipski M, Mehr K. Surface electromyography in orthodontics - a literature review. *Med Sci Monit*. 2013; 19: 416–23.
11. Fox SI. Human physiology. 14th ed. New York: McGraw-Hill Education; 2015. p. 360–76.

12. Okeson JP. Management of temporomandibular disorders and occlusion. 7th ed. St. Louis: Elsevier Mosby; 2012. p. 234–7.
13. Sandhu SS, Utreja A, Prabhakar S, Sandhu N, Kashyap R. A study of electromyographic activity of masseter and temporalis muscles and maximum bite force in patients with various malocclusions. Singh G, editor. *J Indian Orthod Soc.* 2013; 47(2): 53–61.
14. Merletti R, Farina D. Surface electromyography: physiology, engineering, and applications. Canada: Wiley-IEEE Press; 2016. p. 54–8; 89, 100–23.
15. Tomonari H, Seong C, Kwon S, Miyawaki S. Electromyographic activity of superficial masseter and anterior temporal muscles during unilateral mastication of artificial test foods with different textures in healthy subjects. *Clin Oral Investig.* 2019; 23(9): 3445–55.
16. Lapatki BG, Mager AS, Schulte-Moenting J, Jonas IE. The importance of the level of the lip line and resting lip pressure in Class II, Division 2 malocclusion. *J Dent Res.* 2002; 81(5): 323–8.
17. Michelotti A, Rongo R, Valentino R, D'Antò V, Bucci R, Danzi G, Cioffi I. Evaluation of masticatory muscle activity in patients with unilateral posterior crossbite before and after rapid maxillary expansion. *Eur J Orthod.* 2019; 41(1): 46–53.