

Management of a complete 180° rotation of bilateral maxillary canines

Putri Intan Sitasari¹, Niken Merrystia² and Ida Bagus Narmada²

¹Department of Orthodontics, Faculty of Dental Medicine, Universitas Mahasaraswati, Denpasar, Bali, Indonesia

²Department of Orthodontics, Faculty of Dental Medicine, Universitas Airlangga, Surabaya, Indonesia

ABSTRACT

Background: Dental anomalies usually lead to complicated decisions having to be made in terms of the orthodontic treatment of permanent dentition; tooth rotation is the most common of these irregularities. The prevalence rate of this phenomenon is 2.1–5.1% in patients who have not received orthodontic treatment. **Purpose:** This case report aimed to manage the complete bilateral rotation of maxillary canines with couple force by using a Nance appliance modification. **Case:** A 17-year-old male patient came in wanting to straighten his teeth. He complained about his bilateral canines, which were not in a normal position. There was an impacted left maxillary second premolar and an ectopically erupted right maxillary first premolar. He also had protrusions in the upper and lower anterior teeth and crowding in the lower anterior teeth as well as upper and lower midline deviations. **Case Management:** A clinical examination showed a class I relationship between the dental and cephalometry measurements and highlighted a class I skeletal pattern. The upper right first premolar was extracted and the left second premolar had undergone an odontectomy to allay protrusion and correct crowding. Bilaterally rotated upper canines were derotated using a modified Nance appliance and an elastomeric chain with couple force. **Conclusion:** The success of the orthodontic treatment was influenced by the specific nature of the patient's dental and medical history, extraoral and intraoral examination, diagnosis and treatment planning, which was followed by a systematic approach to treatment. The Nance appliance modification reduced the total treatment time by achieving controlled anchorage and derotation of the canines.

Keywords: canine rotation; couple force; derotation; Nance appliance

Correspondence: Ida Bagus Narmada, Department of Orthodontics, Faculty of Dental Medicine, Universitas Airlangga, Jl. Mayjen Prof. Dr. Moestopo 47, Surabaya 60132, Indonesia. Email: ida-b-n@fkg.unair.ac.id

INTRODUCTION

Dental anomalies usually mean complicated decisions with regard to the orthodontic treatment of permanent dentition have to be made.¹ The aetiology of these dental anomalies is caused by genetic and environmental factors,² and developmental versions of these irregularities are an essential part of dental morphologic variations. Abnormalities in the tooth shape, tooth number and tooth structure result from disruption during the developmental stage of morphological differentiation, while abnormalities in the tooth position stem from developmental disruption in the eruption pattern of the permanent teeth. Rotation, impaction and ectopic eruption are all related to irregularities in the tooth position.³

Tooth rotation is intra-alveolar displacement in the mesiolingual or distobuccal direction of the tooth around a longitudinal axis of at least 20°, and the prevalence of tooth rotation is 2.1–5.1% in patients who have not received orthodontic treatment.³ Rotation of permanent dentition can be caused by pre-eruptive and post-eruptive disturbances. Furthermore, several factors relate to pre-eruptive disturbance, such as displaced and misaligned development of tooth buds due to pre-maxillary region injury in childhood, and pathological conditions that can interfere with tooth eruption like a cyst, odontogenic tumour or mesiodens (supernumerary tooth). Elements that can cause post-eruptive disturbances are usually local/environmental, habitual or mechanical. Although the aetiology of dental malpositioning is multifactorial,

environmental reasons that must be considered as a cause of tooth rotation include the presence of space, the tooth eruption pathway and functional effects that are influenced by the tongue and lips. Rotations often occurs in relation to crowded teeth, but an excess number of rotations might also occur in instances that relate to the degree of space.⁴ Gupta et al.³ categorised rotation into three groups: $<45^\circ$, 45° to 90° and $>90^\circ$. In their research, the majority of tooth rotation was between 45° and 90° (58%), followed by $<45^\circ$ rotations (31%) and then $>90^\circ$ rotation (11%). Out of all of the instances of rotation, there were only two cases that presented with a complete 180° rotation (the buccal side is on the palatal side, and vice versa).⁴ It can therefore be interpreted that this case was rare.

In this study, the patient had a complete 180° rotation of the bilateral maxillary canine and other anomalous conditions, such as an impacted maxillary second premolar on the left side and an ectopically erupted maxillary first premolar on the right side. The routine treatment of rotated teeth is to use fixed orthodontic and modified Nance appliances; however, this case report aimed to manage the complete bilateral rotation of maxillary canines with couple force using a Nance appliance modification.

CASE

A 17-year-old man came to the Dental and Oral Hospital/ Rumah Sakit Gigi dan Mulut Pendidikan (RSGM-P) at

the Orthodontics Department, Faculty of Dental Medicine, Universitas Airlangga, wanting to straighten his teeth because his canines were not in a normal position. The patient said that the posterior upper left tooth was never replaced after the primary tooth was extracted. The general condition of the patient was good and he had never had orthodontic treatment before. Moreover, the patient wanted to be treated to improve the appearance of his smile, particularly with regard to the aesthetic of his teeth.

An extraoral examination showed that he had a straight face profile, a medium face type, a mesocephalic head shape, competent lips, normal speech function and no bad habits (Figure 1). Meanwhile, an intraoral examination revealed normal oral mucosa, tongue and palate, with a mild caries frequency and good oral hygiene. The maxillary arch was a normal shape, but the mandibular arch was not typically formed. There was a protrusion in the anterior upper and lower teeth, crowding among the lower anterior teeth, an ectopically erupted #14, a large space between #24 and #26, bilateral rotations in #13 and #23 and a midline deviation of one mm to the right in the upper and one mm to the left in the lower. Sagittally, the relation of the right canine was mesioclusional, the left canine was neutroclusional and the right and left molar were also neutroclusional. The overbite and overjet were found to measure one mm. At the same time, dental cast analysis indicated a discrepancy in the upper and lower arch of -8mm and the curve of Spee was one mm (Figure 2).

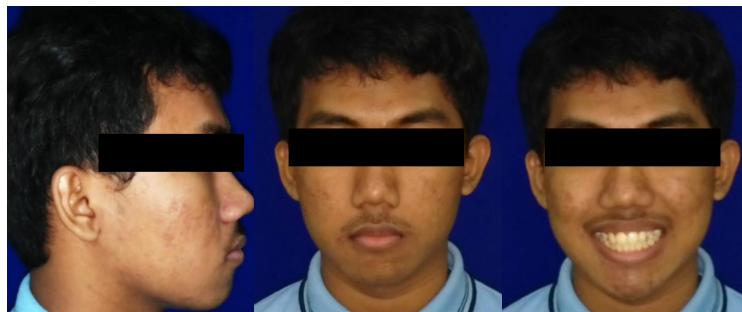

Figure 1. Patient's pre-treatment extraoral photographs.

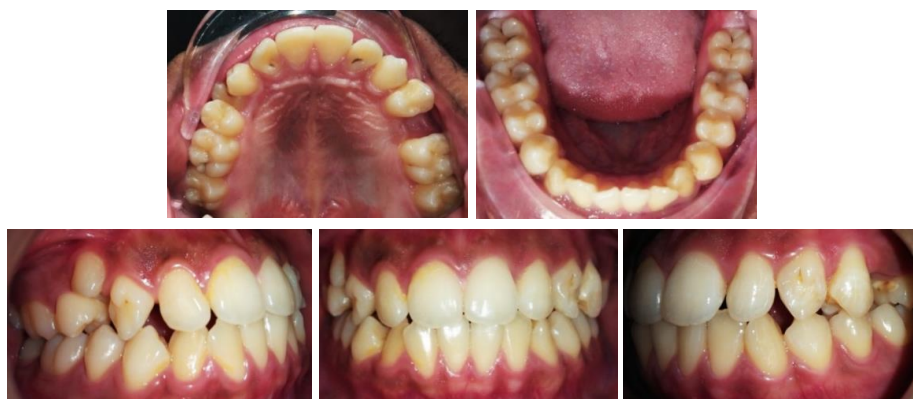

Figure 2. Patient's pre-treatment intraoral photographs.

No pathological conditions were detected on the panoramic radiograph, yet there were several impacted teeth at #18, #25, #28, #38 and #48 (Figure 3). Cephalometric analysis indicated the patient had a straight profile with \angle Nasion-Point A-Pogonion (NA-APog) 3° and \angle Frankfort Horizontal-Nasion-Pogonion (FH-NPog) 85° . The maxilla and mandible relation to the cranium base highlighted a skeletal class I relationship with \angle Sella-Nasion-Point A (SNA) 84° , \angle Sella-Nasion-Point B (SNB) 81° and \angle Point A-Nasion-Point B (ANB) 3° ; also, there was a Wits appraisal of two mm (Figure 4). The dental inclinations of the maxillary and mandibular incisors were protrusive, having the respective values of \angle Upper incisor-Nasion-Point A (I-NA) 27° , \angle Lower incisor-Nasion-Point B (I-NB) 32° , \angle Inter Incisal 125° , \angle Incisor Mandibular Plane Angle (IMPA) 98° and \angle Frankfort Mandibular Incisive Angle (FMIA) 57° . Meanwhile, use of Rickett's and Steiner's soft tissue and lip analyses showed that the lower lips were in front of the e-line and the s-line, which meant the patient had protrusive lower lips (Table 1).

CASE MANAGEMENT

The treatment objectives were to correct the maxillary bilateral rotation of the canines, deal with mandibular crowding, reduce upper and lower incisor protrusion and lower lip protrusion, correct midline deviation and maintain a class I relationship with regard to the canines and molars with an ideal arch form and attain a normal overjet and overbite. From the results of clinical examinations and diagnostic records, including a dental and orthodontic history, dental cast, intraoral and extraoral photographs and radiograph photos, the clinician planned to use fixed orthodontic appliances, which would be accompanied by the extraction of #14, #35 and #45 and an odontectomy on #25. There would also be a retention phase using removable retainers.

The first step of the treatment was the utilisation of bonding brackets using 0.022 slots of MBT, a pre-adjusted edgewise appliance, after the extraction of #14, #35 and #45, and an odontectomy was completed on #25. The molar bands

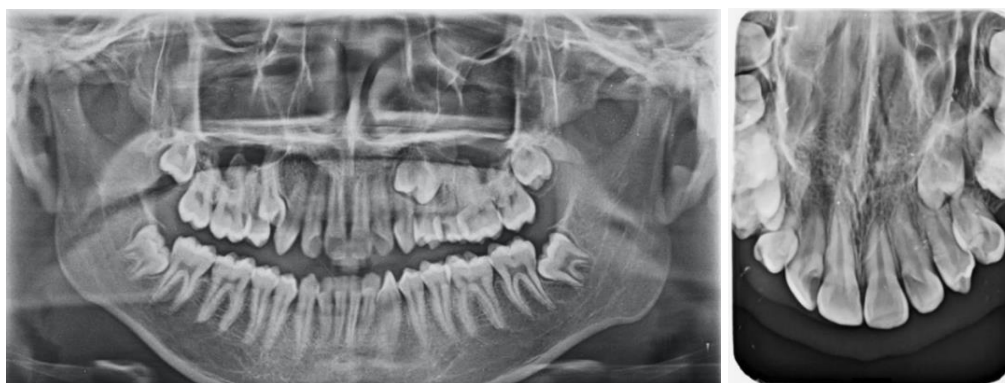

Figure 3. Patient's pre-treatment panoramic and occlusal radiography.

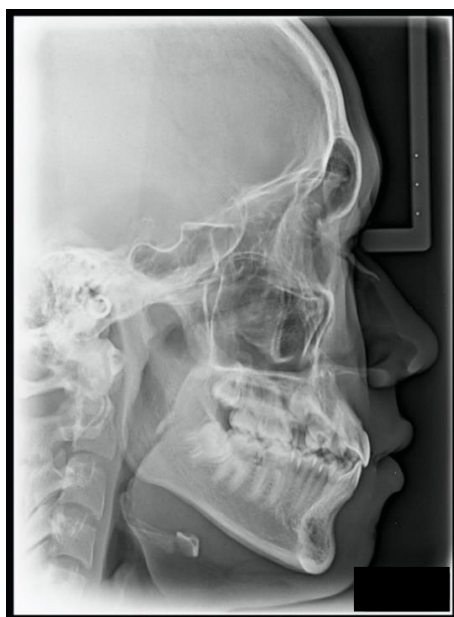

Figure 4. Patient's pre-treatment cephalogram.

Table 1. Pre and post-treatment cephalogram measurements

Measurement	Surabaya Mean	Subject	
		Pre	Post
\angle NA-Apog	84.5 °	85°	85°
\angle FH-Npog	6.1 °	3°	2°
\angle SNA	84.3°	84°	83°
\angle SNB	81.4°	81°	82°
\angle ANB	3°	3°	2°
\angle OP - SN	15–32°	18°	17°
\angle MP - SN	20–40°	32°	32°
\angle I-NA	26°	27°	20°
I-NA (mm)	6.3mm	10mm	5mm
\angle I-NB	29°	32°	25°
I-NB (mm)	7.9mm	8mm	5mm
Nasolabial angle	110–120°	92°	100°
Upper lips: e line	-2–3mm	+1mm	-1mm
Lower lips: e line	-1–2mm	+2 mm	0mm
Upper lips: s line	0mm	+2mm	+1mm
Lower lips: s line	0mm	+3mm	0mm

were cemented to the upper and lower first molar; those in the upper jaw have a slot for inserting the Nance appliance. Levelling and aligning begins with 0.012 nickel-titanium (NiTi), followed by 0.014, 0.016, 0.016 x 0.016 and 0.016 x 0.022 NiTi for the upper and lower arches. Retraction of #24, #34 and #44 was also undertaken using a 0.016 x 0.022 stainless steel (SS) wire with an omega stopper in the mesial of #26, #36 and #46 along with an elastomeric chain.

The next step was the derotation of #13 and #23. Apart from being a conventional anchorage system, the Nance appliance has been modified by adding a hook for the derotation of the canines. The hooks were soldered on the Nance appliance around the palatal area of the canines (Figure 5), and derotation took place using elastomeric chains with couple force as well as the joining together of the premolar and both molars using a ligature wire to reinforce the posterior anchorage. These anchor units would be used to hold the posterior teeth during derotation to prevent loss of anchorage. The derotation of the canine was done via the employment of elastic chains from the palatal surface, which were then attached to the hook on the molar band and from the buccal surface to the hook of the Nance

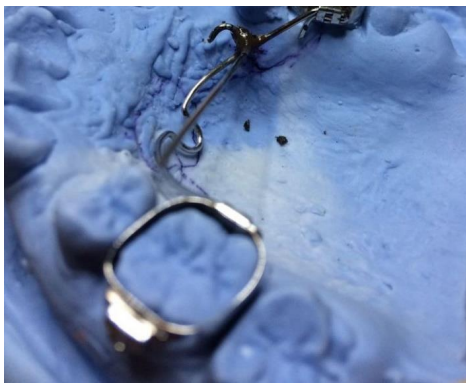


Figure 5. Nance appliance modification with hook around the palatal area of the canine.

appliance (using lingual buttons). The derotation had to be achieved on both the left and right sides (Figure 6).

The retraction of the anterior segment began with canine retraction, which first used 0.016 x 0.022 SS wire with an omega stopper in the mesial of #16, #26, #36 and #46; subsequently, a power chain was utilised. After the canine retraction was done, the upper and lower anterior retraction was started using a t-loop in 0.017 x 0.025 SS. Then, the mesialization of #16, #26, #36 and #46 took place using a power chain. After the overbite and overjet were corrected, a class I canine and molar relationship had been attained. Almost two years and two months later, all the fixed appliances were removed, and a wraparound retainer was chosen for both arches.

DISCUSSION

During the diagnosis of malocclusion, dental anomalies comprise 10% to 20% of cases in orthodontic patients and usually involve complicated decisions having to be made in terms of the orthodontic treatment of permanent dentition.¹ The orthodontist is perhaps the first individual who will detect dental anomalies and diagnose malocclusion in the patient. Furthermore, they will carry out an examination to detect any additional defects in these patients to provide the best treatment.²

Dental anomalies can relate to shape, number, structure and position.³ Irregularities in dental position occur when the tooth moves from its development area lead-up to the functional position,⁵ and such issues in relation to tooth position could be down to tooth rotation, impaction and ectopic eruption. In their study, Gupta et al.³ concluded that anomalies in the dental position were the most common occurrence among this group. Nevertheless, the aetiology of rotation in permanent dentition is multifactorial and can be caused by pre-eruptive and post-eruptive disruptions. In addition, several elements can cause further changes

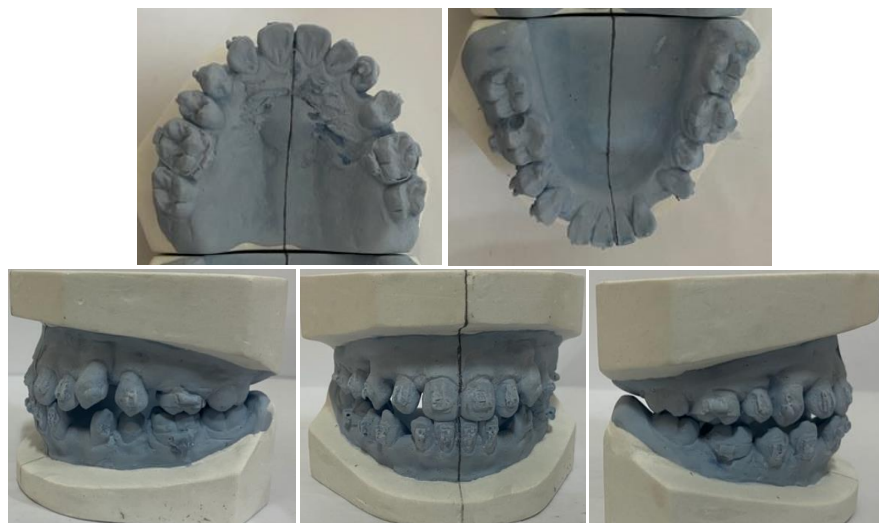


Figure 6. Patient's cast during treatment.

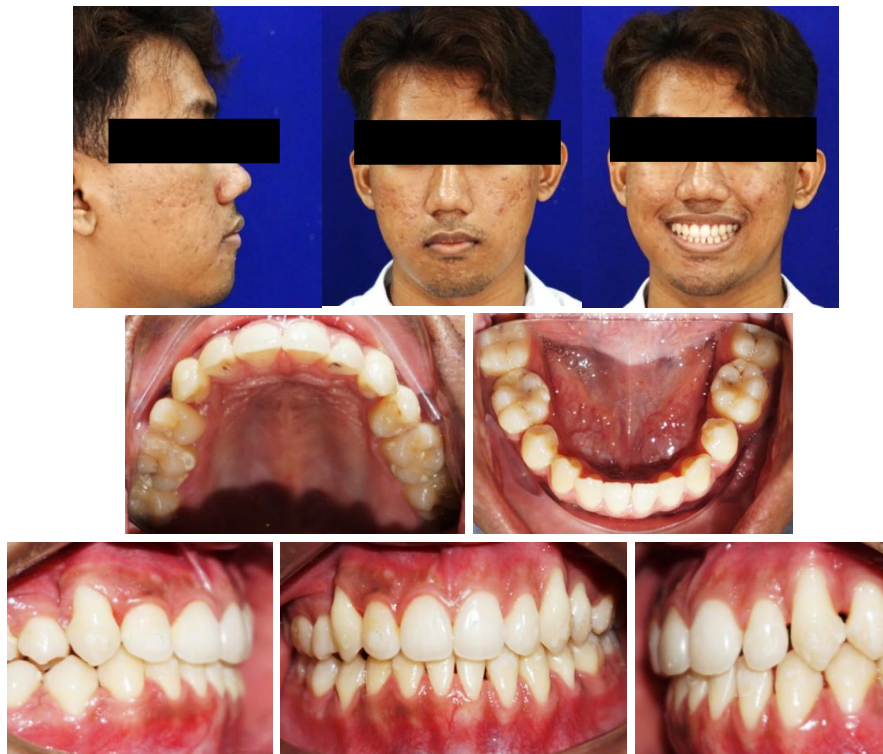

Figure 7. Patient's extraoral and intraoral photographs post treatment.

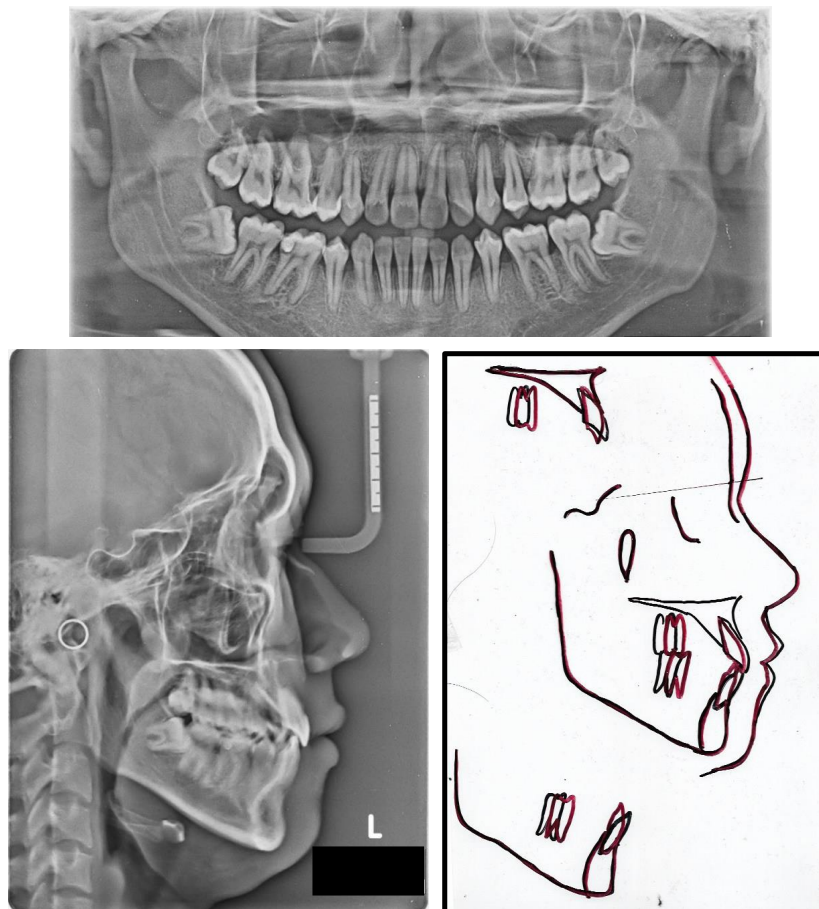


Figure 8. Patient's post-treatment panoramic cephalogram, which was superimposed pre and post-treatment.

in post-eruptive tooth angulation, such as trauma, extraction, hypodontia, ectopic eruption and periodontitis in neighbouring teeth. The prevalence of tooth rotation is quite high in the population, and orthodontists should be aware of indications of dental anomalies, so they can determine the appropriate treatment.⁶

Tooth rotation is an intra-alveolar displacement in a mesiolingual or distobuccal direction of the tooth around a longitudinal axis.⁴ Gupta et al.³ categorised the rotation into three groups: $<45^\circ$, 45° to 90° and $>90^\circ$. In this case, a patient with complete (180°) rotations of the bilateral maxillary canines was treated with a modified Nance appliance. The modification involved adding a hook around the palatal area of the canine, which served the purpose of simultaneously controlling the posterior anchorage and derotation of the severely rotated teeth. Since the derotation that needed to be achieved was bilateral, the hook was soldered on both the right and left side. In relation to this, the preferred method when derotating teeth is generally to use couple force on the adjacent teeth. Iatrogenic effects may occur if there was poor control of the adjacent teeth; thus, they may delay further treatment. Consequently, in some cases where proper anchoring was required, controlling the anchorage can help to avoid unwanted tooth movement.⁷ In this case, in addition to using a molar band that is connected to the Nance appliance, a clinician joined the premolar and both molars using a ligature wire to strengthen the posterior anchorage.

A couple is a form of moment that is created by two forces in oppositional directions, which moves on an axis with equal magnitudes. This force system has the net potential to translate the teeth on which the action is nil, meaning only pure rotation occurs; this is due to the forces having the same magnitude but oppositional directions. The sum of the moments created by the two forces is called a moment couple, and the magnitude of the force and the distance between the two forces can affect its magnitude. The moment created was additive if there were two forces acting on the couple system in oppositional directions from a centre of resistance (CRes), whereas the moment created was subtractive if two forces were on the same side as the CRes.⁸

In different types of malocclusions, extraction of certain teeth may be required. Oral hygiene, a high caries rate, tooth quality, attitude to treatment and the general health of the patient will influence the decision to have a tooth extracted. There are several conditions that cause teeth to be extracted during orthodontic treatment, such as crowding (increased tooth size associated with the arch size), hypodontia (need for extraction if set to close the space), supernumeraries, malformed teeth, caries teeth, open bite cases, increased overjet, tooth impaction, correction of the buccal segment, camouflage orthodontic treatment, periodontal disease involving the teeth, cleft lip and palate and orthognathic surgery.⁹ One of the main reasons for choosing extraction or non-extraction is an arch discrepancy.¹⁰ In this case, the patient had a significant discrepancy of eight mm in relation to the upper and lower arch. Meanwhile, in

instances of crowding teeth with a discrepancy of five to nine mm, arch expansion can be performed after carrying out a comprehensive diagnosis and treatment planning takes place. Permanent tooth extraction is frequently performed in most of these cases to maintain facial aesthetics and the integrity of the soft tissue profile.¹¹ Since this patient had several problems, extracting the four premolars was chosen as the most suitable treatment.

If there is moderate to severe crowding in the anterior segment, it is usually necessary to extract all of the first premolars to create space. However, in this case, a clinician decided to extract the upper first premolar on the right side and perform an odontectomy on the second premolar on the left side. The extraction and odontectomy were undertaken because of the poor prognosis of the premolar on each side, which would have prolonged the treatment period if the teeth were retained. The mandibular second premolars on the right and left side were the teeth selected for extraction, because their removal adjusted the upper jaw and would help correct the relation to a class I standard. There are two main retraction techniques to close extraction spaces: en masse retraction (ER) and two-step retraction (TSR). With regard to the former, the incisors and canines are retracted together in just one step; meanwhile, during the latter, the first step is to retract the canines until they are in contact with the premolar. The canines will then be joined to the premolar and first and second molars as posterior anchorage units. In the second step, these units are used to hold the posterior region while retracting the incisors.¹² In this case, we used the Nance appliance and two-step retraction to lower the risk of anchorage loss.

After the aforementioned orthodontic treatment, class I canine and molar relationships had been achieved in both sides (Figure 7). The inter-incisal angles were normalised after the midline deviation and inclination of the upper and lower anterior teeth were corrected; the soft tissue profile has also been corrected in the patient. The severe rotations of the canines and crowding were corrected; thus, one of the treatment goals was satisfied (Figure 8). In this instance, the clinician had suggested an odontectomy for the third molars, but the patient refused to go through this again because they had previously had an extraction and an odontectomy. The total amount of time taken to complete this orthodontic treatment was 26 months.

From this case, we can conclude that successful orthodontic treatment can be influenced by specific dental and medical histories, extraoral and intraoral examinations, diagnoses and treatment planning, which are followed by a systematic approach to being treated. The selection of an appropriate appliance and an assessment are needed for each case; for example, a bracket prescription and the type of wire as well as techniques for levelling-aligning, derotation, space closure and anchorage all need to be chosen, and they must be prepared to obtain optimal orthodontic treatment results. Here, the Nance appliance modification helped to reduce the total treatment time by achieving controlled anchorage and derotation of the canines.

ACKNOWLEDGEMENTS

Our gratitude goes primarily to the patient and to RSGM-P, Faculty of Dental Medicine, Universitas Airlangga for their willingness to present us with photos of the patient and their treatment.

REFERENCES

1. Massaro C, Janson G, Yatabe M, Calil LR, Oliveira TM, Gariba D. Dental anomaly pattern and multiple ectopic teeth. *Am J Orthod Dentofacial Orthop.* 2020; 158(1): 102-13.
2. Cakan DG, Ulkur F, Taner T. The genetic basis of dental anomalies and its relation to orthodontics. *Eur J Dent.* 2013; 7(1): 143-7.
3. Gupta SK, Saxena P, Jain S, Jain D. Prevalence and distribution of selected developmental dental anomalies in an indian population. *J Oral Sci.* 2011; 53(2): 231-8.
4. Parisay I, Boskabady M, Abdollahi M, Sufiani M. Treatment of severe rotations of maxillary central incisors with whip appliance: Report of three cases. *Dent Res J.* 2014; 11(1): 133-9.
5. Kaur P. Hypodontia, microdontia and tooth rotation: A rare clinical triad. *International Journal of Dental Research.* 2016; 4(2): 57-61.
6. Vani NV, Saleh SM, Tubaigy FM, Idris AM. Prevalence of developmental dental anomalies among adult population of Jazan, Saudi Arabia. 2016; 7: 29-33.
7. Hasan SH, Kolemen A, Elkolaly M, Marya A, Gujjar S, Venugopal A. TAD's for the derotation of 90° rotated maxillary bicuspids. *Hindawi Case Reports in Dentistry.* 2021; 1-8.
8. Upadhyay M, Nanda R. Biomechanics principles in mini-implant driven orthodontics. Greece: Vasiliadis books; 2020. p 1-20.
9. Al-Ani MH, Mageet AO. Extraction planning in orthodontics. *J Contemp Dent Pract.* 2018; 19(5): 619-23.
10. Khanum A, Prashantha GS, Mathew S, Naidu M, Kumar A. Extraction vs non extraction controversy: A review. *J Dent Orofac Res.* 2018; 14(1): 41-8.
11. Sharma NS, Shrivastav SS, Hazarey PV. Mastering Interproximal Stripping: With Innovations in Slenderization. *Int J Clin Pediatr Dent.* 2012; 5(2): 163-6.
12. Schneider PP, Gandini-Júnior LG, Monini ADC, Pinto ADS, Kim KB. Comparison of anterior retraction and anchorage control between en masse retraction and two-step retraction: A randomized prospective clinical trial. *Angle Orthod.* 2019; 89(2): 190-9.