

Management of patients with aphthous-like ulcers related to aplastic anaemia in the COVID-19 pandemic era through teledentistry: A case report

Lani Berlina Talahatu¹, Bima Ewando Kaban¹, Nurina Febriyanti Ayuningtyas², Intan Noha Brilyanti³, Adiastuti Endah Parmadiati², Desiana Radithia², Aulya Setyo Pratiwi²

¹Oral Medicine Specialist Degree, Faculty of Dental Medicine, Universitas Airlangga, Surabaya, Indonesia

²Department of Oral Medicine, Faculty of Dental Medicine, Universitas Airlangga, Surabaya, Indonesia

³Internist of Internal Medicine Clinic, dr. Soebandi General Hospital, Jember, Indonesia

ABSTRACT

Background: Aplastic anaemia is a disease that occurs when the body fails to produce enough blood cells. Oral lesions, such as canker sores, are often used as an early marker of this disease condition. In the COVID-19 pandemic era, a teledentistry method is expected to assist in the management of patients with various diseases including aplastic anaemia. **Purpose:** This case report discusses the management of patients with aphthous-like ulcers related to aplastic anaemia in a 34-year-old woman, based on history, clinical examination, and blood tests through teledentistry. **Case:** The patient complained of a bleeding wound on the inner left cheek and corner of the left lip that appeared one month ago. There was an ulcer lesion that was bleeding easily in the buccal mucosa sinistra and the angular sinistra, as well as macules lesion on her hand and foot. The complete blood count test exhibits a low platelet level. **Case management:** The diagnosis was an aphthous-like ulcer related to aplastic anaemia. Patient was treated with topical antiseptic and anti-inflammatory mouthwashes for the oral lesions, as well as collaboration with the medical team. The lesions improved after the patient received a blood transfusion and drug therapy from the internist while she was hospitalized, but the lesions reappeared in other locations in the oral cavity when the platelet level dropped. **Conclusion:** Management of oral manifestations in patients with aphthous-like ulcers related to aplastic anaemia in the COVID-19 pandemic era can be done through teledentistry. However, this requires sensitivity from the dentist, patient compliance in following instructions, and the involvement of a multidisciplinary approach, such as collaboration with internists to achieve recovery. Delay in detecting and treating aplastic anaemia will lead to death, as in this case.

Keywords: aphthous-like ulcer; aplastic anaemia; oral ulcer; teledentistry

Correspondence: Nurina Febriyanti Ayuningtyas, Department of Oral Medicine, Faculty of Dental Medicine, Universitas Airlangga. Jl. Mayjen Prof. Dr. Moestopo No 47, Surabaya, 60132 Indonesia. Email: nurina-ayu@fkg.unair.ac.id

INTRODUCTION

Aplastic anaemia is a disease rarely encountered in everyday life. This disease can be life-threatening for the sufferer, but 90% of cases can be successfully treated. The condition of bone marrow-associated pancytopenia with persistent hypocellularity in the absence of major dysplastic signs and fibrosis can be defined as aplastic anaemia. With this disease, the body fails to produce enough blood cells. Blood cells are produced in the bone marrow, and stem cells play a role in the production of blood cells. To confirm the diagnosis of aplastic anaemia, it is necessary

to involve at least two components of the peripheral blood cell examination. Aplastic anaemia causes low levels of all components of blood cells, be it erythrocytes, leucocytes or platelets. Values should be lower for haemoglobin (lower than 10 gr/dl), neutrophils (lower than $1.5 \times 10^9/L$) and platelets (lower than $50 \times 10^9/L$).¹⁻³

Aplastic anaemia often occurs in people in their teens between 15 and 25 years old, but can also occur in people over 60 years old with less incidence. It is caused by genetic factors, autoimmune conditions, exposure to chemicals or radiation and drug use. But in some cases, the aetiology of aplastic anaemia is unknown.^{4,5}

Based on the cause, there are two types of aplastic anaemia, acquired aplastic anaemia and inherited aplastic anaemia. Acquired aplastic anaemia is a T-cell-mediated autoimmune disease. Hematopoietic stem/progenitor cells (HSPCs) destroyed by immune cells have a vital role in the pathophysiological process of acquired aplastic anaemia. Dysregulated CD81 cytotoxic T cells, CD41 T cells namely Th1 (T helper type 1), Th2, regulatory T cells, Th17 cells, NK (natural killer) cells, NK T cells, IFN (interferon)- γ , TNF (tumour) necrosis factor)- α and TGF (transforming growth factor)- β , induce continuous apoptosis of HSPCs and characterize severe acquired aplastic anaemia.⁶

The unsurvival rate of patients with aplastic anaemia can be affected by infection from parvovirus. Parvovirus B19 is often associated with aplastic crises involving only erythrocytes, whereas aplastic anaemia involves all the different components of blood cells. In addition to parvovirus B19, viruses that are frequently associated with the development of aplastic anaemia are HIV, hepatitis, cytomegalovirus and Epstein-Barr.⁷

In several studies with animals (ferrets), aplastic anaemia has another possible cause, namely caused by the toxic nature of oestrogen. In female ferrets treated with ovulation induction and not mated, the oestrogen levels will be high. When oestrogen levels are higher than normal limits, the bone marrow will stop producing erythrocytes.⁷

In aplastic anaemia condition, oral manifestations are often found and this is directly related to pancytopenia. Common oral manifestations involve petechial or spontaneous bleeding, gingival swelling, pallor, ulceration and severe periodontal disease. An aphthous-like ulcer is a diagnosis for recurrent oral ulceration associated with a systemic condition. In aplastic anaemia, these manifestations, as well as petechial haemorrhagic lesions and oral trauma are associated with decreased platelet levels. These lesions are most likely due to a clotting disorder-induced thrombocytopenia, which causes bleeding after minor trauma such as friction with the tongue or teeth.⁸

The World Health Organization (WHO) has declared the COVID-19 outbreak a global pandemic. Overall, this condition has resulted in crises in various fields, including public health. In the field of dentistry, it is known that the potential for cross-infection in the dental clinic is very high because most dental procedures produce aerosols and droplets that can be contaminated with the SARS-COV-2 virus. Therefore, the Indonesian government issued a policy calling for the use of online health services known as telemedicine through Circular Letter No. HK.02.01/MENKES/303/2020 concerning the Implementation of Health Services through the Utilization of Information and Communication Technology in the context of Preventing the Spread of Corona Virus Disease 2019 (COVID-19). The letter explained that telemedicine is a health service facility in the form of consultation to establish a diagnosis, therapy and/or disease prevention.⁹

In the field of dentistry, telemedicine is referred to as teledentistry, which is defined as a combination of telecommunications and dental practice that involves the exchange of clinical information in the form of electronic medical records and digital images remotely for dental consultations treatment planning. Teledentistry services are best used for early detection of disease, providing pre-treatment systemically (orally) to treat disease emergencies and can be a means to monitor a disease condition. In the field of oral disease, the role of teledentistry is an effective alternative in diagnosing oral lesions by sending digital images through electronic media.⁹ This case report discusses the management of patients with aphthous-like ulcers related to aplastic anaemia in a 34-year-old woman during the COVID-19 pandemic era, based on history, clinical examination and blood tests through teledentistry.

CASE

A 32-year-old female patient was consulted via teledentistry on December 26, 2020, complaining of a spontaneous bleeding wound and sore on her inner left cheek and corner of the left lip. The wound appeared one month ago. At first it was a scratch and one week later the wound broke open. If the patient opens her mouth, blood comes from the wound. The patient treated her complaint by drinking cool juice, refreshing solution, and getting injections from a health worker, but her condition did not improve. The patient also stated that her body feels weak. Therefore, 22 days after the initial complaint, the patient was hospitalized for one day at a health worker's house. Two days later the patient went to the doctor and underwent blood tests. The results of the examination showed haemoglobin 5.3 g/dL, erythrocytes 1.8 million/uL, haematocrit 16%, MCV 86 fL, MCH 28 pg, MCHC 33 g/dL, leukocytes 410/uL (type count cannot be done because the leukocyte level is too low), and platelets 150000/uL. The patient received medication, namely: cefadroxil, benostamin, etabion, alphanol, and becom-Z.

This condition had been experienced by the patient several months before with a bleeding and painful wound on the left upper back gum, and was treated by drinking refreshing solution and getting injection therapy from the nurse. But the patient did not know what kind of medication was injected at that time, and then the wound healed within 10 days. Two months before, bruises appeared on the patient's feet and hands. This condition existed until the time the patient's teledentistry consultation, without any new bruises reported.

No one in the patient's family has had a similar experience. This patient has no history of food or drug allergies. She eats vegetables every day, but rarely eats fruit and has a consumption of mineral water more than 1500 ml. The patient's 52 kg in weight and 154 cm in height. The body mass index (BMI) is 22, which is normal.

In the family medical history, her mother had hypertension. On extraoral examination (Figure 1) there are multiple desquamations in the upper and lower lips, clear irregular margin, 1 mm in size, normal surrounding tissue, painless. There is also a solitary crust on the corner of the lip sinistra (Figure 2), 2-3 mm in size, clear irregular margin, rough surface texture, spontaneous bleeding, painful. On her legs and arm (Figure 3), there are multiple macules, various shapes and sizes,

blackish-red in colour, smooth surface texture, clear irregular margin, normal surrounding tissue, and painless. On intraoral examination (Figure 4) there is a solitary ulcer on the buccal mucosa sinistra, 1 x 1.5 cm in size, clear irregular margin, rough surface texture, spontaneous bleeding. The diagnosis of this disease is aphthous-like ulcer related to aplastic anaemia, with a differential diagnosis of aphthous-like ulcer et causa thalassemia and systemic lupus erythematosus.

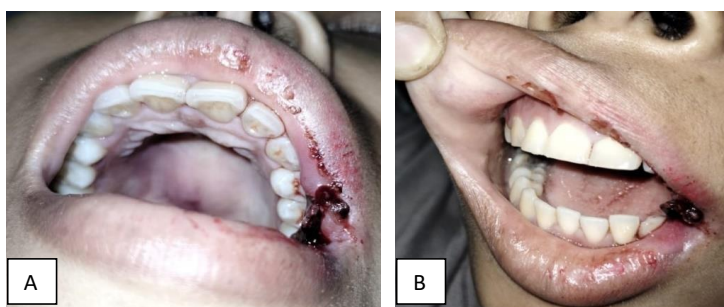


Figure 1. AB. Upper and lower lips: multiple desquamations, clear irregular margin, 1 mm in size, normal surrounding tissue, painless.

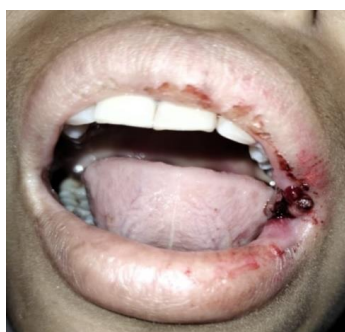

Figure 2. Lip corners sinistra: solitary crust, 2-3 mm in size, clear irregular margin, rough surface texture, spontaneous bleeding, pain.

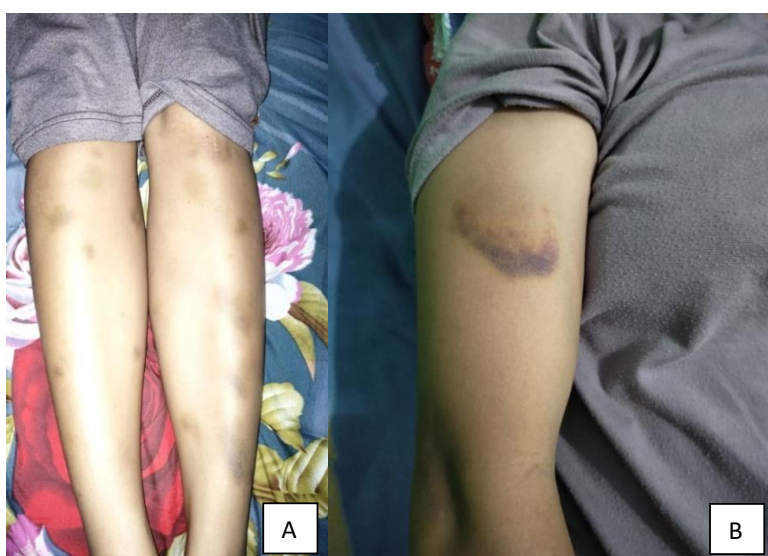


Figure 3. The legs (A) and arm (B): multiple macules, varying in shape and size, red-black in colour, smooth surface texture, clear irregular margin, normal surrounding tissue, painless.

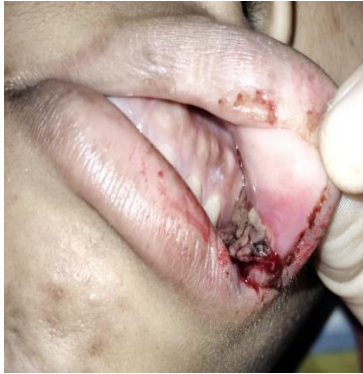

Figure 4. Buccal mucosa sinistra: solitary ulcer, 1x1.5 cm in size, clear irregular margin, rough surface texture, spontaneous bleeding.

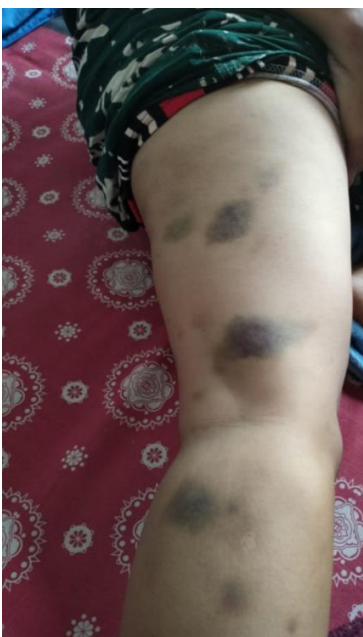

Figure 5. The leg at the first control: multiple maculae, varying in shape and size, blackish-red, smooth surface texture, clear irregular margin, normal surrounding tissue colour, painless.

CASE MANAGEMENT

The oral lesions were treated with 10% povidone-iodine and 1% feracrylum mouthwash. Communicating with the patient about the disease and its possible cause. Instructing the patient in the use of oral topical medications that have been given with the following instructions, eating high nutrition food, not touching the lesions with their tongue and fingers, and using a mask to avoid secondary infection, as well as maintaining oral hygiene.

After consulting through teledentistry, the first action taken was to refer the patient to the emergency department to get therapy for her low platelets level. During hospitalisation, the patient was diagnosed with aplastic anaemia by the internist and received blood transfusion therapy. The patient was hospitalized for four days and received outpatient medication consisting of methylprednisolone, cotrimoxazole, and cefixime.

Ten days later (January 5, 2021), the patient had controlled the condition through teledentistry, and she explained that the bleeding wound on the inside of the left cheek has decreased, and was painless. But new painful and bleeding lesions appeared in other areas of her mouth, namely on the upper right gums. The patient explained that she had checked with the internist four days after discharge from the hospital and underwent another blood test and was given outpatient medication in the form of tranexamic acid, phytomenadione, and cefixime. The results of this second blood test were 11.4 g/dL of haemoglobin, 150/uL of leukocytes, 33.1% of haematocrit, and 7000/uL of platelets. On extraoral examination (Figure 5) there are multiple macules on her feet, with varying shapes and sizes, blackish-red colour, smooth surface texture, clear irregular margin, normal surrounding tissue, and painless.

On the lip corner sinistra there are multiple crusts, 2-3 mm in size, blackish-red colour, clear irregular margin, rough surface texture, spontaneous bleeding, and pain. While on intraoral examination, there was a solitary ulcer on buccal mucosa sinistra, 1x1.5 cm in size, clear irregular margin, rough surface texture, spontaneous bleeding, painless. On the posterior gingival maxilla dextra, there

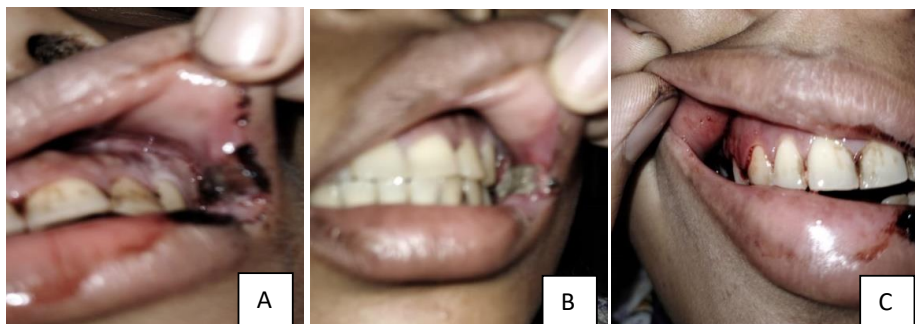


Figure 6. Intraoral examination at first control (A) Corner of the lips sinistra: multiple crusts, 2-3 mm in size, blackish-red, clear irregular margin, rough surface texture, spontaneous bleeding, painless; (B) The buccal mucosa dextra: solitary ulcer, 1x1.5cm in size, clear irregular margin, rough surface texture, spontaneous bleeding, painless; (C) Gingival of the posterior maxilla (dextra): spontaneous gingival bleeding with a recession, painless.

was spontaneous bleeding with gingival recession, and painless (Figure 6). The diagnosis was aphthous-like ulcer related to aplastic anaemia, with a differential diagnosis of aphthous-like ulcer et causa thalassemia and systemic lupus erythematosus. The lesions in the oral cavity are being treated with 10% povidone-iodine solution and aloe vera extract gel. The use of topical drugs as instructed.

DISCUSSION

Aplastic anaemia is described as a severe haematological syndrome, which has the potential to be life-threatening. A hypo or aplastic bone marrow condition indicates aplastic anaemia, which is associated with peripheral pancytopenia. This condition is a rare, sporadic, and non-communicable condition.¹⁰

Based on the severity, there are classifications of aplastic anaemia: moderate, severe, and very severe. In moderate aplastic anaemia, the bone marrow cellularity and levels of two of the three components of hematopoietic cells decreased. In severe aplastic anaemia, they found bone marrow cellularity <30%, a decrease in two of the three components of hematopoietic cells, absolute neutrophil count (ANC) <0.5x10⁹/L, and the need for transfusion. Very severe aplastic anaemia showed the same symptoms as severe aplastic anaemia, but the ANC in very severe aplastic anaemia was <0.2x10⁹/L.^{11,12} In this case, there is a decrease in haemoglobin, erythrocytes, haematocrit, MCV, MCH, MCHC, and leukocytes. The ANC cannot be done because it is too low. So, the aplastic anaemia in this patient is very severe aplastic anaemia.

The oral manifestations of aplastic anaemia may be the very first clinical symptoms of the disease and are directly associated with pancytopenia. The common features include petechial purpuric spots or oral mucosal hematomas, while gingival haemorrhage may be seen in some cases; these findings are seen because of platelet deficiency. Ulcerative lesions of oral mucosa and pharynx are seen due to neutropenia.¹³ In this case, the patient had oral manifestations in the form of oral ulceration and spontaneous bleeding in the gingiva and oral mucosa. There are multiple crusted lesions in the upper and lower lip. Oral ulcers in patients with aplastic anaemia have been reported to be associated with deficiencies of vitamins B (include B1, B2, B6, B12), folic acid, iron, and serum ferritin. Aplastic anaemia associated with iron deficiency results in painful angular cheilitis and depapillation of the tongue, as well as erosive and crusty lesions in the perioral area and lip commissures.¹⁴

An aphthous-like ulcer is similar to recurrent aphthous stomatitis (RAS). If the occurrence of aphthae is associated with a compromised systemic condition, the term aphthous-like ulcer is more appropriate, since aphthae are considered a secondary manifestation of systemic disease and have a different clinical history, as well as require different management strategies from RAS. Clinically, aphthous-

like ulcers are shallow, round/oval-shaped lesions, granular surface texture, and pain. Usually, the lesions appear suddenly and are accompanied by systemic symptoms.¹⁴

The aphthous-like ulcer can be determined based on the patient's medical history, the presence of lesions affecting the skin, mucosa other than the oral cavity (eye mucosa or genital mucosa), and the digestive and respiratory tract. In addition, a complete blood count can also confirm the diagnosis of an aphthous-like ulcer and relate it to the systemic condition.¹⁵ In this case, the ulcer lesion was found in the patient's oral cavity, as well as spontaneous bleeding in the gingiva, that took one month to heal. Extraoral lesions were also found; there are multiple blackish macules in the extremities. On supportive examination, several blood component levels were decreased, namely haemoglobin, erythrocytes, haematocrit, MCV, MCH, MCHC, leukocytes, and platelets. Based on anamnesis and objectives examination, this case was diagnosed as an aphthous-like ulcer related to aplastic anaemia.

In the COVID-19 pandemic era, many patients with various diseases were unable to obtain health services as they should have. Therefore, to facilitate patient access so that they can continue receiving health services, dentists provide consulting services and disease therapy as first aid efforts through the teledentistry method. This case was handled during the COVID-19 pandemic era, so their medical history, objective examination, treatment planning, and controlling the patient's oral complaints were all carried out through teledentistry. Management of patients through teledentistry considers the sensitivity of a dentist in detecting disease, patient compliance in carrying out dentist's instructions, as well as the selection of medications that are easy to obtain and safe.

Management of oral lesions in patients with aplastic anaemia requires treatment in conjunction with other disciplines, such as internists or haematology. Immediate referral of patients for special care is undoubtedly an important step in the management of this disease.⁸ So in this case, before treating the oral lesions, first refer her to the emergency department for first aid. As for the treatment of teeth or lesions in the oral cavity, it should be done at the same time as the platelet transfusion. The effective management of aplastic anaemia will lead to improving oral lesions caused by systemic conditions. According to theory, the management of aplastic anaemia consists of general management and specific management. General management can include insertion of a nasogastric tube, platelet transfusion or packed red cell depending on need, antifibrinolytic, antibiotics, and antipyretics. Specific management may include giving immunosuppressants, such as cyclosporine/antithymocyte, corticosteroids, granulocyte colony-stimulating factor, and stem cell transplantation.¹⁵

General management is carried out in the form of platelet transfusions, cotrimoxazole, cefixime, tranexamic acid, and phytomenadione. Platelet transfusions are given to patients due to platelet levels being too low (150000/uL). Antibiotics are given to prevent secondary infection.

The phytonadione and tranexamic acid were intended as an anticoagulant and antifibrinolytic due to the patient's severe thrombocytopenia. Specific management performed on the patient is the administration of immunosuppressants (methylprednisolone).

Treatment of patients with aphthous-like ulcers depends on the aetiology, i.e., therapy for the underlying cause. If there is a medical history that is the cause of an aphthous-like ulcer (haematological, infectious, gastrointestinal, or skin disease), it should be considered to determine the type of therapy that is needed. It is also important to pay attention to local factors, including sharp tooth surfaces, wearing of dentures and other devices, and the occurrence of biting the oral mucosa during chewing. For aphthous ulcers such as aphthous-like ulcers, topical corticosteroids or tacrolimus can be given.¹⁵

During primary dental care, patients should take antifibrinolytics to avoid excessive bleeding. These agents can reduce the occurrence of bleeding, especially in the oral mucosa. In patients with thrombocytopenia, this can be done by stabilizing the thrombus. There are case reports explaining that aplastic anaemia can be treated by platelet transfusion at the start of treatment, instructions for maintaining oral hygiene, prophylaxis, and systemic administration of aminocaproic acid. Infections often occur in susceptible aplastic anaemia sufferers, therefore dental treatment should be postponed until the patient's condition is stable, that is until the patient's leukocyte level is within normal limits. Dentists should consider prescribing antibacterial mouthwashes and oral antibiotics before dental procedures to prevent foci of infection. Consultation with a haematologist also needs to be done before receiving dental and oral treatment, so that the potential for systemic infection during treatment can be avoided.⁸

In this patient, the overall management of oral lesions was carried out by teledentistry and assisted by an internist who cared for her during hospitalisation. The patient had received oral corticosteroid medication from an internist, namely methylprednisolone, so the patient did not need to be given any more topical corticosteroid medication for her oral lesions. To prevent secondary infection in the oral mucosa, the patient was given an antiseptic mouthwash in the form of 10% povidone-iodine solution. Also, a 1% feracrylum mouthwash was given to avoid spontaneous bleeding in the oral mucosa. In the current study, the 1% feracrylum citrate was used as a novel haemostatic agent. It is an effective, safe, reliable topical agent.¹⁶ As an anti-inflammatory topical drug, aloe vera extract gel was used to inhibit the inflammation in the oral lesions. The patient was instructed not to touch the wound in her mouth carelessly because the wound bleeds easily even with a light touch.

The prognosis of patients with aphthous-like ulcers related to aplastic anaemia will be better if the doctor detects early systemic abnormalities suffered by the patient. Prompt, appropriate, and adequate therapy will also improve the prognosis of this disease. If there is a delay in detecting aplastic anaemia that is the cause of the aphthous-

like ulcer, so that appropriate therapy is delayed, it can lead to death. The patient in this case experienced delays in early detection of the disease, resulting in delays in treatment. This was fatal, and the patient died 46 days after the first complaint appeared and 21 days after her consultation through teledentistry, despite receiving multidisciplinary therapy thereafter. Management of oral manifestations in patients with aplastic anaemia requires a multidisciplinary approach to achieve complete recovery.

In conclusion, during the COVID-19 pandemic, patient management in the field of oral medicine was carried out through teledentistry. The management of this aphthous like ulcer et causa aplastic anaemia, including history taking, diagnosis, and treatment planning was done online. An aphthous-like ulcer is an intra-oral condition that can occur in patients with haematological disorders. An Aphthous-like ulcer in haematological disorders like aplastic anaemia needs to be treated quickly and appropriately. In this case, the management requires a multidisciplinary approach, so that the patients can achieve complete recovery.

ACKNOWLEDGEMENT

The author wishes to thank the Internal Medicine Clinic of dr. Soebandi General Hospital, Jember, East Java, Indonesia.

REFERENCES

1. Miano M, Dufour C. The diagnosis and treatment of aplastic anemia: A review. *Int J Hematol.* 2015; 101(6): 527–35.
2. Young NS. Aplastic Anemia. Longo DL, editor. *N Engl J Med.* 2018; 379(17): 1643–56.
3. Djudad S, Yoarva Malano. Management of aplastic anemia in pregnancy: A case report. *Indones J Obstet Gynecol.* 2020; 8(2): 125–8.
4. Brodsky RA, Jones RJ. Aplastic anaemia. *Lancet.* 2005; 365(9471): 1647–56.
5. Peinemann F, Bartel C, Grouven U. First-line allogeneic hematopoietic stem cell transplantation of HLA-matched sibling donors compared with first-line ciclosporin and/or antithymocyte or antilymphocyte globulin for acquired severe aplastic anemia. *Cochrane database Syst Rev.* 2013; 2013(7): CD006407.
6. Zeng Y, Katsanis E. The complex pathophysiology of acquired aplastic anaemia. *Clin Exp Immunol.* 2015; 180(3): 361–70.
7. Wang L, Liu H. Pathogenesis of aplastic anemia. *Hematology.* 2019; 24(1): 559–66.
8. Rai A, Vaishali V, Naikmasur VG, Kumar A, Sattur A. Aplastic anemia presenting as bleeding of gingiva: Case report and dental considerations. *Saudi J Dent Res.* 2016; 7(1): 69–72.
9. Amtha R, Gunardi I, Astoeti TE, Roeslan MO. Characteristic of oral medicine patient using teledentistry during covid-19 pandemic. *ODONTO Dent J.* 2021; 8(1): 18–27.
10. Dinca AL, Marginean OC, Melit LE, Damian R, Chincesan M. Aplastic anaemia: Therapeutic and deontological aspects. *Rom J Pediatr.* 2016; 65(1): 56–9.
11. Singh P, Sinha A, Kamath A, Malhotra S, Chandra AB. Aplastic anemia- A quick review. *J Cancer Prev Curr Res.* 2017; 7(5): 1–6.
12. Guinan EC. Diagnosis and management of aplastic anemia. *Hematol Am Soc Hematol Educ Progr.* 2011; 2011: 76–81.
13. Anitha N, Appadurai P. Anemia and its oral manifestation. *Eur J Mol Clin Med.* 2020; 7(8): 1715–9.

14. Cappello F, Rappa F, Canepa F, Carini F, Mazzola M, Tomasello G, Bonaventura G, Giuliana G, Leone A, Saguto D, Scalia F, Bucchieri F, Fucarino A, Campisi G. Probiotics can cure oral aphthous-like ulcers in inflammatory bowel disease patients: A review of the literature and a working hypothesis. *Int J Mol Sci.* 2019; 20(20): 5026.
15. Putra M, Aprijadi H. Anemia aplastik berat dengan komplikasi febril neutropenia dan perdarahan pada perempuan usia 20 tahun. *J Agromedicine.* 2019; 6(1): 226–30.
16. Valse D, Hosalli Kumaraswamy N. To evaluate the role of Feracrylum (1%) as hemostatic agent in Tonsillectomy. *Indian J Otolaryngol Head Neck Surg.* 2021; 73(2): 240–5.