

### ***Pangasius djambal* gelatin increases osteoprotegerin, decreases RANK and RANKL after tooth extraction in vivo**

Fredy Mardiyantoro<sup>1</sup>, Nenny Prasetyaningrum<sup>2</sup>, Lukman H. Hidayat<sup>3</sup>, Uswatun Khasanah<sup>4</sup>, Virginia C. Roring<sup>4</sup>, Ahida Muizun<sup>4</sup>, Varella A. W. Kardikadewi<sup>5</sup>

<sup>1</sup>Department of Oral and Maxillofacial Surgery, Faculty of Dentistry, Universitas Brawijaya, Malang, Indonesia

<sup>2</sup>Department of Oral Biology, Faculty of Dentistry, Universitas Brawijaya, Malang, Indonesia

<sup>3</sup>Department of Oral Medicine, Faculty of Dentistry, Universitas Brawijaya, Malang, Indonesia

<sup>4</sup>Undergraduate Student, Faculty of Dentistry, Universitas Brawijaya, Malang, Indonesia

<sup>5</sup>Postgraduate Student of Dental Health Science, Faculty of Dental Medicine, Universitas Airlangga, Surabaya, Indonesia

#### **ABSTRACT**

**Background:** Osteoprotegerin (OPG) plays a role in preventing osteoclast formation and osteoclastic bone resorption by inhibiting the receptor activator nuclear factor- $\beta$  and its ligand (RANK–RANKL) interaction that causes bone resorption. *Pangasius djambal* gelatin contains essential amino acids that may stimulate bone remodeling. **Purpose:** This study aimed to investigate the expressions of OPG, RANKL, and RANK following tooth extraction to ascertain whether OPG is associated with the RANKL and RANK ratios following gelatin induction. **Methods:** This study was a true experimental study with a simple, randomized post-test only control group design. Twenty-four albino rats (*Rattus norvegicus*) were divided into two groups ( $n = 4$ ). The treatment group was treated with *P. djambal* gelatin following tooth extraction, while the control group was left untreated. Animal models undergoing tooth extraction were anesthetized intraperitoneally with ketamine (1,000 mg/10 ml up to 0.2 ml). The tooth was then extracted slowly so as not to break it. *P. djambal* gelatin was dripped (0.1 ml) into the socket after the extraction procedure. The association of OPG with RANKL and RANK immunohistochemistry expressions was evaluated after three, five, and seven days. **Results:** There was a significant increase in OPG expression on day 7 ( $P < 0.05$ ) and a significant decrease in the expression of RANKL and RANK ( $P < 0.05$ ) in the treatment group. **Conclusion:** The application of *P. djambal* gelatin could increase OPG expression, decrease RANKL and RANK expression in the socket following tooth extraction, and might be associated with the inhibition of bone resorption.

**Keywords:** medicine; osteoprotegerin; receptor activator nuclear factor- $\beta$ ; receptor activator nuclear factor- $\beta$  ligand; tooth extraction

**Article history:** Received 29 October 2022; Revised 14 March 2023; Accepted 28 March 2023; Published 1 December 2023

Correspondence: Fredy Mardiyantoro, Department of Oral and Maxillofacial Surgery, Faculty of Dentistry, Universitas Brawijaya, Malang, Indonesia. Email: fredy.fre@ub.ac.id

#### **INTRODUCTION**

Tooth extraction is followed by alveolar bone resorption, which rapidly begins during the first 12 months after tooth extraction.<sup>1</sup> Tooth extraction is a traumatic procedure that damages the supporting tissues of the tooth, including periodontal tissues such as the gums, the periodontal ligament, cementum, and alveolar bone, resulting in alveolar injury or trauma.<sup>2</sup> Following tooth extraction, there is a wound healing process that generally consists of inflammation, proliferation, and remodeling,<sup>3</sup> while the socket's alveolar bone often undergoes bone loss. Alveolar ridge preservation should be performed to

reduce undesirable horizontal and vertical ridge reduction following extraction and facilitate prosthetically-driven implant placement.<sup>4</sup>

In general, socket healing after tooth extraction is essentially the same as soft tissue wound healing.<sup>5</sup> Four cellular components—osteoblasts, osteoclasts, osteocytes, and bone lining cells—act simultaneously in the cup healing process and jawbone remodeling after tooth extraction.<sup>6</sup> During the remodeling process, osteoblasts release cytokines in the form of osteoprotegerin (OPG) and receptor activator nuclear factor-beta ( $\beta$ ) ligand (RANKL), while RANKL itself has a progenitor receptor from pre-osteoclasts known as receptor activator nuclear

factor- $\beta$  (RANK). This interaction between OPG, RANKL and RANK determines the rate of the bone remodeling process. However, excessive interaction between RANK and RANKL can disrupt bone remodeling and promote bone resorption.<sup>7</sup>

Nowadays, many materials have been developed to accelerate the healing process; one of the materials being investigated is catfish gelatin.<sup>8</sup> *Pangasius djambal* gelatin has proven to be superior to other types of fish gelatin, with a 2.84% whiter and moister appearance, 87.1% higher protein content, a very low ash content (0.5%), and 0.002% reduced fat. The amino acid composition in *P. djambal* gelatin is also extremely high, including proline, glycine, lysine, alanine, and arginine, which are the main amino acids contained in gelatin.<sup>9,10</sup> The interaction between OPG, RANKL, and RANK is highly important in the process of bone remodeling. Specifically, RANKL and RANK stimulate osteoclast formation, activation, differentiation, and survival leading to osteoclastogenesis. The increased OPG will bind to the RANK, causing inhibition of osteoclastogenesis activity.<sup>11,12</sup> Therefore, this study aimed to investigate the expressions of OPG, RANKL, and RANK in the tooth socket to ascertain whether OPG has associations with RANKL and RANK ratios as a marker of bone resorption following *P. djambal* gelatin induction using Wistar rats (*Rattus norvegicus*).

## MATERIALS AND METHODS

This study used an experimental method with a simple, blind, randomized post-test only control group design. The animal model involved in the study was a male Wistar (*Rattus norvegicus*) strain albino rat, which was 2–3 weeks old, male, healthy, white, active, and weighed 250–300 mg, with normal behavior, no anatomical abnormalities, and stable health status during the study period. A total of 24 rats were divided into six groups of four, were housed and acclimatized at room temperature (22°C–24°C) for seven days in the Biochemical Laboratory, Faculty of Medicine, at Brawijaya University. The sample size was determined based on the resource equation approach. All experiments were performed in accordance with research ethics committee guidelines (approval no. #198/EC/KEPK-s1-FKG/08/2018)

The gelatin was made from *P. djambal* skin. The skin was then stored in a –200°C cupboard before being cut into small pieces of approximately 1 cm<sup>2</sup> to obtain 100 g of catfish skin. Following this, the catfish skin was rinsed with lemon water and then pure water before being soaked in a citric acid solution for 12 h. Next, the skin was neutralized by washing it several times with neutral water until it reached a neutral pH (6–7). The skin was then extracted at 60°C for 6 h using a shaking water bath and distilled water. The gelatin solution and remaining skin were separated using a #1 Whatman filter cloth. The gelatin solution was then cooled to room temperature to form a gelatin gel.

The animal models undergoing tooth extraction were anesthetized intraperitoneally with ketamine (1,000 mg/10 ml up to 0.2 ml). The tooth was extracted slowly so as not to break it. Approximately 0.1 ml of gelatin was dripped into the socket after the extraction procedure. The control and study jaws were then decapitated on days 3, 5, and 7 and prepared for tissue preparation in the Pathology–Anatomy laboratory, Faculty of Dentistry at Brawijaya University.

Immunohistochemical staining was used to confirm the expression of OPG, RANKL and RANK. The immunohistochemical staining method used was indirect immunohistochemistry, which employs a monoclonal antibody (Santa Cruz Biotechnology, Inc. Dallas, Texas 75220 USA) to investigate tissue-recognizing antigens, and a secondary antibody to detect the primary antibody using a Diaminobenzidine (DAB) chromogenic substrate to produce a brown color. The analysis of OPG, RANKL, and RANK expression was quantitative, and the number of positive cells was counted in ten representative fields: five fields in the upper side and five in the lower side, with consecutive microscopic high-power fields (400 and 1,000 of magnification). Digital images were loaded into OlyVIA software (Maryland, USA) to count the number of immunostained cells.

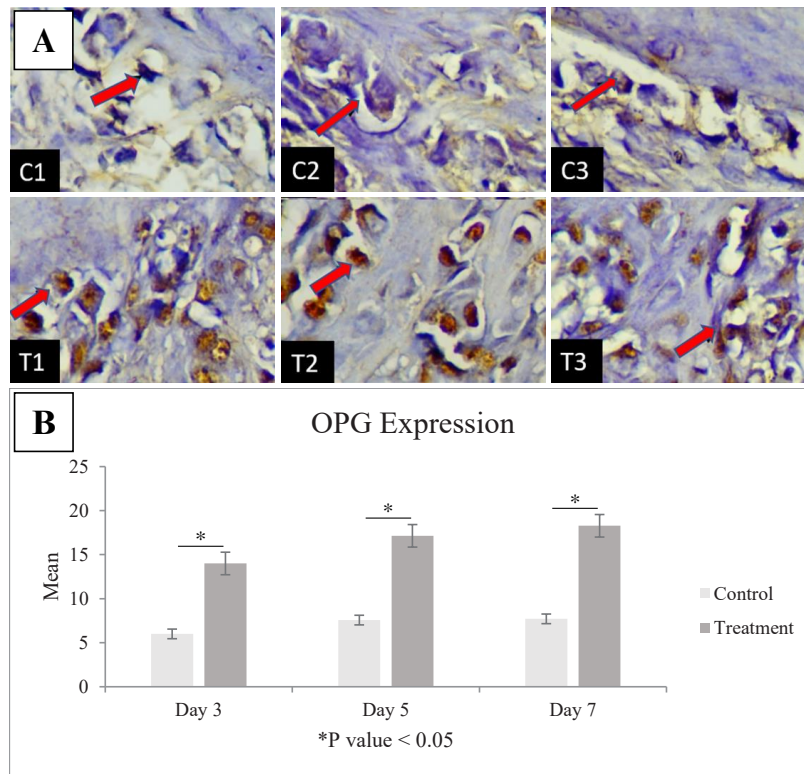
All data were analyzed using the personal computer 20.0 version of SPSS software for Windows (SPSS/PC, Inc. version 22.0, Chicago, IL, USA). Normality was checked using the Shapiro–Wilk test and homogeneity of variances was examined using the Levene’s test, followed by a one-way ANOVA test to determine whether there were any statistical differences of growth factor expressions between the control and treatment groups. A *P*-value of <0.05 was considered statistically significant.

## RESULTS

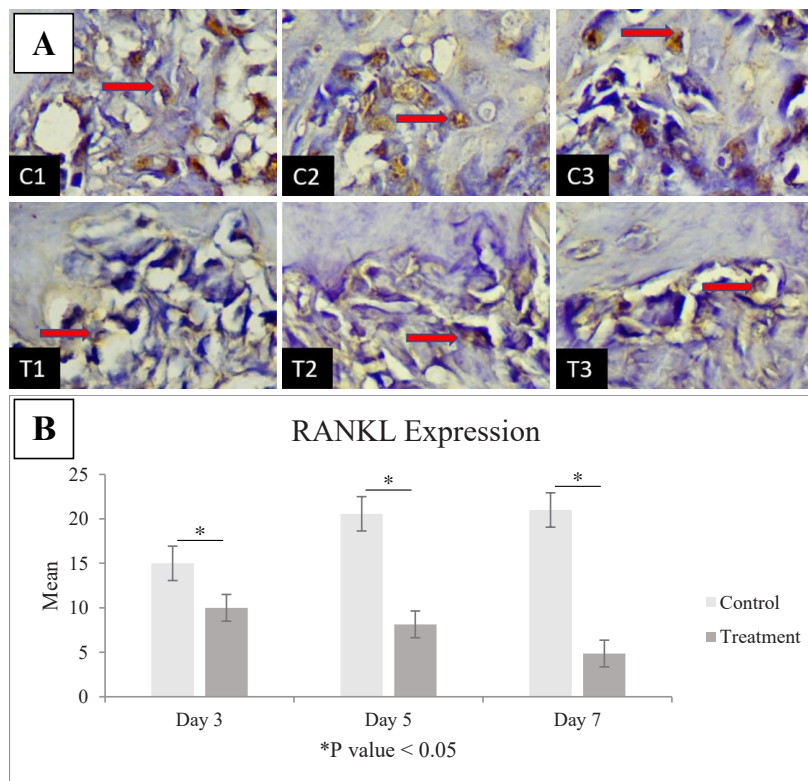
The highest level of OPG expression occurred on day 7 in the treatment group (18.28 ± 2.28), while the lowest occurred in the control group (6.00 ± 2.58) on day 3 (Figure 1A, B). The OPG expression was higher in the control group than in the treatment group. There was a statistically significant decrease in OPG immune expression in the *P. djambal* gelatin-treated group compared with the control group (*P* < 0.05).

The highest level of RANKL expression occurred on day 7 in the control group (21.00 ± 3.05), while the lowest level also occurred on day 7 but in the treatment group (4.86 ± 2.11) (Figure 2A, B). The RANKL expression was higher in the control group than in the treatment group, while RANKL immune expression was statistically significantly reduced in the *P. djambal* gelatin-treated group compared with the control group (*P* < 0.05).

The highest level of RANK expression occurred on day 7 in the control group (15.60 ± 2.30) and the lowest level also occurred on day 7 but in the treatment group (5.80 ± 0.83) (Figure 3A, B). The RANK expression was

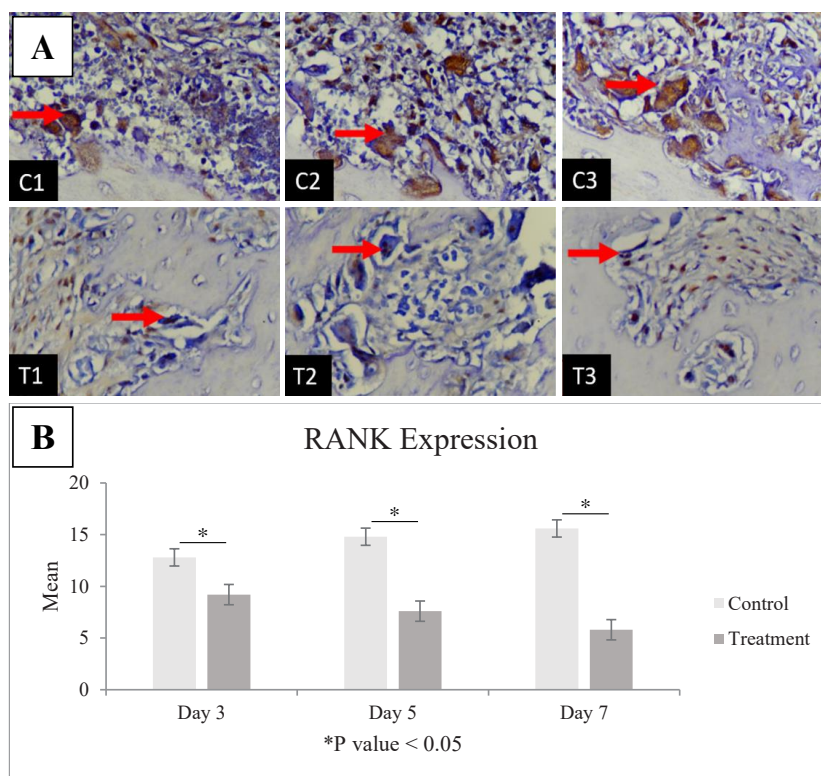


**Figure 1.** A. The results of the histopathological examination of OPG expressions (indicated by the red arrows) for the control groups for day 3 (C1), day 5 (C2), and day 7 (C3), and the treatment groups on day 3 (T1), day 5 (T2) and day 7 (T3). B. Quantification of OPG-positive cells.



**Figure 2.** A. The results of the histopathological examination of RANKL expressions (indicated by the red arrows) for the control groups on day 3 (C1), day 5 (C2), and day 7 (C3), and for the treatment groups on day 3 (T1), day 5 (T2) and day 7 (T3). B. Quantification of RANKL-positive cells.





**Figure 3.** A. The results of the histopathological examination of RANK expressions (indicated by the red arrows) for the control groups on day 3 (C1), day 5 (C2), and day 7 (C3), and for the treatment groups on day 3 (T1), day 5 (T2) and day 7 (T3). B. Quantification of RANK-positive cells.

higher in the control group than in the treatment group. There was a statistically significant decrease in RANK immune expression in the *P. djambal* gelatin-treated group compared with the control group ( $P < 0.05$ ).

## DISCUSSION

During the socket healing process after tooth extraction, a remodeling process occurs where the bone becomes progressively immature and will undergo remodeling into trabecular bone and spongy bone, which can last up to one year.<sup>11</sup> Both OPG and RANKL have roles in terms of being mutual competitors. Specifically, OPG is a key regulator in the bone remodeling process, expressed by osteoblasts, and plays a positive role in hard tissue healing. Increased OPG expression in the injured socket area is directly proportional to new bone formation and accelerates the hard tissue healing process.<sup>12</sup> However, the osteoblasts in OPG inhibit the binding of RANKL to RANK such that osteoclasts are not formed.<sup>13</sup> Decreased expression of RANKL in the wound cavity after tooth extraction can impair hard tissue healing. Meanwhile, decreased numbers of RANKL may also reduce osteoclast activation, disrupting the bone resorption process during the healing of bone tissue. The function of osteoclasts is to create a boundary between dead and healthy hard tissues and to clear away the dead tissue. After necrotic tissue is removed, osteoclasts separate areas

of healthy tissue. Decreased osteoclast function can lead to inadequate cleansing of necrotic tissue in hard tissues and impaired bone healing. Thus, decreased RANKL expression and reduced osteoclast activation leads to suboptimal hard tissue healing processes.<sup>14</sup> The RANKL–OPG balance can affect osteoclast activity, and RANKL is expressed by osteoblasts and bone stromal cells;<sup>15</sup> RANK receptors are produced by osteoclasts. The interaction between RANKL and RANK stimulates osteoclast formation, activation, differentiation, and survival, leading to osteoclastogenesis and subsequent bone resorption.<sup>16</sup>

Meanwhile, OPG, which is primarily made by osteoblasts, is a soluble RANKL decoy receptor that inhibits the RANKL–RANK interaction to stop the production of osteoclasts and osteoclastic bone resorption. Contrarily, RANKL expression is boosted in osteoblasts by cytokines and hormones that stimulate bone resorption. Mature osteoclasts also express RANK and RANKL, which promote osteoclast activity and survival, as well as bone resorption.<sup>7</sup> Based on the experiment performed in this study, OPG significantly increases after treatment (Figure 1). It might be possible to inhibit bone resorption through increased OPG expression. Bone resorption depends on the RANK–RANKL–OPG system, which is a major regulatory system of osteoclast differentiation, induction, activation, and survival.<sup>17,18</sup> By halting osteoclastic bone resorption, RANKL–RANK interaction can send inhibition signals in the bone, enhancing bone mass. According to earlier

studies, mature osteoclasts release vesicular RANK, which binds to osteoblastic RANKL and encourages bone formation by inducing RANKL reversing signals.<sup>19</sup>

In the present study, the expression of RANK and RANKL showed interesting results, demonstrating a decrease after treatment when compared with the control group. Osteoclast differentiation, fusion, survival, and activation all depend on RANKL. Specifically, RANKL controls osteoclastogenesis in bone remodeling and modeling, respectively, on the surfaces of osteoblasts and osteocytes.<sup>15,20</sup> This study is also in line with a previous study that demonstrated how gelatin could regulate RANKL-induced osteoclast differentiation through TGF- $\beta$ 1 signaling pathways.<sup>21</sup> As noted, OPG and RANKL play a role as mutual competitors, which was confirmed through this study's results, which showed that there is an increase in the amount of OPG compared with RANKL and RANK. Based on this study, it can be concluded that the application of *P. djambal* gelatin can increase OPG expression and decrease RANKL and RANK expression in the socket following tooth extraction in Wistar rats (*R. norvegicus*), as documented immunohistochemically.

## REFERENCES

1. Stumbras A, Kuliesius P, Januzis G, Juodzbalys G. Alveolar ridge preservation after tooth extraction using different bone graft materials and autologous platelet concentrates: a systematic review. *J Oral Maxillofac Res.* 2019; 10(1): e2.
2. Rezkita F, Wibawa KGP, Nugraha AP. Curcumin loaded chitosan nanoparticle for accelerating the post extraction wound healing in diabetes mellitus patient: a review. *Res J Pharm Technol.* 2020; 13(2): 1039–42.
3. Kamadjaja MJK, Salim S, Waluyo WH, Noor TNE binti TA. Evaluation of BSP and DMPI in hydroxyapatite crab shells used for dental socket preservation. *Dent J.* 2023; 56(2): 104–8.
4. Juodzbalys G, Stumbras A, Goyushov S, Duruel O, Tözüm TF. Morphological classification of extraction sockets and clinical decision tree for socket preservation/augmentation after tooth extraction: a systematic review. *J Oral Maxillofac Res.* 2019; 10(3): e3.
5. Prahasanti C, Nugraha AP, Saskianti T, Suardita K, Riawan W, Ernawati DS. Exfoliated human deciduous tooth stem cells incorporating carbonate apatite scaffold enhance BMP-2, BMP-7 and attenuate MMP-8 expression during initial alveolar bone remodeling in Wistar rats (*Rattus norvegicus*). *Clin Cosmet Investig Dent.* 2020; 12: 79–85.
6. Saskianti T, Nugraha AP, Prahasanti C, Ernawati DS, Suardita K, Riawan W. Immunohistochemical analysis of stem cells from human exfoliated deciduous teeth seeded in carbonate apatite scaffold for the alveolar bone defect in Wistar rats (*Rattus norvegicus*). *F1000Research.* 2020; 9: 1164.
7. Yasuda H. Discovery of the RANKL/RANK/OPG system. *J Bone Miner Metab.* 2021; 39(1): 2–11.
8. Mardiyantoro F, Prasetyaningrum N, Cahyati M, Abidin ZZ. Potential effect of djambal catfish (*Pangasius djambal*) gelatin as biomaterial product on healing socket after tooth extraction in rats. *Indian J Forensic Med Toxicol.* 2021; 15(2): 2379–87.
9. Ratnasari I, Yuwono SS, Nusyam H, Widjanarko SB. Extraction and characterization of gelatin from different fresh water fishes as alternative sources of gelatin. *Int Food Res J.* 2013; 20(6): 3085–91.
10. Alexander JW, Supp DM. Role of arginine and omega-3 fatty acids in wound healing and infection. *Adv Wound Care.* 2014; 3(11): 682–90.
11. Mardiyantoro F, Munika K, Sutanti V, Cahyati M, Pratiwi AR. *Penyembuhan luka rongga mulut.* Malang: UB Press; 2018. p. 165.
12. Deligiorgi M V, Panayiotidis MI, Griniatsos J, Trafalis DT. Harnessing the versatile role of OPG in bone oncology: counterbalancing RANKL and TRAIL signaling and beyond. *Clin Exp Metastasis.* 2020; 37(1): 13–30.
13. Heinemann C, Heinemann S, Bernhardt A, Lode A, Worch H, Hanke T. In vitro osteoclastogenesis on textile chitosan scaffold. *Eur Cells Mater.* 2010; 19: 96–106.
14. Narmada IB, Husodo KRD, Ardani IGAW, Rahmawati D, Nugraha AP, Iskandar RPD. Effect of vitamin D during orthodontic tooth movement on receptor activator of nuclear factor Kappa-B ligand expression and osteoclast number in pregnant wistar rat (*Rattus norvegicus*). *J Krishna Inst Med Sci Univ.* 2019; 8(1): 37–42.
15. Udagawa N, Koide M, Nakamura M, Nakamichi Y, Yamashita T, Uehara S, Kobayashi Y, Furuya Y, Yasuda H, Fukuda C, Tsuda E. Osteoclast differentiation by RANKL and OPG signaling pathways. *J Bone Miner Metab.* 2021; 39(1): 19–26.
16. Ikebuchi Y, Aoki S, Honma M, Hayashi M, Sugamori Y, Khan M, Kariya Y, Kato G, Tabata Y, Penninger JM, Udagawa N, Aoki K, Suzuki H. Coupling of bone resorption and formation by RANKL reverse signalling. *Nature.* 2018; 561(7722): 195–200.
17. Blair HC, Schlesinger PH, Huang CLH, Zaidi M. Calcium signalling and calcium transport in bone disease. In: *Calcium Signalling and Disease.* Dordrecht: Springer Netherlands; 2007. p. 539–62.
18. Soekobagiono S, Alfiandy A, Dahlan A. RANKL expressions in preservation of surgical tooth extraction treated with *Moringa (Moringa oleifera)* leaf extract and demineralized freeze-dried bovine bone xenograft. *Dent J.* 2018; 50(3): 149–53.
19. Tobeiha M, Moghadasian MH, Amin N, Jafarnejad S. RANKL/RANK/OPG pathway: A mechanism involved in exercise-induced bone remodeling. *Biomed Res Int.* 2020; 2020: 6910312.
20. Devitangingtyas N, Syaify A, Herawati D. Combining 10% propolis with carbonated hydroxyapatite to observe the RANKL expression in a rabbit's alveolar bone. *Dent J.* 2020; 53(4): 212–6.
21. Kuo C-H, Chen J-Y, Chen C-M, Huang CW, Liou Y-M. Effects of varying gelatin coating concentrations on RANKL induced osteoclastogenesis. *Exp Cell Res.* 2021; 400(2): 112509.