

Increase of collagen in diabetes-related traumatic ulcers after the application of liquid smoke coconut shell

Meircurius Dwi Condro Surboyo,¹ Ira Arundina,² and Retno Pudji Rahayu³

¹Master Program in Dental Health Science

²Department of Oral Biology

³Department of Oral Pathology and Maxillofacial
Faculty of Dental Medicine, Universitas Airlangga
Surabaya - Indonesia

ABSTRACT

Background: Traumatic ulcers in patients with diabetes mellitus may experience delayed healing despite their diabetic condition being controlled. Liquid smoke coconut shell containing phenolic compounds can potentially accelerate the healing process. One healing process indicator is the increased number of fibroblasts, another being the increased amount of collagen. **Purpose:** This study aimed to analyze the amount of collagen in traumatic ulcers in diabetics after application of liquid smoke coconut shell. **Methods:** Alloxan was induced in twenty-four male Wistar rats as models of diabetes mellitus. A traumatic 10 mm ulcer was made along the labial fornix incisive inferior with a round, stainless steel blade before liquid smoke coconut shell and benzydamine hydrochloride (as the control) was administrated once a day. A biopsy of the labial fornix incisive inferior was subsequently performed after the topical application for 5 and 7 days. Histological assessment was conducted to analyze the amount of collagen by means of Masson Trichome staining. **Results:** Histologically, the topical application of liquid smoke coconut shell for 5 days significantly increased the amount of collagen, higher than that of benzydamine hydrochloride as the control ($p=0.006$) ($p<0.05$). Meanwhile, the topical application of liquid smoke coconut shell for 7 days made the concentration of collagen no significantly different from that of benzydamine hydrochloride as the control ($p=0.156$) ($p>0.05$). **Conclusion:** Liquid smoke coconut shell applied for 5 days increase the amount of collagen in traumatic ulcers in diabetic patients.

Keywords: liquid smoke coconut shell; traumatic ulcer; diabetes mellitus; collagen

Correspondence: Ira Arundina, Department of Oral Biology, Faculty of Dental Medicine, Universitas Airlangga. Jl. Mayjend. Prof. Dr. Moestopo no. 47 Surabaya 60132, Indonesia. E-mail: arundinafk@yahoo.com.

INTRODUCTION

Diabetes mellitus is prone to the onset of both traumatic and aphtous ulcers in the oral mucosa. Its prevalence shows that 24.2% of ulcerated lesions (traumatic and aphtous ulcers), were found in the oral mucosa in diabetics, while 5.4% of patients with diabetes mellitus presented traumatic ulcers.^{1,2}

Traumatic ulcers in people suffering from diabetes mellitus may experience delayed healing despite their diabetic condition being under control.³ The main complain resulting from a traumatic ulcer is that of pain caused by the loss of the epithelial layer within the oral cavity. This

results in the opening of nerve endings in the lamina propria, producing pain.⁴ The topical application often employed is in the form of mouthwash which serves as a supportive therapy.

Benzydamine hydrochloride is a nonsteroid anti-inflammation drug (NSAID) possessing analgesic, anti-inflammatory, and antimicrobial properties that is available in the form of a mouthwash. It is appropriate for ulcer therapy with predisposing diabetes and its working mechanism may be associated with the inhibition of prostaglandin and inflammatory cytokine.⁵ Nevertheless, there is a specific case in which the provision of topical therapy cannot promote the healing process.³

Liquid smoke is a condensate that is indirectly burned at high temperatures and which can be produced from coconut shell.^{6,7} People in Indonesia do not only employ liquid smoke coconut shell as a natural preservative for various fish and its products, such as tuna, stingray, tofu and meatballs, but have also traditionally resorted to its use as a means of reducing pain and accelerating the healing process in cases of skin burns.⁸⁻¹¹

Liquid smoke coconut shell has been proven to have an analgesic effect. Previous research employing a writhing reflex method with 0.1% acetic acid induction confirmed that liquid smoke coconut shell is able to reduce this reflex in animal subjects due to acetic acid.¹² The analgesic effect is related to the phenolic compound contained in liquid smoke coconut shell.¹³ In cases of a diabetes mellitus condition, reactive oxygen species (ROS) and pro-inflammatory cytokines, such as tumor necrosis factor α (TNF- α), are increasingly formed. These interfere with the proliferation of fibroblasts by stimulating a fibroblast apoptotic process.¹⁴

Liquid smoke coconut shell can, in addition, accelerate healing by increasing the number of fibroblast cells in wounds.¹¹ Phenolic compounds in liquid smoke can bind to ROS, thus indicating reductions in TNF- α formation,¹⁵ resulting in decreased stimulation of the fibroblast apoptotic process.¹⁶ Fibroblasts represent the main element within collagen synthesis. An increased number of fibroblasts can stimulate the synthesis of collagen which plays an important role in tissue regeneration.¹⁷ This study aimed to analyze the increase in the amount of collagen in traumatic ulcer after the application of liquid smoke coconut shell in subjects suffering from diabetes.

MATERIALS AND METHODS

The shells used, identified as a species derived from *Cocos nucifera* L at Conversion Plant in Purwodadi, were derived from 5-6 month old coconuts obtained from a local market in Surabaya. Liquid smoke was obtained through a pyrolysis process conducted at 400⁰ C¹⁸ with a heating rate of 3.33⁰ C for 4.5 hours.

Liquid smoke coconut shell was made at the Research and Development Center of Forest Engineering and Forest Product Processing (PUSTEKOLAH). Coconut shells weighing 5 kg were cleaned and dried before being placed into a pyrolysis tool. The liquid smoke produced in this process was 51.18% and was then settled for 48 hours prior to filtering with Whatman 52 (Watman 52, 110 mm circle, Cat No 1452, GE Healthcare Life Science, Singapore). The purification process was conducted by means of distillation at 120⁰ C¹⁹ to produce 84% liquid smoke.

This research constituted a laboratory-based experimental investigation incorporating a post-test only-control group design and involving twenty-four, 2 month-old, male Wistar rats weighing 120–160gr. They were then intraperitoneally induced with alloxan monohydrate (alloxan monohydrate

A7413, Sigma Aldrich., St.Louise, MO, USA) at a dose of 150 mg/kg to stimulate a diabetic condition.²⁰ Preparation of alloxan was subsequently performed by dissolving 0.9 grams of alloxan monohydrate into 6ml of PBS to produce a concentrate of 150 mg/ml.²¹ The rats did not receive food or water for more than 12 hours overnight before the induction of alloxan occurred. The development of diabetes mellitus in these animals was confirmed seventy-two hours after the alloxan induction had taken place by a fasting glucose level of >200 mg/dl using GlucoDRTM (AGM-2100, Allmedicus, Korea).²²

After the animals had been confirmed as presenting the condition of diabetes mellitus (fasting glucose >200mg/dL), a traumatic ulcer sized 10mm was created along the labial fornix incisive inferior, using a round stainless steel blade.^{23,24} Prior to this traumatic ulcer being made, the animals were anesthetized using a ketamine/xylazine cocktail.²⁵ The traumatic ulcer was confirmed after 24 hours with the clinical appearance of a yellowish-white ulcer with a reddish edge.

At this point in the process, therapeutic topical applications of liquid smoke coconut shell and benzydamine hydrochloride 1.25% (Tantum Verde™, Soho, Jakarta, Indonesia) were performed on the traumatic ulcers of the twenty-four animals with the following distribution: a) six animals were treated with the topical application of liquid smoke coconut shell once a day for 5 days at a dose of 20 μ l/20gr weight; b) six animals were treated with the topical application of benzydamine hydrochloride once a day for 5 days at a dose of 20 μ l/20gr weight; c) six animals were treated with the topical application of liquid smoke coconut shell once a day for 7 days at a dose of 20 μ l/20gr weight; d) six animals were treated with the topical application of benzydamine hydrochloride once a day for 7 days at a dose of 20 μ l/20gr weight.

The rats were terminated, their labial fornix incisive inferior tissue was subjected to biopsy before a histological examination was performed using Masson Trichome (MT) staining to determine the amount of collagen present. The density of collagen expressed is a percentage (%) calculated by dividing the area of collagens (μ m²) observed by the total area of measurement using a light microscope (Nikon H600L microscope; Nikon, Japan) at a magnification of 200x (DS Fi2 300MP digital camera; Nikon, Japan, software digital imaging by Nikkon Image System, Nikon, Japan). The result obtained was the mean plus standard deviation (SD) value. An independent t-test then was performed to determine the differences in the amount of collagen present in each group (p <0.05).

RESULTS

Figure 1 depicts collagen present in traumatic ulcers in the labial fornix incisive inferior after the topical application of liquid smoke coconut shell and benzydamine hydrochloride for 5 and 7 days. The blue area indicates

the presence of collagen. The highest concentration of collagen was obtained after the topical application of liquid smoke coconut shell for 5 days. Meanwhile, the lowest amount of collagen was found after the topical application of benzydamine hydrochloride for 5 days. In general, the topical application of liquid smoke coconut shell-generated collagen was higher than for the topical application of benzydamine hydrochloride (Figure 2).

Furthermore, results of the Kolmogorov Smirnov test show that data in each observation group during the 5 and 7-day periods were normally distributed. An independent t-test was subsequently conducted to determine the difference between the topical application of liquid smoke coconut shell and that of benzydamine hydrochloride over 5 and 7 days.

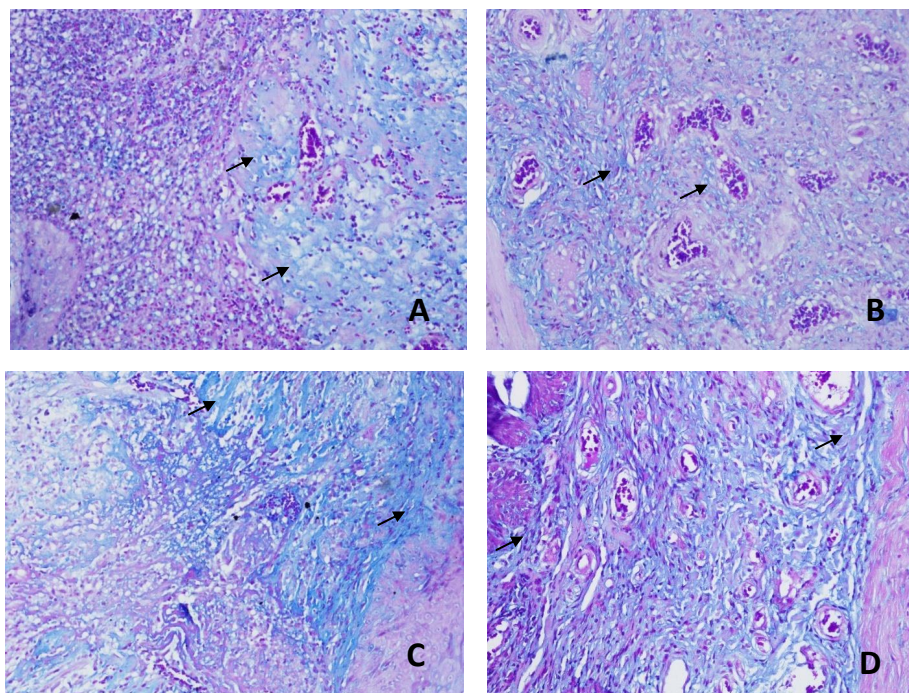


Figure 1. The pictures of collagen on the traumatic ulcers using Masson Trichome (MT) staining at a magnification of 200x (collagen appears as blue area, pointed by arrow). (A) The topical application of benzydamine hydrochloride for 5 days (the number of collagen was 68.8%); (B) The topical application of benzydamine hydrochloride for 7 days (the number of collagen was 76.2%); (C) The topical application of liquid smoke coconut shell for 5 days (the number of collagen was 83.4%); (D) The topical application of liquid smoke coconut shell for 7 days (the number of collagen was 81.6%).

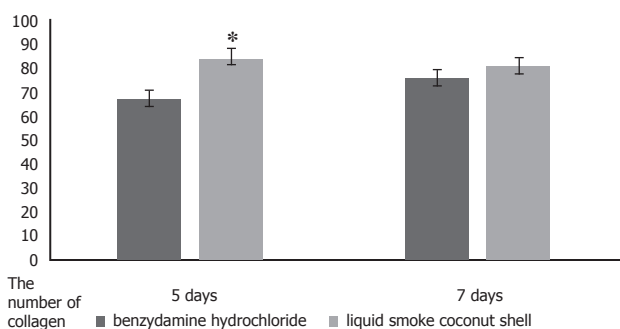


Figure 2. The mean number of collagen on the traumatic ulcers in each treatment group.

The results of the independent t-test indicated that the amount of collagen after the topical application of liquid smoke coconut shell for 5 days was significantly higher than that of benzydamine hydrochloride over 5 days ($p=0.006$).

Meanwhile, the amount of collagen after the topical application of liquid smoke coconut shell for a period of 7 days did not differ to any meaningful degree from that of benzydamine hydrochloride over 7 days ($p=0.156$).

DISCUSSION

The main complaint arising from instances of ulcers in the oral cavity is that of the resulting pain. Benzydamine hydrochloride is a nonsteroid anti inflammation drug (NSAID) whose analgesic, anti-inflammatory, and antimicrobial effects are superior to those of chlorhexidine.²⁶ It is considered to be an appropriate option as far as the control and reduction of pain in the case of oral mucositis is concerned.²⁷ The mechanism of benzydamine hydrochloride is inhibitive to prostaglandins and inflammatory cytokines.⁵ For this reason, this particular chemical was used for the purposes of the research described here due to its analgesic

effects which are derived from coconut shell.¹²

The liquid smoke coconut shell test on animals using acetic acid induction which leads to writhing reflex (a stretching or twisting movement due to contraction of the research sample animals' abdominal muscles) is one of methods used for peripheral analgesic screening, local peritoneal cell response, and prostaglandin pathway.²⁸ The analgesic effect is related to cyclooxygenase inhibition of the tissue resulting in a decrease in PGE2 production. This working mechanism is the same as that of NSAID.²⁹

In reality, the healing process of traumatic ulcers consists of three stages, namely inflammation, proliferation, and remodeling. The systemic condition of diabetes mellitus can affect the healing process.³⁰ Traumatic ulcers in cases of diabetes mellitus can precipitate a delayed healing process due to a prolonged inflammatory process marked by an increased pro-inflammatory cytokine, TNF- α .^{31,32} TNF- α is pro-inflammatory cytokine leading to inflammation and which demonstrates a close correlation with diabetes mellitus.³³ Increased TNF- α does not only occur at a systemic level, but also in the body's tissues. A previous piece of research shows that traumatic ulcers in alloxan-induced diabetic rats can significantly improve TNF- α expression.³¹

The topical application of liquid smoke is capable of reducing the production of TNF- α .¹⁵ The mechanism by which it does so is the inhibiting of reactive oxygen species (ROS), and signaling NF κ B for the production of TNF- α .^{15,34} Liquid smoke coconut shell contains a highly effective phenolic compound, namely; 2-methoxyphenols (guaiacol) at a proportion of 21.71%, phenol at 14.87%, and 4-Ethyl-2-methoxyphenol (EMP) at 3.97%.³⁵ These three compounds demonstrate antioxidant properties. ROS is a compound of free radicals derived from oxygen due to the high metabolism of glucose oxidation in the forms of superoxide (O₂), hydroxyl (OH), and peroxide (H₂O₂).³⁶ Superoxide (O₂) is one such free radical that plays a role in the activation of NF κ B signaling to produce TNF- α .³⁶

In addition, the mechanism of liquid smoke coconut shell in inhibiting the formation of ROS and TNF- α is related to the role of a phenolic compound. This forms part of a hydroxyl group (-OH) directly attached to the aromatic hydrocarbon ring that constitutes a biologically active side of the phenolic compound.³⁷ Phenol is highly reactive to the binding of ROS, while also possessing strong antioxidant properties which can inhibit the modulation of inflammatory mediator formation, such cytokine.³⁴ The resistance mechanism of these free radicals consists of binding superoxide radicals (O₂⁻) to the hydroxyl group (-OH) of phenol so that NF κ B activation decreases thereby inhibiting the production of TNF- α .^{34,38}

The proliferative stage of the healing process is, moreover, characterized by the proliferation of fibroblast and collagen synthesis.³⁰ The formation of granulation tissue at the proliferative stage of the wound healing process triggers fibroblasts to reduce collagenase so that the degradation process decreases. Furthermore, at this

stage, the fibroblasts also undergo apoptosis resulting in the granulation tissue being replaced by collagen.¹⁷ In cases of a hyperglycemic or diabetic condition, an increase in inflammatory mediators and advanced glycation end products (AGEs) occurs. AGEs are formed during the pathogenic process of diabetes, binding to the receptor of AGEs (RAGE). This bond can produce the formation of ROS in order to stimulate apoptotic processes through the activation mechanism of the pro-apoptotic transcription factor (FOXO1) in fibroblasts.^{14,39-41}

The topical application of liquid smoke over both 5 and 7-day periods produced a higher concentration of collagen than that resulting from benzydamine hydrochloride application during the same period (Figure 2). However, only the topical application of liquid smoke coconut shell for 5 days significantly improved the amount of collagen to a level higher than that of benzydamine hydrochloride ($p=0.006$) ($p<0.05$). The mechanism of increased collagen is associated with the inhibition of ROS and TNF- α formation as well a higher number of fibroblasts. Previous research shows that the topical application of liquid smoke coconut shell can decrease ROS formation and TNF- α production, as well as potentially increasing the number of fibroblast cells.^{14,15} Fibroblast constitutes the main element in collagen synthesis. The correlation between increased collagen and the higher number of fibroblasts is possibly due to a decreased apoptosis of fibroblast cells. Other past research into the condition of diabetes mellitus suggests that ROS and TNF- α plays a role in the stimulation of FOXO1 and caspase-3 producing an increase in the process of fibroblast apoptosis.^{14,16} Topical application of liquid smoke coconut shell over 7 days showed no significant difference in the formation of new collagen compared to that of benzydamine hydrochloride ($p=0.156$) ($p>0.05$). However, data showed that the number of collagen after the application of liquid smoke coconut shell was higher than for benzydamine hydrochloride (Figure 2). This condition can be explained by the liquid smoke coconut shell being capable of accelerating the proliferative phase (showing a higher concentration of collagen after application for 5 days) by accelerating the inflammatory phase in traumatic diabetic ulcer sites compared to benzydamine hydrochloride. As a result, in order to analyze and confirm how liquid smoke coconut shell affects the formation of collagen through a decreased inflammation process (TNF- α) and fibroblast apoptosis due to activation of FOXO1 and caspase-3, further research is required. It can be concluded that the topical application of liquid smoke coconut shell over 5 days increase the concentration of collagen in traumatic diabetes mellitus-related ulcers.

REFERENCES

1. Silva MFA, Barbosa KGN, Pereira JV, Bento PM, Godoy GP, Gomes DQ de C. Prevalence of oral mucosal lesions among patients with diabetes mellitus types 1 and 2. *An Bras Dermatol*. 2015; 90(1): 49–53.

2. Vasconcelos BC, Novaes M, Sandrini FAL, Maranhão Filho AW, Coimbra LS. Prevalence of oral mucosa lesions in diabetic patients: a preliminary study. *Braz J Otorhinolaryngol.* 2008; 74(3): 423–8.
3. Tripathi R, Tripathi K. Management of non healing oral ulcer in diabetic patient using topical application of epidermal growth factor : a case report. *Sch Acad J Biosci.* 2015; 3(8): 640–3.
4. Ali SA, Saudi HI. An expert system for the diagnosis and management of oral ulcers. *Tanta Dent J.* 2014; 11(1): 42–6.
5. Parashar A. Mouthwashes and their use in different oral conditions. *Sch J Dent Sci.* 2015; 2(2B): 186–91.
6. Wagiman FX, Ardiansyah A, Witjaksono. Activity of coconut-shell liquid smoke as an insecticide on the rice brown planthopper (*Nilaparvata lugens*). *ARPN J Agric Biol Sci.* 2014; 9(9): 293–6.
7. Zuraida I, Sukarno, Budijanto S. Antibacterial activity of coconut shell liquid smoke (CS-LS) and its application on fish ball preservation. *Int Food Res J.* 2011; 18(1): 405–10.
8. Saloko S, Darmadji P, Setiaji B, Pranoto Y. Antioxidative and antimicrobial activities of liquid smoke nanocapsules using chitosan and maltodextrin and its application on tuna fish preservation. *Food Biosci.* 2014; 7: 71–9.
9. Swastawati F, Susanto E, Cahyono B, Trilaksono WA. Sensory evaluation and chemical characteristics of smoked stingray (*dasyatis blekeery*) processed by using two different liquid smoke. *Int J Biosci Biochem Bioinformatic.* 2012; 2(3): 212–6.
10. Purba R, Suseno SH, Izaki AF, Muttaqin S. Application of liquid smoke and chitosan as natural preservatives for tofu and meatballs. *Int J Appl Sci Technol.* 2014; 4(2): 212–7.
11. Tarawan VM, Mantilidewi KI, Dhini IM, Radhiyanti PT, Sutedia E. Coconut shell liquid smoke promotes burn wound healing. *J Evid Based Complementary Altern Med.* 2016; 22(3): 436–40.
12. Surboyo MDC, Tiantiana T, Arundina I. Analgesic effect of coconut shell (*Cocos nucifera* L) liquid smoke on mice. *Dent J (Maj Ked Gigi).* 2012; 45(3): 156–60.
13. Murakami Y, Hirata A, Ito S, Shoji M, Tanaka S, Yasui T, Machino M, Fujisawa S. Re-evaluation of cyclooxygenase-2-inhibiting activity of vanillin and guaiacol in macrophages stimulated with lipopolysaccharide. *Anticancer Res.* 2007; 27(2): 801–7.
14. Sun K, Wang W, Wang C, Lao G, Liu D, Mai L, Yan L, Yang C, Ren M. AGEs trigger autophagy in diabetic skin tissues and fibroblasts. *Biochem Biophys Res Commun.* 2016; 471(3): 355–60.
15. Yang JY, Kang MY, Nam SH, Friedman M. Antidiabetic effects of rice hull smoke extract in alloxan-induced diabetic mice. *J Agric Food Chem.* 2012; 60(1): 87–94.
16. Siqueira MF, Li J, Chehab L, Desta T, Chino T, Krothpali N, Behl Y, Alikhani M, Yang J, Braesch C, Graves DT. Impaired wound healing in mouse models of diabetes is mediated by TNF- α dysregulation and associated with enhanced activation of forkhead box O1 (FOXO1). *Diabetologia.* 2010; 53(2): 378–88.
17. Tracy LE, Minasian R a., Cateson EJ. Extracellular matrix and dermal fibroblast function in the healing wound. *Adv Wound Care.* 2016; 5(3): 119–36.
18. Lombok JZ, Setiaji B, Trisunaryati W, Wijaya K. Effect of pyrolysis temperature and distillation on character of coconut shell liquid smoke. *Asian J Sci Technol.* 2014; 5(6): 320–5.
19. Desniorita D, Maryam M. The effect of adding liquid smoke powder to shelf life of sauce. *Int J Adv Sci Eng Inf Technol.* 2015; 5(6): 457–9.
20. Radenković M, Stojanović M, Prostran M. Experimental diabetes induced by alloxan and streptozotocin: The current state of the art. *J Pharmacol Toxicol Methods.* 2016; 78: 13–31.
21. Bako HY, Mohammad JS, Waziri PM, Bulus T, Gwarzo MY, Zubairu MM. Lipid profile of alloxan-induced diabetic wistar rats treated with methanolic extract of *adansonia digitata* fruit pulp. *Sci World J.* 2014; 9(2): 19–24.
22. Asgary S, Rafieian-Kopaei M, Shamsi F, Najafi S, Sahebkar A. Biochemical and histopathological study of the anti-hyperglycemic and anti-hyperlipidemic effects of cornelian cherry (*Cornus mas* L.) in alloxan-induced diabetic rats. *J Complement Integr Med.* 2014; 11(2): 63–9.
23. Hitomi S, Ono K, Miyano K, Ota Y, Uezono Y, Matoba M, Kuramitsu S, Yamaguchi K, Matsuo K, Seta Y, Harano N, Inenaga K. Novel methods of applying direct chemical and mechanical stimulation to the oral mucosa for traditional behavioral pain assays in conscious rats. *J Neurosci Methods.* 2015; 239: 162–9.
24. Kılıç Ç, Güleç Peker EG, Acartürk F, Kılıçaslan SMS, Çoşkun Cevher Ş. Investigation of the effects of local glutathione and chitosan administration on incisional oral mucosal wound healing in rabbits. *Colloids Surfaces B Biointerfaces.* 2013; 112: 499–507.
25. He S, Atkinson C, Qiao F, Chen X, Tomlinson S. Ketamine-xylazine-acepromazine compared with isoflurane for anesthesia during liver transplantation in rodents. *J Am Assoc Lab Anim Sci.* 2010; 49(1): 45–51.
26. Seshan H, Shanavas S, Ashwini S. Effective evaluation of benzydamine hydrochloride as a mouth wash in subjects with plaque induced gingival inflammation. *Int J Oral Heal Dent.* 2016; 2(3): 161–70.
27. Roopashri G, Jayanthi K, Guruprasad R. Efficacy of benzydamine hydrochloride, chlorhexidine, and povidone iodine in the treatment of oral mucositis among patients undergoing radiotherapy in head and neck malignancies: A drug trail. *Contemp Clin Dent.* 2011; 2(1): 8–12.
28. Ezeja MI, Ezeigbo II, Madubuike KG. Analgesic activity of the methanolic seed extract of *Buchholzia coriacea*. *Res J Pharm, Biol Chem Sci.* 2011; 2(1): 187–93.
29. Vinoth Prabhu V, Nalini G, Chidambaranathan N, Sudarshan Kisan S. Evaluation of anti inflammatory and analgesic activity of *Tridax procumbens* Linn against formalin, acetic acid and CFA induced pain models. *Int J Pharm Pharm Sci.* 2011; 3(2): 126–30.
30. Xu F, Zhang C, Graves DT. Abnormal cell responses and role of TNF- α in impaired diabetic wound healing. *Biomed Res Int.* 2013; 2013: 1–9.
31. Brizeno LAC, Assreyu AMS, Alves APNN, Sousa FB, de B. Silva PG, de Sousa SCOM, Lascane NAS, Evangelista JS-AM, Mota MRL. Delayed healing of oral mucosa in a diabetic rat model: Implication of TNF- α , IL-1 β and FGF-2. *Life Sci.* 2016; 155: 36–47.
32. Yamano S, Kuo WP, Sukotjo C. Downregulated gene expression of TGF- β s in diabetic oral wound healing. *J Cranio-Maxillofacial Surg.* 2013; 41(2): e42-8.
33. Donath MY, Dalmás É, Sauter NS, Böni-Schnetzler M. Inflammation in obesity and diabetes: islet dysfunction and therapeutic opportunity. *Cell Metab.* 2013; 17(6): 860–72.
34. Costa G, Francisco V, Lopes MC, Cruz MT, Batista MT. Intracellular signaling pathways modulated by phenolic compounds: application for new anti-inflammatory drugs discovery. *Curr Med Chem.* 2012; 19(18): 2876–900.
35. Budjanto S, Hasbullah R, Prabawati S, Setyadjit, Sukarno, Zuraida I. Identifikasi dan uji keamanan asap cair tempurung kelapa untuk produk pangan. *J Penelitian Pascapanen Pertanian.* 2008; 5(1): 32–40.
36. Matough FA, Budin SB, Hamid ZA, Alwahaibi N, Mohamed J. The role of oxidative stress and antioxidants in diabetic complications. *Sultan Qaboos Univ Med J.* 2012; 12(1): 5–18.
37. Gülçin I, Beydemir Ş. Phenolic compounds as antioxidants: carbonic anhydrase isoenzymes inhibitors. *Mini Rev Med Chem.* 2013; 13(3): 408–30.
38. Sikorski ZE, Sinkiewicz I. Smoking | Traditional. In: Dikeman M, Devine C, editors. *Encyclopedia of Meat Sciences.* 2nd ed. Elsevier; 2014. p. 321–7.
39. Erejuwa OO. Oxidative stress in diabetes mellitus: Is there a role for hypoglycemic drugs and/or antioxidants? In: Lushchak VI, Gospodaryov D V., editors. *Oxidative Stress and Diseases.* InTech; 2012. p. 217–46.
40. Garcia-Bailo B, El-Sohemy A, Haddad PS, Arora P, Benzaied F, Karmali M, Badawi A. Vitamins D, C, and E in the prevention of type 2 diabetes mellitus: modulation of inflammation and oxidative stress. *Biol Targets Ther.* 2011; 5: 7–19.
41. Desta T, Li J, Chino T, Graves DT. Altered fibroblast proliferation and apoptosis in diabetic gingival wounds. *J Dent Res.* 2010; 89(6): 609–14.