

Odontogenic maxillary sinusitis and oroantral communication: A case report

Jackson Dipankara¹, Gary Hadrian², Eddy³, Tansza Setiana Putri³, Astri Rinanti⁴, Thet Thet Swe⁵, Wiwiek Poedjiastoti¹

¹Department of Oral and Maxillofacial Surgery, Faculty of Dentistry, Universitas Trisakti, Jakarta, Indonesia

²Conservative Dentistry Resident, Faculty of Dentistry, Universitas Trisakti, Jakarta, Indonesia

³Department of Dental Material, Faculty of Dentistry, Universitas Trisakti, Jakarta, Indonesia

⁴Department of Environmental Engineering, Faculty of Landscape Architecture and Environmental Technology, Universitas Trisakti, Jakarta, Indonesia

⁵Department of Physics, University of Yangon, Kamayut, Yangon, Myanmar

ABSTRACT

Background: Odontogenic maxillary sinusitis (OMS) and oroantral communication (OAC) have been well recognized in oral and maxillofacial surgery. The treatment ranges from non-surgical treatment to surgical treatment. **Purpose:** This case report discusses the management of OMS and OAC through a non-surgical approach. **Case:** A female patient presented to our department after being referred from a different department. After informed consent was obtained, her tooth was extracted. Unfortunately, the maxillary sinus was exposed, and OMS was suspected after pus leakage occurred into the oral cavity prior to tooth extraction. The communication was found at the mesiobuccal region with a 3 mm diameter and distobuccal region with a 2 mm diameter. **Case management:** Due to the small size of the OAC, it was decided to close the communication using the figure-of-eight suture technique, and an absorbable gelatin sponge was placed inside the socket. Odontogenic maxillary sinusitis was treated with a combination of pharmacological therapy and dental therapy, including the removal of the source of infection and a prescription of antibiotics and nasal decongestant due to the OAC. Finally, the patient was educated about the sinus precaution step. **Conclusion:** Good healing of the lesion was noted in this report. Non-surgical treatment such as dental therapy and pharmacological therapy can, therefore, be considered to treat OMS. Closure of the OAC using a suture technique and a gelatin sponge can treat small-sized communication.

Keywords: odontogenic maxillary sinusitis; oroantral communication; non-surgical treatment

Article history: Received 19 December 2023; Revised 18 April 2024; Accepted 13 May 2024; Online 25 March 2025

Correspondence: Jackson Dipankara, Department of Oral and Maxillofacial Surgery, Faculty of Dentistry, Universitas Trisakti, Jakarta, Indonesia. Email: jackson@trisakti.ac.id

INTRODUCTION

The Schneiderian membrane (SM) can be affected by any disease arising from the dental or dentoalveolar structure and present as a pathologic disease in the maxillary sinus, known as odontogenic maxillary sinusitis (OMS).¹ Odontogenic infection with perforation of the SM or dentoalveolar surgery is the common etiology of OMS. In addition, the close anatomic proximity between the maxillary sinus and the posterior maxillary root apexes puts the dental disease at risk of spreading into the maxillary sinus.² Odontogenic maxillary sinusitis has been well recognized in oral and maxillofacial surgery. Patients with OMS may complain of nasal obstruction, nasal discharge, post-nasal drip, and frontal headache.³ The treatment options for OMS include

oral antibiotics, dental treatment, endoscopic sinus surgery alone, or a combination of the last two treatments. However, the appropriate management guidelines for treating OMS have not been established.⁴

The upper jaw alveolar bone can become thinner with age, and pneumatization of the sinus continues even after the eruption of the teeth, which may cause the apices of the posterior maxillary teeth to protrude into the sinus.² When the root apex is closer to the maxillary sinus, OMS will arise if the odontogenic infection perforates into the maxillary sinus, or oroantral communication (OAC) will occur if the tooth is extracted. Dental extraction is often carried out in daily practice, and some complications may occur.⁵ Oroantral communication is one of the common complications of dental extraction; it regularly occurs in

upper molar and premolar teeth.⁶ Oroantral communication is defined as a gap between the oral cavity and the sinus. If untreated, it can lead to an oroantral fistula (OAF). This complication is mostly iatrogenic following the extraction of maxillary posterior teeth.^{7,8} Other causes include intervention on cystic or tumoral pathologies, trauma, osteoradionecrosis, or infection.⁹ A study revealed that the mean distance between apices to the maxillary sinus of the upper second premolar was 2.72 mm for the right side and 2.83 mm for the right side; on the other hand, the mean distance for the upper first molar was 1.12 mm for the mesiobuccal root, 0.81 mm for the distobuccal root, and 0.44 mm for the palatal root.¹⁰

In daily practice, a critical evaluation of the anatomic relationship between apices and the maxillary sinus is crucial before a tooth extraction procedure.¹¹ Dental imaging, such as panoramic radiographs or 3D cone-beam computed tomography, can be used to determine the range.^{12,13} Nevertheless, when all preparation has been completed and OAC still develops, clinical decision-making regarding the closure of the OAC is required. Multiple factors need to be considered in determining the optimal strategy, such as the size of communication, the presence of infection, and the time of diagnosis.¹⁴

Usually, OMS and OAC occur separately. Odontogenic maxillary sinusitis accounts for a low prevalence of 10–12% of all cases of sinusitis.¹⁵ The uniqueness of this case

compared to others lies in the fact that OMS was found accidentally after the OAC occurred, with an initial tooth extraction treatment leading to dental treatment for the OMS condition. This case report aims to present a non-surgical approach with the addition of pharmacological therapy to aid the management of OMS and a suture technique combined with a gelatin sponge to close a small-sized OAC. In this case, the OMS and OAC were diagnosed due to the extraction of the upper first molar. The diagnosis was obtained based on patient history and a clinical examination, and it was confirmed with a periapical radiograph.

CASE

In April 2023, a 30-year-old female patient presented to postgraduate endodontics at the Faculty of Dentistry, Universitas Trisakti Teaching Dental Hospital, DKI Jakarta, Indonesia, for the treatment and evaluation of pain arising from the posterior upper jaw region. Extra-oral evaluation pain occurred when palpating the cheek near the maxillary sinus region, with negative edema and negative erythema detected around the cheek. During the intra-oral evaluation, a large disto-occlusal composite restoration was observed on the first molar tooth. There was also a positive bite test, positive percussion, negative erythema, and negative edema (Figure 1).

A periapical radiograph was conducted, and large a radiopaque was observed in the coronal portion and the pulp chamber. Radiopaque was observed in the distobuccal root canal and in 1/3 cervical part mesiobuccal root length. Mesiobuccal apices were observed protruding into the maxillary sinus, and distobuccal apices were observed in closer proximity to the maxillary sinus floor (Figure 2).

Based on the clinical and radiograph examination, root canal retreatment for the upper first molar was recommended to the patient. However, the patient refused the request to extract the tooth due to financial difficulties. Therefore, the patient was referred to the oral and maxillofacial surgery department. Before the treatment began, the patient was informed that OAC may occur due to the proximity of the root to the maxillary sinus.

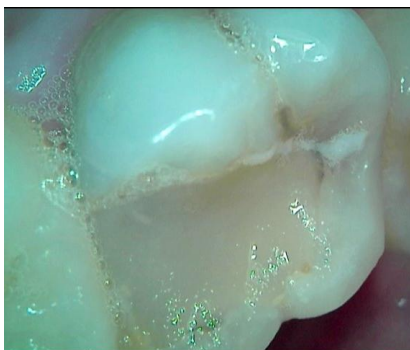


Figure 1. Clinical feature of upper first molar; a large disto-occlusal composite restoration was observed.

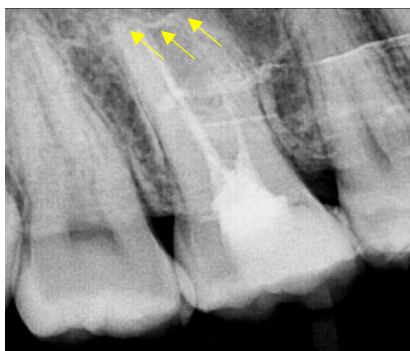


Figure 2. The upper first molar periapical radiograph; the yellow arrows show the proximity of the apices and maxillary sinus.

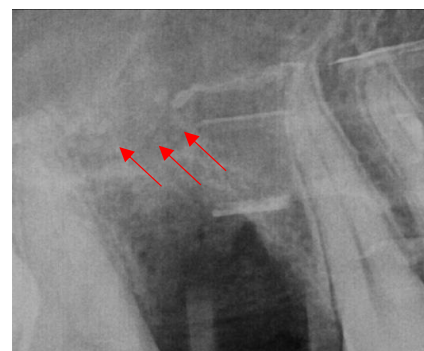


Figure 3. The red arrow showed the maxillary sinus floor defect.

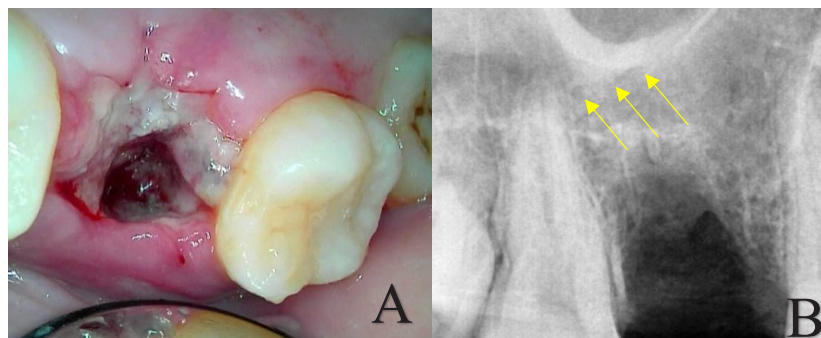


Figure 4. A. Seven days post socket extraction, post suture removal. B. The yellow arrows show the new epithelium generated at the maxillary sinus floor.

CASE MANAGEMENT

After obtaining informed consent, a dental extraction was performed using closed-method extraction. Unfortunately, the maxillary sinus was exposed (OAC mesiobuccal region 3 mm, distobuccal region 2 mm; the measurement was performed using a gelatin sponge, which was cut to the size of the communication and then measured with a caliper) as a result of dental extraction, and pus leakage into the oral cavity was observed. Due to suspected OMS, the patient was then questioned about any recent nasal obstruction. A periapical radiograph was subsequently taken, which revealed a bone defect that caused the right maxillary sinus to connect with the oral cavity (Figure 3). A diagnosis of OMS was confirmed by the presence of nasal obstruction, unilateral cheek pain by palpation, purulent leakage into the oral cavity from the maxillary sinus, and foul odor after the OAC occurred.

Non-surgical treatment was decided upon due to the small size of the OAC (2–3 mm). The figure-of-eight suture technique was performed to seal the socket with an absorbable gelatin sponge (Spongostan™). Thereafter, the patient was prescribed antibiotics (amoxicillin 500 mg with clavulanic acid 125 mg) to be taken three times a day, alongside a nasal decongestant to treat the OMS and an analgesic to be taken for five days. The patient was also informed of sinus precautions, which included the avoidance of vigorous exercise, closed-mouth sneezing, and closed-mouth nose blowing. The patient returned for a follow-up after seven days. Good healing was observed with the closure of the OAC, and no complications occurred during suture removal (Figure 4A). The periapical radiograph showed a maxillary sinus floor filled with new tissue (Figure 4B).

DISCUSSION

Causes of OMS include infectious causes, iatrogenic causes, odontogenic cysts with sinus involvement, traumatic injuries of the bone, and tumors.¹⁶ In this case, underfilled root canal treatment was noted at the mesiobuccal root. Therefore, endodontic infection may have developed, and bacteria may have spread to the adjacent tissue, which

activated a reaction from the SM epithelium.² A study found that the teeth causing the development of OMS most often are the first molar (35.6% of cases), followed by the second molar and second premolar (17.4% and 14.4% of cases, respectively).¹⁷ The first molar was most likely affected by endodontic pathology as a result of widespread belief, like the majority of Indonesian people, that the first molar that erupted at six years old is the primary tooth and that if the tooth decays, it will later be replaced by a permanent tooth. Therefore, untreated teeth can leave the oral cavity and become a source of infection.¹⁸

The treatment of OMS is divided into two stages, including non-surgical treatment and surgical sinus treatment. Non-surgical treatment consists of pharmacological treatment for the infection and resolution of dental lesions with dental treatment.¹⁹ Sometimes, non-surgical treatment is sufficient to solve the OMS, but occasionally, surgical sinus treatment is needed. However, the predictive factors that determine the failure of non-surgical treatment and, therefore, require surgical sinus treatment are still not fully understood.²⁰ Recent studies show that good healing is observed for OMS patients initially treated with dental extraction. This study suggests that OMS can be cured by dental treatment alone, without surgical sinus treatment. Nevertheless, when dental treatment is not effective for a patient with OMS, surgical sinus treatment may be considered.⁴ Our case, in line with the study mentioned above, shows that OMS heals after non-surgical treatment (pathological tooth extraction and pharmacological therapy).

Clinical observation is typically used to diagnose OAC. The patient gently blows air against their closed nostrils while keeping their mouth open. An inspection can be made using a Valsalva test. The presence of OAC is determined by the passage of air or blood at the postoperative site.²¹ A radiological examination with periapical/panoramic/cone-beam computed tomography of the OAC site is necessary to validate the clinical examination.⁹

Closure of the OAC is crucial to prevent the formation of an OAF. To date, several techniques are known to mitigate the complications of OAC (buccal/palatal alveolar flap, alongside the modification that presented to the surgeon), including various materials made from alloplastic (gold foil, gold plate, soft PMAA (polymethylmethacrylate),

and lyophilized collagen). Bone graft material has also been utilized (usually an autogenous bone graft). The most suitable technique is selected based on the presented case and the surgeon's experience.^{6,9}

Protocols for treating OAC should be followed. A rational approach depends on the size of the lesion. A lesion that is less than 2 mm in size will heal on its own, while a lesion larger than 2 mm requires surgical intervention. Treatments for this condition include suturing, soft tissue grafts/flap, metal plates, hemostatic gauze, and reimplantation of the molar. Allogeneous materials used for non-surgical treatments for OAC without flap closure have been explored, including absorbable polyglactin, prolamin occlusion gel, and fibrin glue. However, synthetic bone grafts are also known to be effective in treating OAC. Therefore, antibiotics and nasal decongestants are prescribed for pharmacological treatments.²² Surgical intervention is required if the defect diameter is larger than 5 mm or the lesion has been present for more than three weeks.¹⁴ In this case, the patient was treated with a non-surgical intervention due to the size of the lesion and the surgeon's experience. The treatment was performed immediately after the communication was confirmed, and epithelization was noted in the defect area a few weeks later. A study revealed that approximately 50% of OACs develop sinusitis after 48 hours if treated improperly, and 90% of sinusitis occurs after two weeks if untreated.²³

Postoperative care after OAC treatment includes prescribing a soft food diet and pharmacological therapy (analgesic and nasal decongestant); thus, vigorous exercise, closed-mouth sneezing, and closed-mouth nose blowing should be avoided.¹⁴ In conclusion, dental extraction and pharmacological treatment can be considered non-surgical therapies for OMS. Therefore, closure of an OAC as soon as possible is recommended to avoid the development of OAF and sinusitis.

ACKNOWLEDGEMENT

The authors wish to thank the Faculty of Dentistry, Universitas Trisakti Dental Hospital. In addition to consenting to the treatment, the patient has given permission for the case to be included in scientific publications.

REFERENCES

- Kim SM. Definition and management of odontogenic maxillary sinusitis. *Maxillofac Plast Reconstr Surg*. 2019; 41(1): 13.
- Hutomo FR, Kamadjaja DB, Danudiningrat CP, Bramantoro T, Amir MS. Dental infection is a major problem in Indonesia: Retrospective study in emergency department attached to Dental Hospital. *World J Dent*. 2024; 15(1): 48–52.
- Nurrachman AS, Rahman FUA, Sarifah N, Ghazali AB, Epsilawati L. Ostiomeatal complex inflammation with a rare ethmoid sinolith utilizing cone-beam computed tomography: A clinical and radiological approach to diagnosis. *Radiol Case Reports*. 2024; 19(1): 268–76.
- Yoshida H, Sakashita M, Adachi N, Matsuda S, Fujieda S, Yoshimura H. Relationship between infected tooth extraction and improvement of odontogenic maxillary sinusitis. *Laryngoscope Investig Otolaryngol*. 2022; 7(2): 335–41.
- Isnandar, Hanafiah OA, Lubis MF, Lubis LD, Pratiwi A, Erlangga YSY. The effect of an 8% cocoa bean extract gel on the healing of alveolar osteitis following tooth extraction in Wistar rats. *Dent J*. 2022; 55(1): 7–12.
- Chekaraou SM, Benjelloun L, EL Harti K. Management of oro-antral fistula: Two case reports and review. *Ann Med Surg*. 2021; 69: 102817.
- Konate M, Sarfi D, El Bouhairi M, Benyahya I. Management of oroantral fistulae and communications: our recommendations for routine practice. *Case Rep Dent*. 2021; 7592253.
- Mahdani FY, Nirwana I, Sunariani J. The decrease of fibroblasts and fibroblast growth factor-2 expressions as a result of X-ray irradiation on the tooth extraction socket in *Rattus novergicus*. *Dent J (Majalah Kedokt Gigi)*. 2015; 48(2): 94.
- Azzouzi A, Hallab L, Chbicheb S. Diagnosis and Management of oro-antral fistula: Case series and review. *Int J Surg Case Rep*. 2022; 97: 107436.
- Ragab MH, Abdalla AY, Sharaan ME-S. Location of the maxillary posterior tooth apices to the sinus floor in an Egyptian subpopulation using cone-beam computed tomography. *Iran Endod J*. 2022; 17(1): 7–12.
- Razumova S, Brago A, Howijieh A, Manvelyan A, Barakat H, Baykulova M. Evaluation of the relationship between the maxillary sinus floor and the root apices of the maxillary posterior teeth using cone-beam computed tomographic scanning. *J Conserv Dent*. 2019; 22(2): 139.
- Shaul Hameed K, Abd Elaleem E, Alasmari D. Radiographic evaluation of the anatomical relationship of maxillary sinus floor with maxillary posterior teeth apices in the population of Al-Qassim, Saudi Arabia, using cone beam computed tomography. *Saudi Dent J*. 2021; 33(7): 769–74.
- Aulianisa R, Widyaningrum R, Suryani IR, Shantiningsih RR, Mudjosemedi M. Comparison of maxillary sinus on radiograph among males and females. *Dent J*. 2021; 54(4): 200–4.
- Parvini P, Obreja K, Begic A, Schwarz F, Becker J, Sader R, Salti L. Decision-making in closure of oroantral communication and fistula. *Int J Implant Dent*. 2019; 5(1): 13.
- Sabatino L, Lopez MA, Di Giovanni S, Pierri M, Iafrati F, De Benedetto L, Moffa A, Casale M. Odontogenic sinusitis with oroantral communication and fistula management: role of regenerative surgery. *Medicina (B Aires)*. 2023; 59(5): 937.
- Martu C, Martu M-A, Maftei G-A, Diaconu-Popa DA, Radulescu L. Odontogenic sinusitis: from diagnosis to treatment possibilities-a narrative review of recent data. *Diagnostics (Basel, Switzerland)*. 2022; 12(7): 1600.
- Troeltzsch M, Pache C, Troeltzsch M, Kaeppler G, Ehrenfeld M, Otto S, Probst F. Etiology and clinical characteristics of symptomatic unilateral maxillary sinusitis: A review of 174 cases. *J Cranio-Maxillofac Surg*. 2015; 43(8): 1522–9.
- Dhanir N, Praja HA, Santoso RM, Ongkowitzo CW, Saraswati W. Conventional endodontic retreatment of persistent pain on previously treated tooth in an elderly patient: A case report. *Acta Med Philipp*. 2021; 55(8): 854–9.
- Novan Y I P, Primadi A, Mahfudz, Suharjono. Comparison of antibiotic prescriptions in adults and children with upper respiratory tract infections in Bangka Tengah primary health care centers. *J Basic Clin Physiol Pharmacol*. 2020; 30(6).
- Newsome HA, Poetker DM. Odontogenic sinusitis: current concepts in diagnosis and treatment. *Immunol Allergy Clin North Am*. 2020; 40(2): 361–9.
- Bhalla N, Sun F, Dym H. Management of oroantral communications. *Oral Maxillofac Surg Clin North Am*. 2021; 33(2): 249–62.
- Shahrour R, Shah P, Withana T, Jung J, Syed AZ. Oroantral communication, its causes, complications, treatments and radiographic features: A pictorial review. *Imaging Sci Dent*. 2021; 51(3): 307–11.
- Procacci P, Alfonsi F, Tonelli P, Selvaggi F, Menchini Fabris GB, Borgia V, De Santis D, Bertossi D, Nocini PF. Surgical treatment of oroantral communications. *J Craniofac Surg*. 2016; 27(5): 1190–6.