

## Potency of *Garcinia mangostana L* peel extract combined with demineralized freeze-dried bovine bone xenograft on IL-1 $\beta$ expression, osteoblasts, and osteoclasts in alveolar bone

Imam Safari Azhar,<sup>1</sup> Utari Kresnoadi,<sup>1</sup> and Retno Pudji Rahayu<sup>2</sup>

<sup>1</sup>Department of Prosthodontics

<sup>2</sup>Department of Oral Pathology

Faculty of Dental Medicine, Universitas Airlangga  
Surabaya - Indonesia

### ABSTRACT

**Background:** Alveolar bone plays an important role in supporting dentures. One socket preservation procedure is the application of bone graft to the tooth socket immediately after extraction. The administration of *Garcinia mangostana L* peel extract combined with demineralized freeze-dried bovine bone xenograft (DFDBBX) is assumed to decrease the number of osteoclast cells and IL-1 $\beta$  expressions, while also increasing that of osteoblast cells. **Purpose:** This study aimed to establish the potency of *Garcinia mangostana L* peel extract combined with DFDBBX on interleukin 1 $\beta$  expressions, osteoclast cells, and osteoblast cells during the preservation of tooth extraction sockets. **Methods:** This research constituted experimental laboratory-based research using 56 *Cavia cobaya*s as specimens with randomized factorial design (true experimental design). These subjects were divided into eight groups, given PEG, DFDBBX, mangosteen peel extract or a combination of mangosteen peel extract and DFDBBX, and subsequently anesthetized before their left mandibular incisors were extracted. Thereafter, the post-extraction sockets were treated with PEG, DFDBBX, mangosteen peel extract or a combination of mangosteen peel extract and DFDBBX. The sockets were examined by means of HE and immunohistochemical staining on days 7 and 30 after extraction. The data obtained was analyzed with a one-way ANOVA test. **Results:** The results of the one-way ANOVA test showed that the average number of osteoblasts, osteoclasts, and IL-1 $\beta$  expressions varied significantly between the groups. **Conclusion:** The combination of mangosteen peel extract and DFDBBX can potentially increase osteoblasts, while also decreasing osteoclasts and IL-1 $\beta$  expressions in the alveolar bones of *Cavia cobaya*.

**Keywords:** Alveolar bone; DFDBBX; Mangosteen peel extract; IL-1 $\beta$  expression; osteoblasts, osteoclasts

**Correspondence:** Imam Safari Azhar, Department of Prosthodontics, Faculty of Dental Medicine Universitas Airlangga. Jl. Mayjend. Prof. Dr. Moestopo no. 47 Surabaya 60132. E-mail: imam-safari-azhar@fkg.unair.ac.id

### INTRODUCTION

Interleukin 1 beta (IL-1 $\beta$ ) is a mediator in infection and injuries which is activated by monocytes and macrophages that are cells generally active in the inflammatory process.<sup>1</sup> The increased level of IL-1 $\beta$  in tissues can trigger inhibition of osteoblast differentiation resulting in a decrease in the number of osteoblasts leading, in turn, to the inhibition of bone formation. Such inhibition will then impede further treatment such as the prescribing of dentures. As a result, the suppression of IL-1 $\beta$  level in tissues is required in order to promote effective wound healing.<sup>2</sup>

The development of treatment evolves into the use of natural materials, one of which that has been studied and proven to be effective as an anti-inflammatory and antioxidant in the wound healing process being *Garcinia mangostana L* or mangosteen.<sup>3</sup> Previous research has shown that mouse cells with 5 mg of gamma-mangostin can inhibit the production of such cyclooxygenase-2 enzymes that reduce inflammation. Therefore, gamma-mangostin is demonstrated to have a superior anti-inflammatory effect.<sup>4</sup> Another previous piece of laboratory-based research analyzing the toxicity of mangosteen peel extract also

found that mangosteen extract at concentrations of 200 µg/ml, 300 µg/ml, 400 µg/ml, 500 µg/ml, 600 µg/ml, 700 µg/ml, and 800 µg/ml cannot cause toxicity to human gingival fibroblast cell cultures.<sup>5</sup>

On the other hand, preservation of tooth extraction sockets constitutes a surgical procedure intended to preserve the alveolar bone through the application of bone graft on sockets immediately after teeth have been extracted. This procedure aims to optimally maintain the bone and soft tissue post-tooth extraction.<sup>6,7</sup> In general, bone graft is used to support bone regeneration, severe bone defects caused by trauma or surgical procedures, repair of bone damage resulting from dental problems, post-extraction socket filling to maintain the height and width of the alveolar ridge, and immediate post-extraction alveolar ridge reconstruction.<sup>8</sup> One of the bone graft materials used is demineralized freeze-dried bovine bone xenograft (DFDBBX).

DFDBBX is one bone graft xenograft type derived from cows that is osteoconductive. Therefore, DFDBBX can play a role as a scaffold in new bone growth triggered by osteoblasts derived from the base of the post-extraction socket.<sup>9</sup> Moreover, DFDBBX is often used because of its osteoconducted inorganic matrix components which serve to provide scaffold for bone regeneration without being involved in bone formation itself. DFDBBX can also affect protein-inducing exposed bone during the demineralization process. Consequently, DFDBBX can be said to be both osteoinductive and osteoconductive.<sup>10</sup> For these reasons, an innovative material that can induce graft activity to accelerate bone formation is required.

This study aimed to analyze the effects of mangosteen peel extract at a concentration of 2% as an active substance combined with DFDBBX in IL-1 $\beta$  expressions, osteoclast cells and osteoblast cells in extraction sockets. Results of this study are expected to be used as a reference for the development of mangosteen peel extract as an alternative treatment combined with DFDBBX in accelerating alveolar bone formation.

## MATERIALS AND METHODS

The research reported here was approved with ethical clearance certificate number 067/HRECC.FODM/VI/2017 and constituted an experimental laboratory-based investigation featuring randomized factorial design (true experimental design). 56 *Cavia cobayas* were used as research subjects divided into eight sample groups each of which contained seven members. The inclusion criteria applied comprised the following: healthy, active male *Cavia cobayas* weighing 300-350 grams, aged 3-3.5 months with a normal appetite and skin and limb injury-free. Furthermore, the subjects were required to enjoy full use of their faculties, while exhibiting a normal gait and movement as well as a standard body temperature. They were subsequently kept in one location and placed on identical diets.

Mangosteen peel extract was produced through a process involving several stages. Mangosteen fruit was washed before being separated according to whether their peel was hard or soft. As the primary raw material, soft mangosteen peel was mashed in order to facilitate the extraction process carried out using a mixture of ethanol and water at a ratio of 1:2 as a solvent. Meanwhile, the ratio of materials extracted to solvent used was 1:4. The products of extraction were immersed for 24 hours and filtered to separate them from their dregs. To produce a combination of mangosteen peel extract and DFDBBX at a concentration of 2%, 0.5 gr of mangosteen peel extract was added to 0.5 gr of DFDBBX and 24 gr of PEG.

Thereafter, the *Cavia cobaya* subjects were anesthetized with a 20 mg/ 300 mg BB dose of ketamine administered intramuscularly.<sup>11</sup> Their left mandibular incisors were then cleansed of food scraps with a water spray and dried before being fully extracted (no root fracture) using a sterile needle holder. Extraction was performed by means of the same movement, direction and strength. The sockets were then irrigated with sterile aquade solution.

Post-extraction, the mangosteen peel extract + DFDBBX, mangosteen peel extract, DFDBBX, and PEG were introduced into the selected sockets with a syringe until they were full, at approximately +0.1 ml. All wound sites were then stitched with polyamide monofilament sewing thread, DS 12 3/8 c, 12 mm, 6/10 meth, 0.7 sterile Braun Aesculap.<sup>12</sup> At the next stage, the members of groups I, II, III, and IV were sacrificed on day 7, while those in groups V, VI, VII, and VIII were sacrificed on day 30 since deposition and bone resorption were assumed to occur in the sockets within four weeks. The subjects were sacrificed using ketamine in 100 mg/ml (Pfizer) at a dose of 0.2 ml. Their mandibula was then removed before burial.

Subsequent steps performed included dehydrating, clearing, infiltrating, and embedding. The most commonly used reagent for fixating histological specimens consisted of 10% neutral buffered formaldehyde. Each tissue was then cut to a thickness of 2-4 mm. The size of the tissues did not exceed the embedding of the cassette, so the reagent could flow around the tissues. The next stage is that of dehydrating aimed at removing water from the tissue and replacing it with paraffin. The dehydrating process was affected by washing the tissues with 70% ethanol for 15 minutes, 80% ethanol for 1 hour, 95% ethanol for 1 hour and, finally, ethanol (absolute) for one hour. This process was repeated twice. Clearing was subsequently conducted by immersing the tissues in xylol solution for one hour and then xylol for a further two hours. This process was then repeated.

After clearing had been completed, infiltration was carried out on the tissues. A piece of tissue was placed in the middle of the embedding cassette and closed. Impregnation was then carried out by reducing the tissues in paraffin at a temperature of 56-58<sup>0</sup> C for two hours, a process repeated three times. Thereafter, the tissues were planted in paraffin blocks. Liquid paraffin at a boiling point between 56 and 60<sup>0</sup>

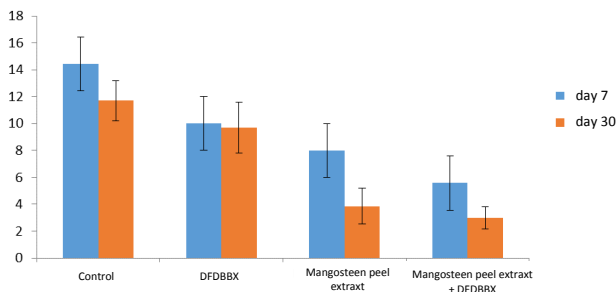
C was poured into a metal moulding device. An embedding cassette was then placed into the metal moulds with the surface of the tissue to be cut facing downwards. Before the liquid paraffin was poured into the moulds, the upper part was labeled. After the paraffin had hardened, the resulting blocks were removed from their metal molds.

At the next stage, the paraffin blocks were cut using a shear microtome of 4µm thickness. The results were collected using a brush, and then placed carefully on the surface of the waterbath at a fixed temperature of 56-58<sup>0</sup> C. The incision results were placed on a poly-L-lysine (preparat) microscope slide. The tissue-containing preparations were placed on a host plate at a minimum temperature of 30-35<sup>0</sup> C for 12 hours. The preparations were then ready for continuous immunohostical staining to facilitate observation of IL-1β expressions and HE staining to enable examination of osteoblast and osteoclast cells.

The number of IL-1β expressions, osteoblasts, and osteoclasts was observed and calculated using a light microscope at 400x magnification. The observed portion was calculated manually through 20 viewing fields. Based on the calculation results, a Levene’s test was conducted followed by a one-way ANOVA test intended to analyze any differences between groups. A Tukey HSD test was subsequently performed to establish the respective difference between each group.

**RESULTS**

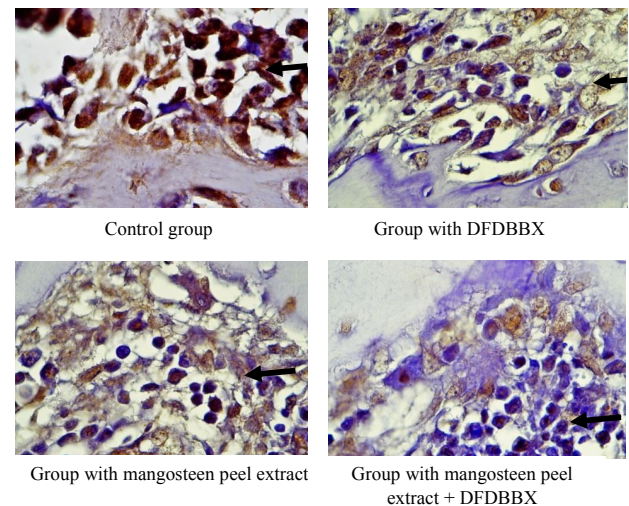
The results of this research indicated that the average number of IL-1β expressions was significantly different across the groups. There were differences in the average number of IL-1β expressions between the mangosteen peel extract, group, the DFBBX group, and the PEG group. The highest average number of IL-1β expressions was found in the control group on day 7, while the lowest was in the group with mangosteen peel extract + DFDBBX on day 30 (Figure 1). Figure 2 illustrates macrophage cells expressing IL-1β that observed using a light microscope.



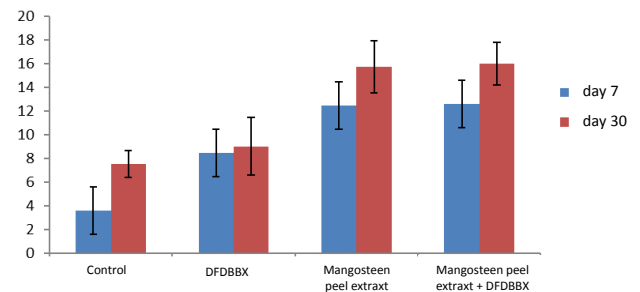
**Figure 1.** Mean and standard deviation of the number of IL-1β expressions on days 7 and 30.

Figure 3 illustrates that there were differences in the average number of osteoblasts between the group with mangosteen peel extract, the group with DFBBX, and the group with PEG. The highest number of osteoblasts was found in the group with mangosteen peel extract + DFDBBX on day 30, while the lowest one was in the control group with PEG on day 7. Figure 4 illustrates osteoblast cell seen with a light microscope on day 30.

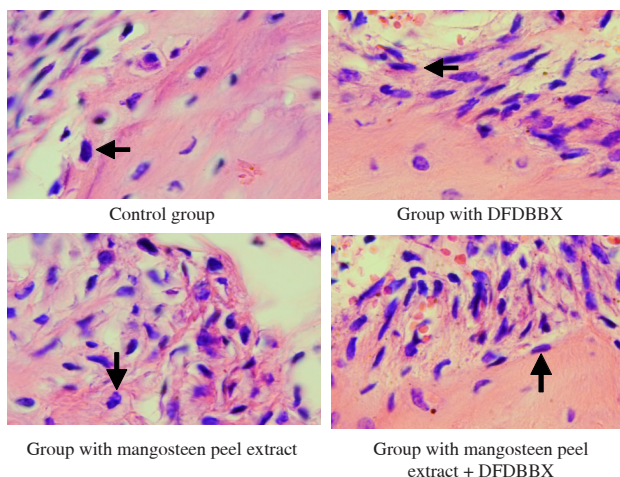
Figure 5 demonstrates that there were differences in the average number of osteoclasts between the group with mangosteen peel extract, the group with DFBBX, and the group with PEG. The highest number of osteoclasts was found in the control group with PEG on day 7, while the lowest one was in the group with mangosteen peel extract + DFDBBX on day 30. Figure 6 indicating osteoclast cells that observed using a light microscope on day 30.



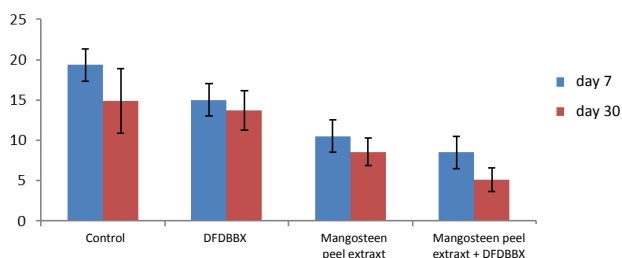
**Figure 2.** Microscopic pictures of IL-1β expressions in each treatment group during CPI examination, arrows indicating macrophage cells expressing IL 1β viewed through a light microscope at a magnification of 400x.



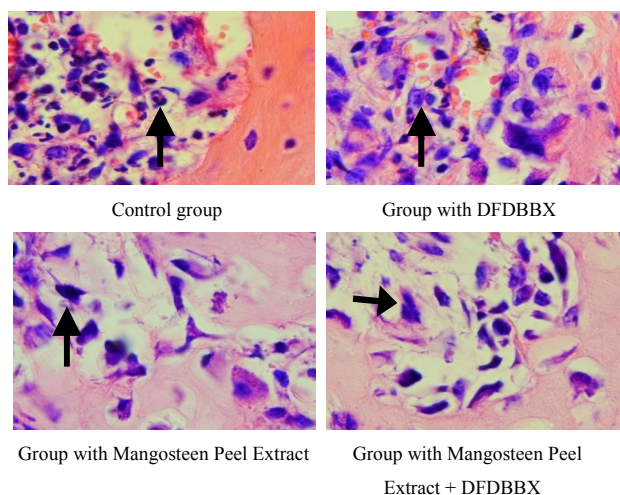
**Figure 3.** The graph of the mean and standard deviation of osteoblasts on days 7 and 30.



**Figure 4.** Microscopic pictures of osteoblast cells in each treatment group during HE examination, arrows indicating osteoblast cells seen with a light microscope with a magnification of 400x on day 30.



**Figure 5.** The graph of the mean and standard deviation of osteoclasts on days 7 and 30.



**Figure 6.** Microscopic pictures of osteoclast cells in each treatment group during HE examination, arrows indicating osteoclast cells seen with a light microscope with a magnification of 400x on day 30.

## DISCUSSION

Alveolar bone becomes atrophied after tooth extraction.<sup>13</sup> If it becomes severely atrophied, fitting dentures effectively becomes difficult. As a result, an attempt to recover the lost alveolar bone is required. Several types of materials such as autograft, allografts, xenografts, synthetic biomaterials, and osteoactive agents have been used widely as bone replacement.<sup>14</sup>

Furthermore, the application of bone graft to post-tooth extraction sockets is intended to stimulate new bone growth. In other words, the bone graft functions as a skeleton (scaffolds) and a matrix for the attachment and proliferation of osteoblasts. The bone graft was also expected to provide a skeletal structure for the development, maturation, and remodeling of the clot supporting bone formation. Therefore, bone graft materials should have biocompatibility and osteoconductivity properties for cellular attachment (proliferation and migration) as well as osteogenesis and osteoinduction.<sup>15</sup>

Moreover, bone graft materials should be more osteoinductive, stimulating the osteoprogenitor to differentiate into osteoblasts and form new bone.<sup>16</sup> Certain previous research has shown that the administration of DFDBBX and PEG can decrease the number of IL-1 $\beta$  expressions compared to those of the control group. The number of IL-1 $\beta$  expressions in the treatment group with the administration of DFDBBX was seen to differ significantly compared to the control group on the 7<sup>th</sup> and 30<sup>th</sup> days. DFDBBX is a kind of xenograft derived from cows. Xenograft has osteoconductive properties with porous internal surfaces to enable revascularization and osteoblast migration from the socket base supportive of osteogenesis.<sup>9</sup> Consequently, DFDBBX with its osteoconductive properties can play a role as a skeleton (scaffold) in new bone growth triggered by osteoblasts derived from the base of the post-tooth extraction socket.<sup>17</sup>

Mangosteen peel contains a number of pigments derived from two metabolites, namely  $\alpha$ -mangostin and  $\beta$ -mangostin. Mangosteen peel is also very beneficial to health since it contains numerous xanton compounds. In fact, such compounds contained there are 27 times greater than those contained in mangosteen flesh. For the human body, xanton compounds play a role as a strong anti-oxidant, anti-proliferation, anti-inflammatory, and anti-microbacterial.<sup>18</sup>

Similarly, within this research, the group treated with mangosteen peel extract had a significantly different number of IL-1 $\beta$  expressions on days 7 and 30 compared to that in the control group and the group treated with DFDBBX. This is because mangosteen peel extract is rich in xanton compounds, especially  $\alpha$ -mangostin and  $\gamma$ -mangostin, that can decrease TNF  $\alpha$ , IL-1 $\beta$ , IL-6, IL-8, MCP-1, and TLR-2 expressions. However,  $\gamma$ -mangostin

has greater anti-inflammatory properties than  $\alpha$ -mangostin. Moreover,  $\gamma$ -mangostin also can inhibit lipopolysaccharide (LPS) inducing activation of IKK, NF $\kappa$ B, and COX-2 transcriptions.<sup>17</sup> The inhibition of COX-2 can then decrease proinflammatory (IL-1, TNF  $\alpha$ ) cytokines directly or indirectly leading to the inhibition of osteoclast formation through RANKL. Consequently, there is no differentiation and formation of osteoclasts resulting in their decrease.

Nevertheless, within this research, the group receiving an administration of mangosteen peel extract combined with DFDBBX produced better results than either the group treated with mangosteen peel extract alone or the group treated with DFDBBX. It means that a combination of mangosteen peel extract and DFDBBX can execute a scaffold function as well as demonstrate anti-inflammatory properties. The results in the group treated with mangosteen peel extract combined with DFDBBX on day 7 were also different from those on day 30. The number of osteoblast cells on day 30 was higher than that on day 7. In contrast, osteoclast cells and IL-1 $\beta$  expressions on day 30 were fewer than those on day 7. Similarly, previous research showed that during weeks 4-6, alveolar bone is mostly filled with woven bone, followed by a bone maturation process in the next phase.<sup>19</sup>

It can be argued that the post-extraction socket preservation conducted in this research could reduce the occurrence of alveolar bone resorption, while accelerating the process of bone formation in the defective bone since the additional ingredients of mangosteen peel extract are indirectly osteoinductive. As a result, mangosteen peel extract can suppress NF $\kappa$ B activities leading to a proliferation of osteoblast progenitor cells. Consequently, it can be said that the combination of osteoconductive and osteoinductive properties of mangosteen peel extract mixed with DFDBBX can significantly reduce the number of IL-1 $\beta$  expressions. This combination can potentially be expected to further increase the success of socket preservation with the result that the dimension and volume of post-tooth extraction bone can be maintained. It can be concluded that mangosteen peel extract at a concentration of 2% as an active substance combined with DFDBBX demonstrates the potential to increase the number of osteoblast cells as well to decrease that of osteoclast cells and IL-1 $\beta$  expressions in the alveolar bone of *Cavia cobaya*.

## REFERENCES

1. Dinarello CA. Immunological and inflammatory functions of the interleukin-1 family. *Annu Rev Immunol.* 2009; 27(1): 519–50.
2. Lin FH, Chang JB, McGuire MH, Yee JA, Brigman BE. Biphasic effects of interleukin-1 $\beta$  on osteoblast differentiation in vitro. *J Orthop Res.* 2010; 28(7): 958–64.
3. Yatman E. Kulit buah manggis mengandung xanton yang berkhasiat tinggi. *Majalah Ilmiah Widya.* 2012; 29(324): 1–9.
4. Nakatani K, Nakahata N, Arakawa T, Yasuda H, Ohizumi Y. Inhibition of cyclooxygenase and prostaglandin E2 synthesis by  $\gamma$ -mangostin, a xanthone derivative in mangosteen, in C6 rat glioma cells1. *Biochem Pharmacol.* 2002; 63(1): 73–9.
5. Hayyu NS. Sitotoksitas ekstrak kulit garcinia mangostana linn terhadap sel fibroblas gingiva manusia (penelitian semi experimental laboratoris). Thesis. Surabaya: Universitas Airlangga; 2013. p. 43.
6. Peck MT, Marnewick J, Stephen L. Alveolar ridge preservation using leukocyte and platelet-rich fibrin: a report of a case. *Case Rep Dent.* 2011; 2011: 1–5.
7. Kotsakis G, Markou N, Chrepa V, Krompa V, Kotsakis A. Alveolar ridge preservation utilizing the “Socket-Plug” technique. *Int J Oral Implantol Clin Res.* 2012; 3(1): 24–30.
8. Albanese A, Licata ME, Polizzi B, Campisi G. Platelet-rich plasma (PRP) in dental and oral surgery: from the wound healing to bone regeneration. *Immun Ageing.* 2013; 10: 1–10.
9. Cohen RE, Alsawaiyan A, Wang B. Xenografts and periodontal regeneration. *J Orthod Endod.* 2015; 1(1): 1–6.
10. Al-Ghamdi H, Mokeem SA, Anil S. Current concepts in alveolar bone augmentation : a critical appraisal. *Saudi Dent J.* 2007; 19(2): 74–90.
11. Kusumawati D. Bersahabat dengan hewan coba. Yogyakarta: Gajdah Mada Press; 2004. p. 14, 26–28, 114.
12. Kresnoadi U. Toll like receptor 2 sebagai signaling pathway osteogenesis tulang alveoli yang diinduksi kombinasi aloe vera dan graft. Dissertation. Surabaya: Universitas Airlangga; 2012. p. 49–50.
13. Mezzomo LA, Shinkai RS, Mardas N, Donos N. Alveolar ridge preservation after dental extraction and before implant placement: a literature review. *Rev Odonto Ciência.* 2011; 26(1): 77–83.
14. Allegrini S, Koenig B, Allegrini MRF, Yoshimoto M, Gedrange T, Fanghaenel J, Lipski M. Alveolar ridge sockets preservation with bone grafting--review. *Ann Acad Med Stetin.* 2008; 54(1): 70–81.
15. Reynolds MA, Aichelmann-Reidy ME, Branch-Mays GL. Regeneration of periodontal tissue: bone replacement grafts. *Dent Clin North Am.* 2010; 54(1): 55–71.
16. Gupta R, Pandit N, Malik R, Sood S. Clinical and radiological evaluation of an osseous xenograft for the treatment of infrabony defects. *J Can Dent Assoc.* 2007; 73(6): 513.
17. Chaverri JP, Rodríguez NC, Ibarra MO, Rojas JMP. Medicinal properties of mangosteen (*Garcinia mangostana*). *Food Chem Toxicol.* 2008; 46(10): 3227–39.
18. Mardiana L. Ramuan & khasiat kulit manggis. Jakarta: Penebar Swadaya; 2011. p. 11-20.
19. Irinakis T. Rationale for socket preservation after extraction of a single-rooted tooth when planning for future implant placement. *J Can Dent Assoc.* 2006; 72(10): 917–22.