

## Case Report

# Unidentified angular recurrent ulceration responsive to antiviral therapy

Rahmi Amtha<sup>1</sup> and Siti Aliyah Pradono<sup>2</sup>

<sup>1</sup>Department of Oral Medicine, Faculty of Dentistry, Universitas Trisakti

<sup>2</sup>Department of Oral Medicine, Faculty of Dentistry, Universitas Indonesia  
Jakarta - Indonesia

### ABSTRACT

**Background:** Recurrent ulcer on angular area is usually called stomatitis angularis. It is caused by many factors such as vertical dimension reduce, vitamin B<sub>12</sub>, and immune system deficiency, *C. albicans* and staphylococcus involvement. Clinically is characterized by painful fissure with erythematous base without fever. **Purpose:** to describe an unidentified angular ulcer proceeded by recurrent ulcers with no response of topical therapy. **Case:** An 18-years old male came to Oral Medicine clinic in RSCM who complained of angular recurrent ulcers since 3 years ago which developed on skin and bleed easily on mouth opening. Patient had fever before the onset of ulcers. Large, painful, irregular ulcers covered by red crustae on angular area bilaterally. Patient has been treated with various drugs without improvement and lead to mouth opening limitation. Intra oral shows herpetiformtype of ulcer and swollen of gingival. **Case management:** Provisional diagnosis was established as viral infection thus acyclovir 200 mg five times daily for two weeks and topical anti inflammation gel were administered. Blood test for IgG/IgM of HSV1 and HSV2 were non reactive, however ulceration showed a remarkable improvement. The ulcers healed completely after next 2 weeks with acyclovir. **Conclusion:** The angular ulceration on above patient failed to fulfill the criteria of stomatitis angularis or herpes labialis lesion. However it showed a good response to antiviral. Therefore, unidentified angular ulceration was appointed, as the lesion might be triggered by other type of human herpes virus or types of virus that response to acyclovir.

**Key words:** Unidentified angular ulceration, anti inflammatory gel, acyclovir

### ABSTRAK

**Latar belakang:** ulser rekuren pada sudut mulut biasanya disebut stomatitis angularis. Kelainan ini disebabkan oleh banyak faktor seperti berkurangnya dimensi vertikal, defisiensi vitamin B12 dan sistem kekebalan tubuh, infeksi *C. albicans* serta staphylococcus. Secara klinis kelainan ini ditandai dengan fisur sakit pada sudut mulut dengan dasar eritematus tanpa disertai demam. **Tujuan:** Melaporkan kasus ulser sudut mulut rekuren yang tidak biasa, tanpa respon terhadap terapi topikal yang biasa diberikan. **Kasus:** Seorang laki-laki berusia 18 tahun datang ke klinik Penyakit Mulut RSCM dengan keluhan ulser rekuren pada sudut mulut yang meluas ke kulit sekitarnya sejak 3 tahun yang lalu. Ulser mudah berdarah saat pasien membuka mulut dan demam sebelum lesi timbul. Ulser membesar, bilateral, sakit, tepi tidak teratur, ditutupi oleh krusta merah. Pasien telah diobati dengan berbagai obat, namun tidak menunjukkan perbaikan. Intra oral tampak ulser jenis herpetiformis pada gingiva disertai dengan pembengkakan. **Tatalaksana kasus:** Diagnosis awal ditegakkan sebagai infeksi virus, oleh karena itu pasien diberikan acyclovir 200 mg lima kali sehari selama dua minggu dan gel anti radang topikal. Walaupun hasil darah IgG/IgM HSV1 dan HSV2 non reaktif, namun ulserasi menunjukkan penyembuhan yang luar biasa dengan anti virus yang diberikan. Ulser sembuh sempurna setelah pemakaian acyclovir 2 minggu berikutnya. **Kesimpulan:** ulserasi sudut mulut pada pasien di atas gagal memenuhi kriteria stomatitis angularis atau herpes labialis. Namun ulser menunjukkan respon yang amat baik terhadap antivirus. Diagnosis ditetapkan sebagai ulserasi sudut mulut yang tidak teridentifikasi. Kemungkinan lesi dipicu oleh virus herpes manusia jenis lain atau jenis virus yang memberikan respon terhadap asiklovir.

**Kata kunci:** Ulser sudut mulut tidak teridentifikasi, gel anti radang, asiklovir

Correspondence: Rahmi Amtha, c/o: Departemen Penyakit Mulut, Fakultas Kedokteran Gigi Universitas Trisakti. Jl. Kyai Tapa Grogol, Jakarta 11440, Indonesia. E-mail: rahmi.amtha@gmail.com

## INTRODUCTION

In daily practice, it is common to find an angular ulceration which can be triggered by many factors. Cheilitis is a broad term description of inflammation of the lip surface characterized by dry scaling and fissuring. There are some types of cheilitis such as atopic, angular, granulomatous, and actinic. Angular cheilitis is commonly seen and it specifically refers to cheilitis that radiates from the commissures or corners of the mouth. Other terms synonymous with angular cheilitis are *perlèche*, commissural cheilitis or angular stomatitis.<sup>1</sup> Clinically angular cheilitis appears as redness, ulceration and fissuring either unilateral or bilaterally at the corners of the mouth. It can appear alone or in conjunction with another form of candidiasis. Cheilitis angularis is a syndrome that involves several factors. The factors may play role individually or interchangeably. *Candida albicans*, *Staphylococcus aureus*, vertical dimension decreasing, vit B12 deficiency until immune deficiency (such as in HIV patients) are the established predisposing factors of angular cheilitis.<sup>2,3</sup>

However, occasionally the clinical manifestation shows unpathognomonic or unspecific clinical appearance with recurrent episodes and involves general conditions. This condition may make the provisional diagnosis sometimes difficult to be established and need further analysis to be able to treat the ulcers.

Ulceration at the corner of the mouth can be also as the manifestation of secondary herpes simplex infection. Typically, lesions are located on the vermillion border of the lips (herpes labialis, "cold sores" or "fever blister"), but may develop elsewhere in the mouth, on the face or inside the nose. The initial primary episode of herpes labialis occurs 1 to 26 days after inoculation and can appear as multiple blisters, 1–2 mm in size, associated with severe discomfort that lasts for 10 to 14 days.<sup>4</sup> Recurrent herpes labialis may affect about one-third of the population in the world, with episodes usually occurring from one to six times per year.<sup>4</sup> Orolabial recurrent herpesvirus infections can be triggered by stimuli such as fever, stress, cold, menstruation and ultraviolet radiation. Prodromal symptoms, including paraesthesia, tenderness, pain, burning sensation, tingling or itching sensation at the site of viral re-activation, arise in 46–60% of patients, and last for about 6 hours.<sup>5</sup>

Some autoimmune diseases such as erythema multiforme eruption is known to have an association with those who have history of recurrent herpes simplex infection. Erythema multiforme ranges from mild, severe to potentially life-threatening, and can involve acutely painful oral and labial ulcers.<sup>6</sup> Herpes simplex virus or other viral infections may precipitate erythema multiforme in the oral cavity.<sup>6–8</sup> Besides herpes simplex virus, there are some other human herpes viruses that may induce the oral ulcerations. Eight human herpesvirus species with distinct biological and clinical characteristics have been described: herpes simplex virus-1, herpes simplex virus-2, varicella-

zoster virus, Epstein–Barr virus, human cytomegalovirus, human herpesvirus-6, human herpesvirus-7 and human herpesvirus-8. Each herpesvirus subfamily maintains latent infection in specific cell population(s). Alpha herpesviruses exhibit a relatively short reproductive cycle, rapid lyses of infected cells and latency in sensory ganglia.<sup>9</sup>

Herpes simplex virus and cytomegalovirus are also reported to be potential pathogens of Behcet's syndrome ulcerations and Pemphigus vulgaris (an intraepidermal bullous disease which frequently involves large recalcitrant oral ulcers that precede the onset of skin lesions). Further research is needed to determine the extent to which viruses are involved in the oral ulcerogenesis of these and other systemic diseases, including Crohn's disease, ulcerative colitis and neutropenia.<sup>9</sup>

Epstein–Barr virus is involved in a great variety of cancers. The virus possesses factors capable of immortalizing B lymphocytes and epithelial cells, contains several potentially oncogenic antigens Epstein–Barr virus is associated with numerous lymphoid proliferations, including African Burkitt's lymphoma, classical Hodgkin's disease and recurrent periodontal disease.<sup>10</sup> The Epstein–Barr virus is present in two-thirds of AIDS-related lymphomas.<sup>11</sup> In the oral cavity, Epstein–Barr virus has been identified in Hodgkin's lymphoma, Burkitt's lymphoma, cyclosporine-related post-transplant lymphoproliferative disorder, post-transplant diffuse B-cell lymphoma, follicular lymphoid hyperplasia and plasmablastic lymphoma. Demographic, geographic and environmental factors may be important, as most studies showing a herpes viral association with oral tumors originate from Asian countries. Epstein–Barr virus-related nasopharyngeal carcinoma is known to occur with a high relative prevalence in natives of southern China and southeast Asia,<sup>12</sup> which may be a result of ethnically determined host–virus interactions or distinct Epstein–Barr genotypes predominating in some Asian populations.

Human cytomegalovirus genome and antigens have been identified in malignant tumors, including colon cancer, malignant glioblastoma. Cytomegalovirus is a member of the herpes family of DNA viruses. Herpes viruses are capable of latency after infection with an acute disease followed by an asymptomatic, quiescent state. Fifty to ninety five percent of adults have antibodies against CMV.<sup>13</sup> Infection with CMV in most immunocompetent hosts is asymptomatic but can present as a mononucleosis-like syndrome.<sup>14,15</sup> Cytomegalovirus is the virus most frequently isolated from people with AIDS. Ninety percent of patients with AIDS are infected with CMV, and disseminated CMV is found during autopsy in 93% of patients with AIDS. There are infrequent reports in the literature of cutaneous CMV infections. This may be because cutaneous CMV infections are uncommon or because making a diagnosis of CMV is difficult as a result of its multiple clinical presentations and subtle histopathological findings. Below is the case report of patient who have an recurrent angular ulceration which show a good improvement with antiviral agent.

## CASE

An eighteen years old man came to Oral Medicine clinic in Cipto Mangunkusumo Hospital to seek for treatment of recurrent angular ulcer since four days ago that developed to skin and bleed easily on mouth opening. Patient had slight fever before the onset of ulcers. Large, painful, irregular ulcer covered by red crustae found on bilateral angular area (Figure 1). Ulcers appear at least twice a year for last three years and always preceded by slight fever and herpetiformis type of ulcer on the commissure, upper and lower lip bilaterally, floor of the mouth and absence of skin ulcers. Upper and lower gingival showed pseudomembranous and slightly inflamed on interdental papilla (Figure 2). Ulcers healed ranging in 2-3 weeks. Patient has seen medical doctors and been given antibiotic, analgesic, some topical agent (triamcinolone acetone ointment, albotyl®, Chinese green traditional powder) and variety of mouthwashes. However, the ulcer showed no improvement and lead to a deeper and wider ulcer develop to surrounding skin, easy to bleed and cause limitation of mouth opening. Patient stays in dormitory with sufficient facilities and admits no psychological stress. Patient's diet pattern shows normal and likes to eat vegetables and drink a lot of water. Patient is non smoking and non alcohol drinking and use sodium lauryl sulfate dental paste. On the first day of visit, patient looked depressed due to unhealed ulcers and showed reluctant in replying question during anamnesis because of painful and bleeding ulcers. Hematological results (ordered by previous doctors) showed an increase in erythrocyte sedimentation rate (ESR), erythrocyte and hemoglobin and negative of Widal test.

Based on the history of slight fever and the herpetiform type of ulcer preceded the bilateral angular ulcer, two provisional diagnosis were established as herpes labialis or erythema multiforme triggered by herpes simplex infection (HAEM). Thus, acyclovirs 200 mg five times daily, hyaluronic acid gel and multivitamin once a day for two weeks were administered on the first visit. Blood test for IgG/IgM of HSV1 and HSV2 was ordered.

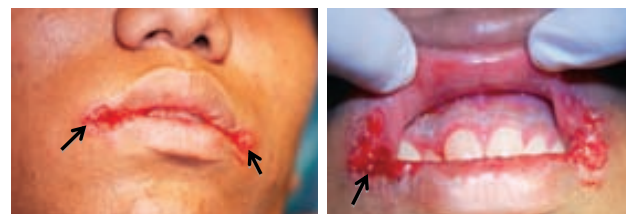Second visit (10 days later): After ten days patient came again for first control. The angular ulcers as well as the surrounding skin showed remarkable improvement (Figure 3). There was no red crustae seen over the lesion. Thin fissure with yellowish base and desquamation still obvious on the angular area without bleeding tendency every time patient opened his mouth. No other ulcers found on the upper, lower lips and floor of the mouth. The laboratory result showed IgG and IgM for HSV 1 and HSV 2 were no reactive/normal. Acyclovir 200 mg 5 times a day for 2 weeks and multivitamin once daily were continued. Fucidin ointment was administered three times a day to help recovery of the skin and prevent further involvement of bacteria (staphylococcus).

Third visit (15 days later): On the second control, patient looked satisfy that the angular ulcer has completely healed without skin desquamation, scar and soreness. The recovery

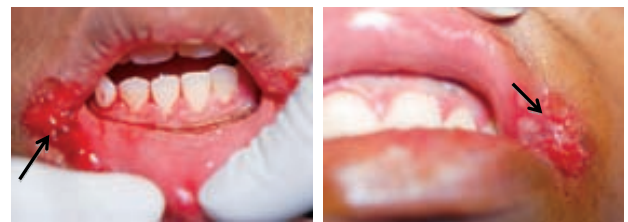tissue still looked pale compared to surrounding tissue; however follicle and sebaceous gland near commissural area showed well emerge (Figure 4). Therefore, patients was discharged with instruction to maintain the oral hygiene and have enough rest. The update interview is done by phone one month before this case is reported, showed that patient has no longer oral ulcers including at the angular area as before.

## DISCUSSION

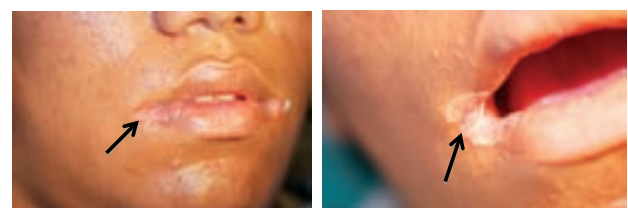By looking to the clinical manifestation, the angular ulcers in this case cannot be called as a classic cheilitis angularis as the manifestation expressed differently from



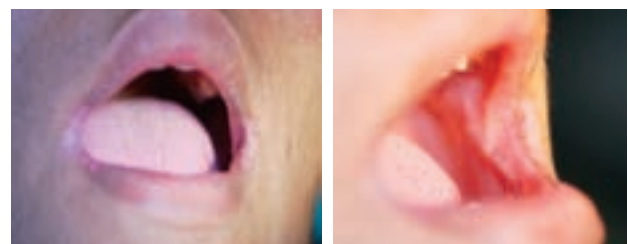
**Figure 1.** Bilateral chronic multiple angular ulcer covered with red crustae which easy to bleed (1<sup>st</sup> visit).



**Figure 2.** Slight edematous on upper and lower gingival, coexist with multiple minor ulcer on lower lip (1<sup>st</sup> visit).



**Figure 3.** Angular ulcers showed remarkable healing with still desquamation (2<sup>nd</sup> visit) the 10<sup>th</sup> days.



**Figure 4.** Complete healing of the angular ulcers bilaterally (3<sup>rd</sup> visit) the 15<sup>th</sup> days.

the common cheilitis angularis which caused by nutritional deficiencies, reduction of vertical dimension, microorganism involvement or allergy. Moreover, the background of recurrent onset with slight fever and do not response to any topical agent (anti ulcer) lead to possibility of recurrent ulcers due infection of human herpes virus, usually herpes simplex (HSV). The severe clinical appearance on the first visit, which showed angular ulcers with tendency of bleed easily coincide with multiple herpetiform ulcers in the mouth is also leading to further autoimmune disease which associated with herpes virus infection. HSV infection is a predominant preceding event in individuals that experience recurrent episodes of Erythema Multifome (EM), and such individuals are labeled as having herpes-associated erythema multifome (HAEM). However, usually the EM skin lesions characteristically occur 1 to 10 days after an episode of herpes labialis or genitalis, which did not appear in this case. It was strengthened by the laboratory results of HSV1 and HSV2 IgG/IgM that showed normal (non reactive). Weston<sup>16</sup> has reported that seven of 34 patients with HSV had detectable HSV DNA in peripheral blood mononuclear cells (PBMC) isolated, these subjects, however, did not develop EM. This led some researchers to believe that HSV is transported to skin lesions via the blood, but further noted that HSV-specific antibody responses and lymphocyte transformation responses to HSV antigens were similar in-group with or without HSV infection. Therefore, they found that HAEM occurred in spite of high immunity. Aurelian in year 2005 also reported that subjects with HAEM have detectable herpes simplex viral particles in their circulating peripheral blood CD34 cells and it presumably destined to be precursors of epidermal Langerhans cells.<sup>17</sup> The findings found that patients with recurrent herpes labialis or genitals but without episodes of EM did not have detectable virus in this type of cells.<sup>16</sup>

The administration of anti viral for the second visit was still prescribed eventhough the laboratory results of IgG/IgM of HSV showed negative. The reason was because the ulcers showed a significant improvement with the antiviral given. This is supported the findings by Weston<sup>16</sup> and Aurelian<sup>17</sup> regarding the non-specific antigen of HSV found in case of erythema multiforme. Therefore the positive response of the ulcers with anti viral agent is in consequence of possibility of triggered by one or more type of human herpes virus (HHV). As we know that HHV has 8 types and their oral manifestation has not been completely elaborated and studied. So that when IgM/IgG of HSV were tested showed negative. It is assumed that this type of virus did not induce the ulcers and it needs further study. Furthermore, It is probable that several of the risk factors for oral ulceration cause lesion outbreak by activating a latent viral infection that is not herpes simplex type of virus. Also, some viruses may induce oral ulceration when co-infecting with other viruses. In this case, stress, nutritional deficiency and lack of rest can be the risk factors, even though there was not a specific test done to describe

that condition and patient did not admit that he was under pressure in his dorm life of style.

Widespread and multiple oral ulcers should raise the suspicion of skin disease or vasculitis, particularly if associated with mucocutaneous lesions (e.g. blistering, hyperkeratosis or scarring); and ulcers limited to the commissures (angular cheilitis) have typically a microbial basis (often a candida or staphylococcal infection).

History of recurrent angular ulcers and herpetiform ulcerations with fever is the basic of decision of prescribing the anti viral in this patient, besides increasing immune system by instruction of enough rest and multivitamin. The response of using corticosteroid (triamcinolone ointment) showed no improvement of the lesions and actually a contraindication for viral infection except for bell's palsy type of case with background of HSV reactivation. There is no harmful side effect of giving patient of standard dosage of anti viral as the empirical treatment. As mentioned in previous research that one of eight people showed detectable particle of human herpes virus in their peripheral blood cells but not as the complete genome of the viral, so that the IgG/IgM found no reactive.<sup>16,17</sup> Moreover, all the human herpes virus has showed positive response to anti viral acyclovir.

The fucidin ointment is an optional treatment to eliminate the involvement of staphylococcus infection on the skin surrounding ulcers. Some clinical trial also showed that it helps to regenerate the skin texture damage. In this case, recurrent angular ulcers showed severe ulcers until involve deeper surrounding dermis.

Finally, as clinicians sometime it is difficult to determine one fixed diagnosis as the clinical appearance of oral ulcers is often not pathognomonic, and several different ulcerogenic conditions of the mouth may currently be lumped together. The best approach can be done is to review the basic pathogenesis of the disease to establish the best treatment.

Angular cheilitis terminology has a broad meaning and approach of treatment. The variety of clinical appearance and history of onset may lead to some diagnosis which is caused by viral infection. The angular ulceration on above patient failed to fulfill the criteria of stomatitis angularis or herpes labialis lesion. However it showed a good response to antiviral. Therefore, unidentified angular ulceration was appointed; as the lesion might be triggered by other type of human herpes virus or types of virus that response to acyclovir.

## REFERENCES

1. Skinner N, Jessie A, Junker, Flake D. What is angular cheilitis. *J Fam Pract* 2005; 54(5): 470-1.
2. Scully C. *Oral and maxillofacial medicine*. 2<sup>nd</sup> ed. Edinburgh: Churchill Livingstone; 2008; 147-9.
3. Dangi YS, Soni ML, Namdeo KP. Oral candidiasis: A Review. *Int J Pharm Pharm Sci* 2010; 2(4): 36-1.

4. Cernik C, Gallina K, Brodell RT. The treatment of herpes simplex infections: an evidence-based review. *Arch Intern Med* 2008; 168(11): 1137–44.
5. Arduino PG, Porter SR. Herpes simplex virus type 1 infection: overview on relevant clinico-pathological features. *J Oral Pathol Med* 2008; 37(2): 107–21.
6. Al-Johani KA, Fedele S, Porter SR. Erythema multiforme and related disorders. *Oral Surg Oral Med Oral Pathol Oral Radiol Endod* 2007; 103(50): 642–54.
7. Sinha A, Chander J, Natarajan S. Erythema multiforme presenting as chronic oral ulceration due to unrecognised herpes simplex virus infection. *Clin Exp Dermatol* 2006; 31(5): 737–8.
8. Wanner M, Pol-Rodriguez M, Hinds G, Hutt C, Husain S, Grossman ME. Persistent erythema multiforme and CMV infection. *J Drugs Dermatol* 2007; 6(3): 333–6.
9. Slots J. Oral Viral Infections of Adults. *Periodontol* 2000, 2009; 49: 60–86.
10. Lin YL, Li M. Human Cytomegalovirus and Epstein-Barr virus inhibit oral bacteria-induced macrophage activation and phagocytosis. *Oral Microbiol Immunol* 2009; 24(3): 243–8.
11. Saccoccio FM, Sauer AL, Cui X, Armstrong AE, Habib ESE, Johnson DC, Ryckman BJ, Klingelhutz AJ, Adler SP, McVoy MA. Peptides from cytomegalovirus UL130 and UL131 proteins induce high titer antibodies that block viral entry into mucosal epithelial cells. *Vaccine* 2011; 29(15): 2705–11.
12. Chang ET, Adami HO. The enigmatic epidemiology of nasopharyngeal carcinoma. *Cancer Epidemiol Biomarkers Prev* 2006; 15(10): 1765–77.
13. Tessme MS, Reilly AC, Brossay L. Salivary Gland NK Cells Are Phenotypically and Functionally Unique. *PLoS Pathog* 2011; 7(1): e1001254.
14. Lambert EM, Strasswimmer J, Lazova R, Antaya RJ. Cytomegalovirus ulcer. *Arch Dermatol* 2004; 140(10): 1199–201.
15. Juckem LK, Boehme KW, Feire AL, Compton T. Differential initiation of innate immune responses induced by human cytomegalovirus entry into fibroblast cells. *J Immunol* 2008; 180(7): 4965–77.
16. Weston WL. Herpes-associated erythema multiforme. *J Invest Derm* 2005; 124(6): 15–6.
17. Aurelian L, Ono F, Sharma BK, Smith CC, Burnett JW. CD34 cells in the peripheral blood transport Herpes Simplex Virus (HSV) DNA fragments to the skin of patients with erythema multiforme (HAEM). *J Invest Dermatol* 2005; 124(6): 1215–24.
18. Chen J, Abatangelo G. Functions of hyaluronan in wound repair. *Wound Repair Regen* 1999; 7(2): 79–89.