

## Case Report

## The management of chronic traumatic ulcer in oral cavity

**Maharani Laillyza Apriasari**

Department of Oral Medicine

Study Program of Dentistry, Faculty of Medicine, Lambung Mangkurat University

Kalimantan Selatan - Indonesia

**ABSTRACT**

**Background:** The traumatic ulcer is one of the most common oral mucosal lesions. The etiology of traumatic ulcer may result from mechanical trauma, as well as chemical, electrical, or thermal stimulus, may also be involved in addition, fractured, malposed, or malformed teeth. The clinical manifestation of traumatic ulcer are ulcer, have a yellowish floor, fibrinous center, red and inflammatory margin without induration. **Purpose:** The purpose of this case report is to present how to manage the patient with the chronic traumatic ulcer in oral cavity. **Case:** This case report is about the patient with chronic ulcer in oral cavity. Intra oral examination showed on the right tongue margin appeared the major ulcer, single, diameter 1,5 cm, pain, white color, induration and irregular margin around the ulcer. The patient had been suffering it for 5 months. She had come to a lot of dentist and the oral maxillofacial surgery, but they could not heal the ulcer. The dental occlusion of the patient, especially 17 and 47 then 15 and 45 teeth was looked bitten the right tongue. It underlied to get the clinical diagnosis as the chronic traumatic ulcer. **Case management:** The main therapy of traumatic ulcer is eliminating the etiology factor, so that decided to do teeth extraction 45 and 47 that was looked linguversion position on 45 degrees. Before doing the teeth extraction, the patient was referred to take complete blood count (CBC), blood glucose examination and biopsy. The monitoring of the ulcer must be done until 2 weeks after the teeth extraction. If the lesion was persistent, it is suspected as malignancy. **Conclusion:** It can be concluded that the main management of chronic traumatic ulcer in oral cavity is removing the etiology factors. If the ulcer is still persistent after 2 weeks from the etiology factor had been removing, it is suspected as the malignancy that is needed biopsy examination to get the final diagnosis.

**Key words:** Biopsy, chronic, management, traumatic ulcer

**ABSTRAK**

**Latar belakang:** Ulkus traumatikus adalah salah satu lesi pada mukosa mulut yang sering terjadi. Penyebab ulkus traumatikus adalah adanya trauma mekanik, seperti kimia, elektrik atau suhu, selain itu dapat pula terjadi karena fraktur, malposisi atau malformasi gigi. Manifestasi klinis dari ulkus traumatikus adalah ulser, dasar berwarna kuning, pada bagian tengah tampak fibrin, pinggiran berwarna merah dan mengalami peradangan tanpa adanya indurasi. **Tujuan:** Tujuan dari laporan kasus ini adalah untuk melaporkan bagaimana penatalaksanaan pasien dengan ulkus traumatikus kronis pada rongga mulut. **Kasus:** Kasus ini melaporkan tentang ulser kronis yang terjadi pada rongga mulut. Pemeriksaan pada rongga mulut menunjukkan pada pinggir lidah kanan tampak ulser mayor, tunggal, diameter 1,5 cm, sakit, berwarna putih, pinggiran sekitarnya tampak indurasi dan tidak teratur. Ulser terjadi selama 5 bulan. Pasien mengunjungi banyak dokter gigi dan spesialis bedah mulut, tetapi ulser tidak dapat disembuhkan. Pada saat pasien oklusi, pada gigi, 17 dengan 47 serta gigi 15 dengan 45 tampak lidah sebelah kanan tergigit. Hal ini yang mendasari diagnosis sementara adalah ulkus traumatikus kronis. **Tatalaksana kasus:** Penanganan utama dari ulkus traumatikus adalah menghilangkan faktor penyebab, oleh sebab itu dilakukan ekstraksi pada gigi 45 dan 47 yang terlihat posisi linguoversi 45 derajat. Sebelum gigi-gigi tersebut diekstraksi, pasien dirujuk untuk melakukan pemeriksaan darah lengkap, gula darah dan biopsi. Ulser harus tetap dimonitor sampai 2 minggu pasca ekstraksi. Jika lesi menetap, maka ini diduga Squamous Cell Crsinoma. **Kesimpulan:** Dapat disimpulkan bahwa penatalaksanaan utama dari ulkus traumatikus kronis pada rongga mulut adalah dengan menghilangkan faktor penyebab. Ulser yang persisten setelah 2 minggu setelah faktor penyebab dihilangkan, maka diduga suatu keganasan yang perlu pemeriksaan biopsi untuk menegakkan diagnosis akhir.

**Kata kunci:** Biopsi, kronis, penatalaksanaan, ulkus traumatikus

*Correspondence:* Maharani Laillyza Apriasari, Program Studi Kedokteran Gigi, Fakultas Kedokteran Gigi Universitas Lambung Mangkurat. Jl. Veteran 128 B Banjarmasin, Kalimantan Selatan, Indonesia. E-mail: rany.rakey@gmail.com

## INTRODUCTION

Traumatic ulcer is one of the most common mucosal lesions in oral medicine. The lesion injuries involving the oral cavity may typically lead to the formation of surface ulcerations. The injuries may result from events such as accidentally biting oneself while talking, sleeping, or secondary to mastication. Other forms of mechanical trauma, as well as chemical, electrical, or thermal stimulus, may also be involved in addition, fractured, caries, malposed, or malformed teeth. Poorly maintained and ill-fitting dental prosthetic appliances may also cause trauma.<sup>1</sup>

Traumatic ulcers are usually caused by a denture and often seen in the buccal or lingual sulcus. The etiology of traumatic ulcers is the accidental injury. The clinical manifestation of uler traumatic are tender to painful, have a yellowish floor, fibrinous center, red and inflammatory margin, and no induration. If caused by the sharp edge of a broken-down tooth, they are usually on the tongue or buccal mucosa. Occasionally, a large ulcer is caused by biting the cheek after a dental local anaesthetic. During the healing phase they frequently develop a 'keratotic halo'.<sup>2-4</sup>

The differential diagnosis of the traumatic ulcer are recurrent aphthous stomatitis, squamous cell carcinoma, and tuberculosis ulcer.<sup>1,5</sup> The diagnosis of traumatic ulcer is usually based on the history and the clinical examination. If the ulcer is still persistent after 2 weeks or the ulcer clinical manifestation suspects the malignancy so that must be done a biopsy that is necessary to rule out malignancy.<sup>1,2,5</sup> This case report show the importance of biopsy to help the final diagnosis of chronic ulcer. She had been suffering it for 5 months and had been visiting a lot of doctors as dentist, the oral and maxillofacial surgeon, the neurologist, and the oto laryngologist. Actually none of them asked her to do biopsy, although she had been suffering the chronic ulcer more than 1 month. All of them could not heal the chronic ulcer.

## CASE

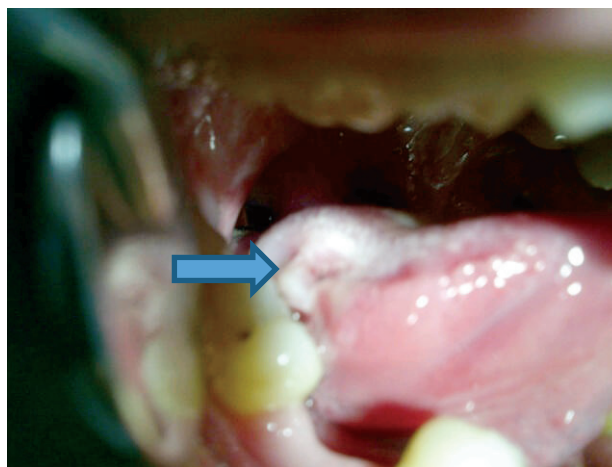
The patient, woman, 33 years, had been suffering stomatitis on right of tongue margin since 5 months ago. She was difficult for talking and eating which made the loss body weight until 10 kg. The ulcer had never been cured, pain, numb sensation of the tongue and difficult speaking. The patient had been given 36% policresulen and 0.1% triamcinolone acetonide, but it was not healed. She decided to see the spesialist of oral maxillofacial surgery whom grinding the tooth 47. The tooth was on linguoversion position until 45 degrees that suspected as etiology of the traumatic ulcer. She was given the oral drugs by the dentist as amoxycillin 500 mg three times a day, mefenamic acid 500 mg three times a day, dexamethason 0.5 mg three times

a day and the topical drug as 0.1% triamcinolone acetonide, oral base three times a day. Actually she was still not cured, so that she decided to visit the oral and maxillofacial surgeon, the oto laryngologist and the neurologist, but they referred to the dentist. Finally all of them could not heal the ulcer.

## CASE MANAGEMENT

On the first visit, the extra oral of clinical examination showed the right submandibula lymphenode was palpable, chewy, swelling and not pain. The intra oral examination showed on the right tongue margin appeared the major ulcer, single, diameter 1.5 cm, pain, white color, induration and irreguler margin around the ulcer (Figure 1). The ulcer was bitten by between teeth 16 and 17 with 47 on occlusion position (Figure 2). Based on this condition, this case was diagnosed as chronic ulcer traumatic. The differential diagnosis was squamous cell carcinoma, it was caused the induration and irreguler margin around the ulcer. For getting the final diagnosis, the patient was reffered to undertake biopsy, complete blood count (CBC) and blood glucose examination. The therapy had been given to the patient was the topical drugs as allovera gargle. The patient was asked to control after she got the result of biopsy, blood glucose examination and CBC.

On visit 2 (1 day after visit 1), the result of CBC showed patient was not severe anemia and normal of blood glucose. The biopsy result from ulcer on the right tongue margin showed distribution of epithel squamous cell with round nucleus, spread cytoplasma, not rough chromatin and reguler nucleus membran. It was meant there was not the malignancy cell. Based on the biopsy result, the final diagnosis was the chronic ulcer traumatic. The patient was

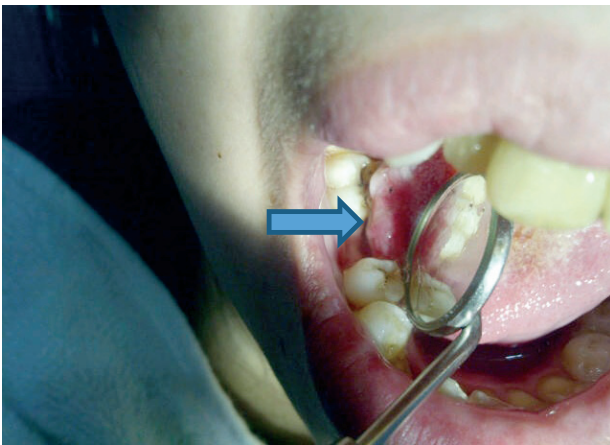


**Figure 1.** Chronic major ulcer, single, diameter 1.5 cm, tender to painful, white, elevated periphery.

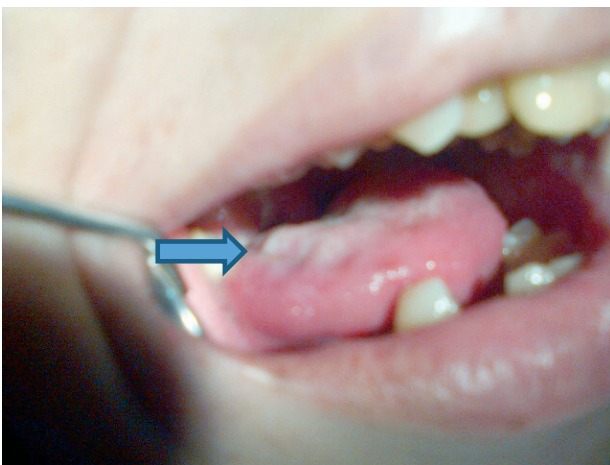
asked to do teeth 45 and 47 extraction. The therapy was oral drugs as cefadroxil 500 mg 2 x 1, calium diclofenac 50 mg 3 x 1 and multivitamin 1 x 1 for 5 days.

On visit 3 (3 days after visit 1), the patient complained that her lips and tongue were pain and chapped after drinking the drugs. The intra oral examination showed lips and tongue were erosion, erythema, little bleeding, and pain. The clinical diagnosis was the allergic stomatitis because of consume cefadroxil 500 mg. The patient asked to change cefadroxil 500 mg with amoxicillin 500 mg, then continuing to consume calium diclofenac 50 mg 3 x 1 and multivitamin for 5 days. For curing the allergy, the patient was given cetirizine HCl 10 mg 1 x 1 for 5 days.

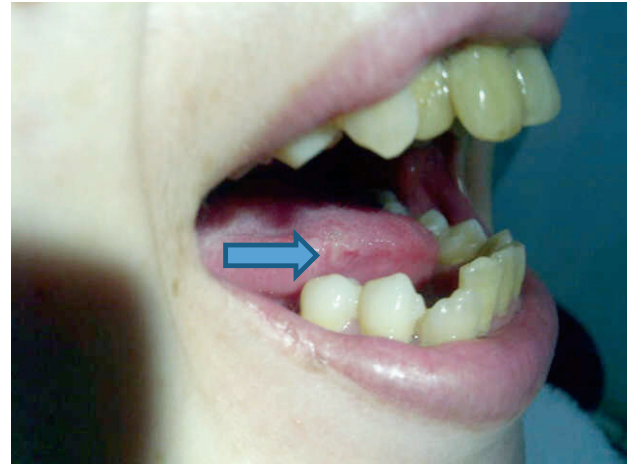
On visit 4 (6 days after visit 1), the result of anamnesis showed the lips and tongue had been cured, the ulcer on right tongue margin was more better, diameter 0.5 mm, erythema and the tongue might be moved more better (Figure 3). The wound post extraction was still pain. The patient instruction stopped to consume cetirizin, but continue to consume amoxicillin 500 mg 3 x 1, calium diclofenac 50 mg 3 x 1 and multivitamin contains zinc for five days.



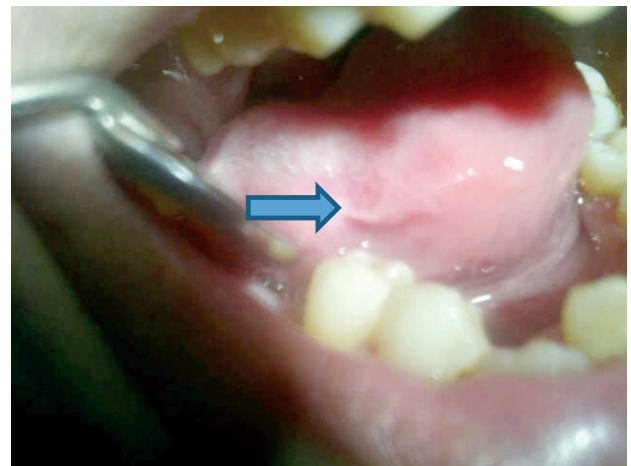**Figure 2.** The ulcer was lied on the occlusion position between teeth 16 and 17 with 47.



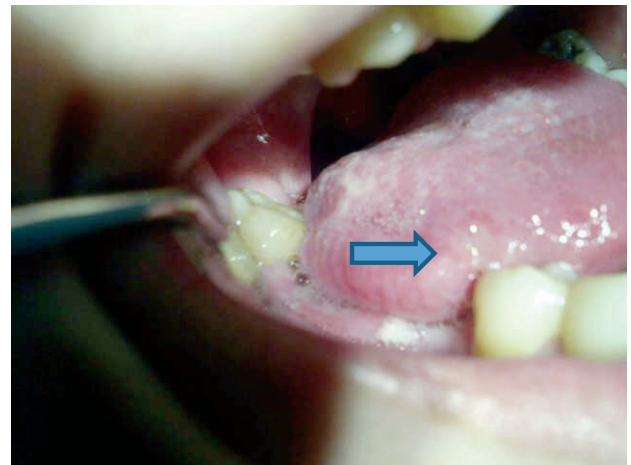
**Figure 3.** The lips and tongue had been cured, the ulcer on right tongue margin was more better, diameter 0.5 mm, erythema and the tongue might be driven more.



**Figure 4.** The ulcer on right tongue margin had cured, but there was a new ulcer near the tooth 45, diameter 0.5 mm, pain, white color and surrounded erythema.



**Figure 5.** The ulcer was suspected as traumatic ulcer because it was bitten by the teeth 15 and 45 on occlusion position.



**Figure 6.** The wound post extraction of tooth 45 was still pain and not recovered yet, but the ulcer was healed. Finally the patient could be cured.

On visit 5 (14 days after visit 1), the result of clinical examination showed the ulcer on right tongue margin had cured, but there was a new ulcer near the tooth 45, diameter 0,5 mm, pain, white color and surrounded erythema (Figure 4). The ulcer was suspected as traumatic ulcer because it was bitten by the occlusion of the teeth 15 and 45. The teeth 45 was linguoversion (Figure 5). The patient was asked to do teeth 45 extraction and continue to consume amoxicillin 500 mg 3 x 1, calcium diclofenac 50 mg 3 x 1 and multivitamin contains zinc 1 x 1.

On visit 6 (19 days after visit 1), the result of anamnesis showed ulcer had cured. The wound post extraction of tooth 45 was still pain and not healed yet. The patient was asked for continuing to consume amoxicillin 500 mg 3 x 1, calcium diclofenac 50 mg 3 x 1 and multivitamin for 5 days. Finally the patient could be cured (Figure 6).

## DISCUSSION

This case presents about the woman, 33 years old that was suffering the chronic ulcer on right tongue margin. She had been suffering the ulcer for 5 months and never recovered. The patient had come to a lot of dentists, the oral and maxillofacial surgeon, the neurologist, and the otolaryngologist, but the ulcer is still persistent. None of them asked her to do biopsy, although she had been suffering the chronic ulcer more than 2 weeks.

The intra oral examination showed in occlusion position, the teeth 17 and 47 then the teeth 15 and 45 was biting the right tongue. The oral and maxillofacial surgeon had ever been grinding the teeth 47, but the tongue was still bitten. The teeth 45 and 47 were linguoversion on 45 degrees. Based on the clinical examination, the diagnosis was chronic traumatic ulcer. The main therapy of traumatic ulcer is removing the etiology factors, so that the patient was referred to do the extraction of teeth 47 and 45.

Before doing extraction of teeth 45 and 47, the patient was referred to take CBC, blood glucose examination and biopsy. CBC examination will show the anemia condition, because the patient looked skinny and pale. It might be because of her difficult condition for eating caused the loss body weight until 10 kg for 5 months. Actually the anemia condition caused the oxygen transport and nutrition was disturbed. It made the enzymes activity on mitochondria of red blood cells was not in a good process, so that obstructed the differentiated of epithel cells growth. The terminal differentiated of epithel cells to stratum corneum was disturbed, then the oral mucous would be thinner. There was not the normal keratinized, atrophy, and disruption of the healing process.<sup>3</sup> The malnutrition condition made the ulcer was difficult to get the healing process, so in this case it aggravated the ulcer for recovering. The result of CBC was showed not severe anemia, so the anemia was not

The blood glucose examination of the patient was normal, so it was not the etiology of the chronic ulcer. This examination was done because sometimes the patient with undiagnosed or inadequately treated diabetes suffers

xerostomia and candidiasis that cause the stomatitis, sore tongue, and non specific glossitis.<sup>4</sup>

The clinical manifestation of ulcer on the right tongue margin were major ulcer, diameter 1.5 cm, pain, white color, surrounding induration margin and irregular. It had been suffering since 5 months ago and never been healed. Based on the clinical manifestation the differential diagnosis was Squamous cell carcinoma. It was caused some reasons there was the induration margin around the chronic ulcer and the ulcer had been more than 2 weeks without healing process. The biopsy must be done to get the final diagnosis as Squamous cell carcinoma.<sup>1,2,5</sup> The malignant lesion was not determined just by seeing the clinical examination, it needs the others examination to determine it as early detection by 1% toluidine blue application, brush biopsy and scalpel biopsy.<sup>6</sup>

The dentists must know the possibility of lesion changes to be carcinoma. The lesion as chronic ulcer, white or red color, and swelling on mucous membran must be confirmed by biopsy.<sup>2</sup> Early diagnosis helps the patient with malignancy to get recovery quickly. The small malignancy lesion can spread as extensive lesion rapidly. Most carcinoma is found in late condition which is in difficult phase to be cured.<sup>6,7,9</sup>

The patient was done the brush biopsy by specialist of anatomic pathology. The biopsy result from ulcer scrapping did not show the malignancy cell, so it was diagnosed as the chronic traumatic ulcer. The main therapy was removing etiology factors, so the teeth 47 and 45 had to be done the extraction. The patient was given the oral drugs as amoxicillin 500 mg three times a day and calcium diclofenac 50 mg three times a day for 5 days. Post extraction had been done by the dentist, the ulcer was cured.

After removing the etiology factor of traumatic ulcer, the monitoring of the lesion must be done. If the traumatic ulcer is persistent, although the etiology factors had been removed after 2 weeks, accordingly the patient must be done the biopsy. It may be a carcinoma.<sup>5,10</sup> After the lesion treatment had done, the dentists must avoid the trauma because of the denture or the sharp carries teeth, monitor the malignancy lesion appeared, and give the good mental support to the patients.<sup>1,2,8</sup>

It can be concluded that the main management of chronic traumatic ulcer in oral cavity is removing the etiology factors. If the ulcer is still persistent after 2 weeks from the etiology factor had been removing, it is suspected as the malignancy that is needed biopsy examination to get the final diagnosis.

## REFERENCES

1. Laskaris G. Treatment of oral disease: A Concise Textbook. New York: Thieme, Stuttgart; 2005. p. 169.
2. Cawson RA, Odell EW, Porter S. Cawson's essentials of oral pathology and oral medicine. 7<sup>th</sup> ed. UK: Churchill Livingstone, Elsevier; 2002. p. 251-3.
3. Apriasari ML, Hendarti HT. Stomatitis aftosa rekuren oleh karena anemia. Jurnal Dentofasial 2010; 9(1): 45.

4. Field A, Longman L. Tyldesley's oral medicine. 5<sup>th</sup> ed. New York, USA: Oxford University Press; 2004. p. 51–2.
5. Sciubba JJ, Regezi JA, Rogers RS. PDQ oral disease: Diagnosis and treatment. Hamilton, London: BC Decker Inc; 2002. p. 90–1.
6. Guneri P, Epstein JB, Kaya A, Veral A, Kazandi A, Boyacioglu H. The utility of toluidine blue staining and brush cytology as adjuncts in clinical examination of suspicious oral mucosal lesions. *Int J Oral Maxillofac Surg* 2010; 40(2): 155–61.
7. Epstein JB, Guneri P. The adjunctive role of toluidine blue in detection of oral premalignant and malignant lesions. *Current Opinion in Otolaryngology and Head & Neck Surgery* 2009 April; 17(2): 79–87.
8. Scully C. Oral and maxillofacial medicine: The basis of diagnosis and treatment. London, British: Wright Elsevier; 2004. p. 287–310.
9. Agus P. Prognostic value of molecular markers of oral pre-malignant and malignant lesions. *Dent J (Maj Ked Gigi)* 2009; 42(2): 104.
10. Leosari Y, Hadiati S, Agustina D. Screening of premalignant lesions in smokers using toluidine blue. *Dent J (Maj Ked Gigi)* 2009; 42(2): 90.