

Literature Review

## Simple replantation protocol to avoid ankylosis in teeth intended for orthodontic treatment

Yuli Nugraeni<sup>1</sup>, David Buntoro Kamadjaja<sup>2</sup>, and Haryono Utomo<sup>3</sup>

<sup>1</sup>Department of Conservative Dentistry, Dentistry Study Program, Brawidjaja University, Malang

<sup>2</sup>Department of Oral Surgery, Faculty of Dentistry, Airlangga University, Surabaya

<sup>3</sup>Dental Clinic, Faculty of Dentistry, Airlangga University, Surabaya

### ABSTRACT

**Background:** Dento-alveolar trauma resulted from accidents involving the oral regions mostly affect the upper central incisors. Overjet that is beyond 5 mm and incompetent lip also contribute to increase the risk. Several literatures had already discussed different methods of replantation of avulsed teeth. However, it was not meant for further orthodontic treatment. **Purpose:** The objective of this review is to propose a simple replantation protocol of avulsed teeth which also prevent from ankylosis. **Reviews:** Protruded teeth usually need orthodontic treatment; therefore, an appropriate management should be done to avoid the development of ankylosis. Ankylosis of the periodontal ligament (PDL) becomes a problem in orthodontic tooth movement in repositioned or replanted teeth. In addition, ankylosed teeth also more susceptible to root resorption. Actually, it was caused by the endodontic treatment. In particular, severely protruded or unoccluded teeth are hypofunctional, therefore have narrow PDL, thus it may facilitate to ankylosis development. Ideal management protocol such as the use of root canal sealer i.e. mineral trioxide aggregate (MTA); the using of Emdogain, and resilient wiring or semi-rigid fixation with brackets has become a solution in avulsed teeth arranged for orthodontic treatment. Nevertheless, the presence of oral surgeon, endodontist and orthodontist in the same time, and also ideal preparations after an accident was difficult to achieve. **Conclusion:** Considering that reducing the ongoing PDL inflammation with intracanal medicaments and maintaining the functional force during mastication is possible; it is concluded that this simple replantation protocol is likely.

**Key words:** replantation protocol, ankylosis prevention, orthodontic treatment

Correspondence: Yuli Nugraeni, Dentistry Study Program, Brawijaya University, Veteran 1, Malang. E-mail: [yulinugraeni@yahoo.com](mailto:yulinugraeni@yahoo.com)

### INTRODUCTION

Dental trauma is one of the most serious oral health problems in active children and adolescents. It requires immediate initial emergency treatment followed by integrated procedures to restore damaged oral structures along with subsequent trauma prevention strategy. Dentoalveolar injuries in the anterior region of the mouth are often characterized by tooth avulsion or intrusion, with or without fractures of the crown or root. The predisposing factors in dental trauma are maxillary teeth protruding more than 5 mm, which are two to three times more likely to suffer dental trauma, incompetent lip and obesity.<sup>1</sup>

Tooth avulsion accounts for 0.5–16% of traumatic injuries in the permanent dentition and for 7–21% of injuries in the primary dentition. Avulsions of permanent teeth occur most often in children at the age of 7–10 year, during which

time the relatively resilient alveolar bone provides only minimal resistance to extrusive forces.<sup>2</sup> Avulsions cause severe pulpal and periodontal injuries. The status of the pulp is one decisive object for periodontal healing. Pulp necrosis and consecutive infections cause ankylosis (or replacement resorption, RR),<sup>3</sup> and infection-related resorption (IRR, formerly called inflammatory resorption).<sup>4,5</sup> Unfortunately, tooth ankylosis leads to difficulties in orthodontic treatment i.e. retracting the avulsed protruded teeth.

Ankylosis is a known complication of replanted or severely intruded permanent incisors. Despite considerable knowledge about the pathogenesis of ankylosis from animal studies and observation of human replanted teeth, there is no known treatment to arrest this condition. Management techniques for ankylosis and its consequences are supported by little evidence, do not appear to be widely adopted and do not offer any proven long-term benefit. Nevertheless, other

literatures revealed that the antiresorptive-regenerative therapy (ART) with the local application of glucocorticoids and enamel matrix derivative (EMD, Emdogain®) and the systemic administration of doxycycline combined with semi-rigid fixation was considered to have successful results.<sup>4,6</sup> However, in private dental practice or even in small hospitals, the presence of dentists who are competent to avulsion management (i.e. special-trained dentists, oral surgeon, endodontist and orthodontist), and the provision of ideal preparations (i.e. mineral trioxide aggregate, MTA and EMD) at the same time of the accident are rarely achieved. Therefore, a simple replantation protocol of avulsed tooth should be developed to achieve a successful treatment that also prevent from ankylosis.

The objective of this review is to propose a new simple protocol of avulsed tooth management which also minimizes the risk of ankylosis; especially in tooth intended for further orthodontic treatment. This new concept is based on literatures regarding to the simplicity of methods and using the commonly available dental medicaments in most dental office.

### Avulsion

By definition, avulsion is a complete displacement of tooth out of its socket. The periodontal ligament is severed and fracture of the alveolus may occur. The diagnosis is made based on clinical and radiographic findings. Radiographic assessment will verify that the tooth is not intruded when it is clinically missing. Even though avulsion of permanent incisors is a relatively rare injury; in an emergency situation, a prompt decision should be made to treat it with replantation. Therefore, the clinician must be prepared to learn about the management protocol for avulsed teeth and identify its negative consequences such as ankylosis and root resorption.<sup>6</sup>

There are contraindications to tooth replantation which are immunocompromise, severe congenital cardiac anomaly; severe mental disability, severe uncontrolled diabetes and lack of alveolar integrity.<sup>6</sup> For better understanding of the avulsion treatment and to minimize its negative effects, the physiological and pathological aspects of the tooth and its surrounding tissue should be reviewed.

### The Periodontal Ligament

Recently it has been revealed that PDL tissue possesses multipotential mesenchymal stem cells that can differentiate into mineralized tissue-forming cells such as osteoblasts and cementoblasts. However, PDL tissue is never ossified in vivo under normal circumstances. In fact, in vitro maintained PDL cells have various osteoblast-like properties, including the capacity to form mineralized nodules, expression of bone-associated markers, and response to bone-inductive factors such as bone morphogenetic protein 2 (BMP-2) which lead to ankylosis.<sup>7</sup> Conversely, PLAP1/aspurin which expressed predominantly in the PDL negatively regulates the mineralization of PDL cells. It also plays as a negative regulator of cytodifferentiation and mineralization

probably by regulating BMP-2 activity to prevent the PDL from developing non-physiological mineralization such as ankylosis.<sup>8</sup>

### Ankylosis (Replacement resorption, RR)

Ankylosis or RR is a pathologic fusion of the cementum or dentin of a tooth root to the alveolar bone. It is most likely to affect a replanted avulsed tooth or a severely intruded tooth within weeks following trauma. Detection of ankylosis depends on clinical signs and radiographic interpretation. Clinical diagnosis of ankylosis is based on qualitative assessment of the sound produced on percussion and of mobility.<sup>3</sup> Ankylosis of teeth in the pre-adolescent can lead to infraocclusion and distortion of the gingiva and the underlying bone producing both functional and esthetic deficits with jaw growth. Therefore, the benefit of early detection is that it gives earlier warning of growth-associated infraocclusion.<sup>2, 3, 7, 8</sup>

### Pathogenesis of ankylosis

In healthy patients, PDL fibroblasts block osteogenesis within the periodontium by releasing locally acting regulators, such as cytokines and growth factors, thereby maintaining separation of tooth root from alveolar bone.<sup>8</sup> Necrosis of the periodontal ligament's cellular elements by desiccation, crushing or mechanical damage, as in severe luxation injury, disrupts this normal homeostatic mechanism. Ankylosis is established not only via inflammatory-mediated and mechanical alterations in the periodontal ligament but also because insufficient functional cellular elements survive to suppress osteogenic activity. This disruption allows growth of bone across the periodontal ligament and ankylosis (RR).<sup>3-5</sup> Inflammatory resorption (IRR) sustained by bacterial infection of necrotic pulp tissue in the replanted tooth can be effectively arrested by pulpectomy followed by Ca(OH)<sub>2</sub> root canal filling. However, despite the ability to treat IRR predictably, unfortunately, its arrest promotes RR.<sup>3,4</sup>

### Treatment of avulsion

Despite evidence that immediate replantation (i.e. within 5 min) is required for regeneration of the periodontal ligament (PDL) and its return to normal function. Most school teachers and coaches would be reluctant to replant teeth if the circumstance arose. The reasons i.e. inadequate training, reluctance to induce pain or fear in the child, fear of replacing the tooth incorrectly and fear of possible legal consequences.<sup>2</sup>

General prognosis in avulsion treatment is vary, in the permanent teeth is primarily dependent upon formation of root development and extra oral dry time. In permanent teeth, there is risk for pulp necrosis, root resorption, ankylosis, and infraocclusion during adolescent growth. The tooth has the best prognosis if replanted immediately, if not be replanted within 5 min, it should be stored in a medium to maintain vitality of the periodontal ligament.<sup>9-12</sup> Moreover, the risk of ankylosis increases significantly with

an extra oral dry time of 15 min. An extra oral dry time of 60 min is considered the point where survival of the PDL cells is unlikely.<sup>6</sup>

Transportation media for avulsed teeth include (in order of preference) Viaspan, Hank's Balanced Salt Solution, cold milk, saliva (buccal vestibule) or physiologic saline. Water is an inappropriate media because it increases osmotic pressure and cells explode, not much better than dry. If avulsed tooth is stored in a physiologic media, storage time has not been found to be a significant factor.<sup>11, 12</sup>

#### **Antiresorptive-regenerative therapy (ART)**

Since 1998 the topical and systemic application of different medicaments was used to depress resorption activity and support regeneration in the PDL. Antiresorptive-regenerative therapies (ART) with application of topical corticosteroids and enamel matrix derivative (EMD), combined with systemic doxycycline may have potential for enhancing the prognosis of avulsed teeth. Treatment strategies are directed at avoiding or minimizing inflammation, increasing revascularization, and producing hard barriers in teeth with open apices.<sup>6</sup>

If the extra-oral dry time > 60 min, soak tooth for 5 min in 2.4% NaF acidulated to a pH of 5.5 before replantation. Immediately before replantation-after removal of the coagulum from the alveolus by rinsing with sterile isotonic saline-EMD (Emdogain®) was applied onto the root surface and into the alveolus. Subsequently, topical corticosteroid (i.e. Ledermix®) is applied intracanal; followed by systemic doxycycline therapy,<sup>4</sup> and chlorhexidine mouth rinse for prevention of infection.<sup>12</sup>

#### **Splinting for tooth avulsion**

Stabilizing the tooth with a functional, semi-rigid splint for one week for avulsion without alveolar fracture<sup>13</sup> or two to three weeks with alveolar fracture will assist in re-establishing the PDL support of the tooth.<sup>1</sup> Semi-rigid splint wire is adapted to the facial or lingual surfaces of the teeth to be splinted and one sound tooth on either side of the traumatized tooth should be included.<sup>13</sup> Recent publications revealed that semi-rigid splint accommodate occlusal forces which are advantageous for PDL healing. Successful replantation of permanent teeth without ankylosis is obtained when light occlusal forces were applied via archwire during the early stages of recovery.<sup>14,15</sup>

Chen *et al.*,<sup>14</sup> study showed that occlusal force increase nitric oxide (NO) synthesis by inducible nitric oxide synthase (iNOS) which necessary for repair of injured PDL fibers, angiogenesis and nerve regeneration. Moreover NO induces osteoblast apoptosis and depresses bone formation. Consequently, with the existence of iNOS, PDL width could be maintained, thus avoid from ankylosis. Additionally, with the same stimulus Hu *et al.*<sup>15</sup> suggested that the increase of fibroblast growth factor (bFGF/FGF-2) is considered as a key factor in PDL healing.

#### **Emdogain®**

Future studies should help illuminate the reported benefits of Emdogain®, an enamel matrix derivative (Biora AB, Malmo, Sweden) extracted from developing embryonal enamel of porcine origin. It has been used to coat the entire root surface of the avulsed tooth prior to replantation. Emdogain contains proteins of the amelogenin family and is presently thought to aid in the migration, attachment, proliferative capacity, and biosynthetic activity of PDL cells.<sup>4,16</sup>

Emdogain has also been shown to enhance PDL cell proliferation and protein production, and it may act as a matrix for cells responsible for regenerating PDL at a wound site such as a replanted avulsed tooth. Several case reports and other articles have shown promising results in terms of decreased replacement root resorption when it was used topically prior to replantation in several avulsion management protocols.<sup>4</sup>

#### **Endodontic treatment of avulsed teeth**

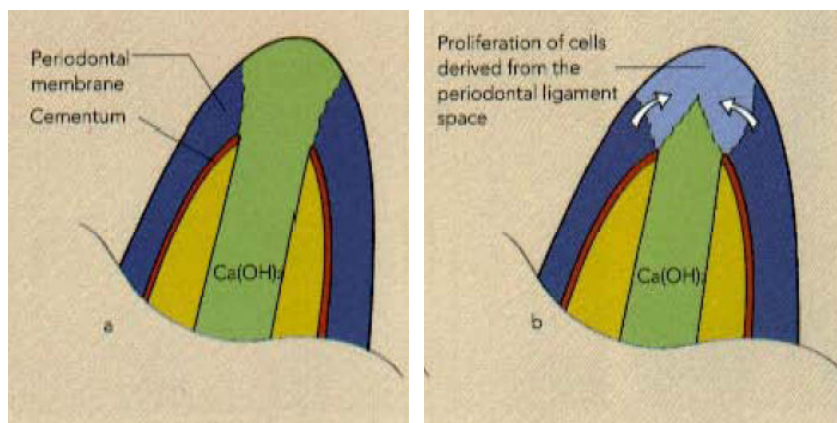
Endodontic treatment is essential for the progress of the healing process of the replanted tooth. Nevertheless, there are still controversies, especially in closed apex tooth (< 1 mm), should it be done extra or intra-orally. However, best results are obtained when the tooth is immediately, without being endodontically treated, inserted into the alveolar socket and pulp extirpation is directly done to prevent the initiation of IRR. The canal should be debrided, dressed with a corticosteroid/ antibiotic or Ca(OH)<sub>2</sub> paste for one to three months, after which time the canal can be obturated.<sup>17</sup> Intra oral endodontic is provided intra-orally only after splinting.<sup>1, 10-14</sup>

Endodontic therapy involving obturation with gutta-percha or the placement of Ca(OH)<sub>2</sub> dressings at the time of replantation delays periodontal healing and accelerates ankylosis (RR) in mature teeth. Thus, it is recommended that in mature teeth, endodontic therapy should be commenced 7–10 days following replantation. Radiographs should be taken at regular intervals of one, three, six and 12 months.<sup>1,6</sup>

In immature teeth, when the time out of the mouth is short and the apex is open, revascularization of the pulp may occur. Endodontic therapy can be delayed to establish whether revascularization will occur but only if patient compliance for follow-up treatment is assured. Regular follow-up is essential and apexification procedures should be carried out at the first sign of resorption, discoloration, the presence of a draining sinus or periapical bone loss. The root canal should be accessed so the infected tissue and debris can be removed and the canal then be filled with Ca(OH)<sub>2</sub>. Root filling involving gutta-percha and/or MTA can be carried out later.<sup>12</sup>

#### **Apexification**

Apexification is the process by which the open apex of a tooth with pulp necrosis and an incompletely formed



**Figure 1.** A) Open apex filled with  $\text{Ca(OH)}_2$ ; B) Apex closing process.<sup>21</sup>

root can be closed by deposition of hard tissue (probably cementum). To accomplish apexification, the necrotic pulp is removed, the canal is cleaned and the canal filled with  $\text{Ca(OH)}_2$ . After the apex is closed by hard tissue deposition, the root canal is filled with sealer and gutta percha (usually after 6 months) (Figure 1).<sup>18,19</sup>

#### Intracanal medicaments

The PDL management in cases of extended dry times (i.e. > 60 minutes), recent animal studies have reported that roots treated with the intracanal medicament Ledermix® (triamcinolone acetonide and demeclocycline calcium; Lederle, UK) have significantly more favorable healing and less resorption than in those treated with  $\text{Ca(OH)}_2$ . In this case, time is not a big factor thus can be done extra or intra orally.<sup>20</sup> Calcium hydroxide has several advantages as it has antimicrobial activity, disintegrates endotoxin (LPS); denatures IL- $1\alpha$ , TNF- $\alpha$ , and neuropeptides; and stimulates apex development. Combination of  $\text{Ca(OH)}_2$  with other medicaments such as iodine potassium iodide 5% and camphorated chlor-phenol chamfer (CHKM) increases its effectivity.<sup>18</sup> Nevertheless, it also interrupts healing process of PDL, thus the application should be delayed minimal until 7 days after replantation.<sup>18,19</sup>

#### Pharmacological treatment

Tetanus prophylaxis and antibiotic coverage should be considered. Treatment strategies are directed to avoid inflammation that may occur as a result of the tooth's attachment damage and/or pulpal infection.<sup>6</sup> Pharmacological treatments manipulate the inflammatory response to minimize destruction and facilitate repair of the damaged root surface by new cementum and periodontal ligament. After completion of the ART (or dental emergency treatment), doxycycline is prescribed for systemic use according to the patients' weight (2 mg/kg body weight daily, maximum dose 100 mg/day) for 5 days. Tetracycline derivatives has been widely used in periodontal treatment because of its sustained antimicrobial effects and anti-resorptive properties. Specifically, it has a direct

inhibitory effect on resorption activity of osteoclast cells and collagenase.<sup>5</sup>

While tetracycline affects osteoclasts at the site of resorption, drugs are able to affect the recruitment of osteoclasts to the site of injury. Thus the combination of the two types of drugs might have a synergistic effect on the inhibition of root resorption. Glucocorticoids have been widely used to reduce the deleterious effects of inflammatory responses. Therefore, they could also potentially be useful in manipulating the initial inflammatory response after attachment damage. Thus, repair by cementoblasts rather than bone-derived cells would be encouraged. Topical dexamethasone was found to be useful, while systemic usage was not.<sup>1</sup>

#### DISCUSSION

It is clear that according to literatures ankylosis and root resorption in tooth avulsion treatment are mostly caused by: 1) improper management directly after injury (i.e. direct replantation of contaminated tooth, washing with contaminated water); 2) dry time exceeding 60 minutes, 3) persistent inflammation of the PDL; 4) minimal or absence of occlusal force (i.e. severe protruded teeth, rigid wiring).<sup>1-5,14,15</sup> However, until now, there were still inconsistency whether endodontic treatment should be conducted extra-orally or intra-orally in avulsed tooth exceeding dry time limit.

It is interesting that notwithstanding with this controversy, studies revealed that with respect to pulpal healing, the revascularization success rate of replanted teeth has been reported to range from 8% in mature teeth to 25% to 34% in immature teeth. Relative to periodontal ligament healing, success has been reported to range from 24% to 57%.<sup>10</sup> However, this article did not compare extra-oral and intra-oral endodontic treatment. Thus, there are still other aspects that should be considered.

According to Becktor *et al.*,<sup>20</sup> several aspects which may be related to ankylosis and root resorption are the existence



of epithelial rest of Mallasez (ERM) and Hertwig's epithelial root sheath (HERS). Fujiyama *et al.*,<sup>21</sup> study showed that denervation in rats resulted in dentoalveolar ankylosis was also associated with decreased numbers of ERM cells, therefore ERM cells might protect the root against resorption. Additionally, Talic *et al.*,<sup>22</sup> study have shown that ERM might play a role for maintenance and remodelling of the PDM. It has been shown that ERM synthesise and secrete latent collagenase, and that they proliferate and increase in size in connection with experimental tooth movement. Thus, it is in coincident with Mine *et al.*,<sup>23</sup> research which revealed that low forces such as in orthodontic tooth movement is beneficial for dentoalveolar ankylosis prevention. Moreover, according to MacIntosh *et al.*,<sup>24</sup> HERS and ERM might play an important role in preventing calcification and ankylosis of the PDM has been illustrated in their comparing vertebrate ankylosis-type attachment and mammalian 'true' periodontium. This study demonstrated how the root of a gecko was free of HERS and ERM and how it was connected to bone via ankylosis.

Nevertheless, since most avulsed teeth were not directly replanted, the reason of which being: 1) the patient and people surrounding the injury site are reluctant or do not know that avulsed tooth should be replanted directly; especially if the patient is unconscious; 2) the emergency treatment priority was for other injuries which may be more severe (i.e. skull fractures); 3) delayed intra-oral inspection. Therefore, this article stresses to develop a simple management of the unreplanted avulsed teeth with dry time > 60 min, especially those with closed apex which are prone to ankylosis.

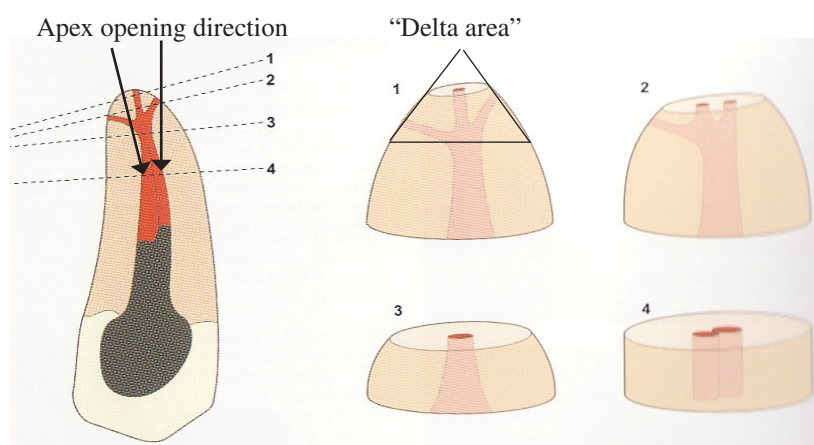
After 60 min extra oral dry time, the survival rate of the PDL cells on the root surface is almost zero, and osseous replacement is predicted. Therefore, direct extirpation the pulps and application of intraradicular medicaments is beneficial. It has been suggested that Ledermix® inhibits

the proliferation of dentinoclasts and it may prove effective when mixed with  $\text{Ca}(\text{OH})_2$ .<sup>25,26</sup> Moreover, according to studies, corticosteroids have anti-resorptive effect, and they are biocompatible. As a result, intracanal placement of corticosteroids can be used as standard treatment protocol at emergency visit for traumatic injuries, in which the root resorption is predicted. Corticosteroids can also be placed in the canal space to intercept external IRR caused by infected pulp as long as the source of infection has been cleared out.<sup>25</sup> However, Trope<sup>26</sup> did not suggest overuse of this material because of the possibility of tooth discoloration, additionally, it is not easily available in Indonesia.

The promising results of Emdogain® in replantation were excellent; however, future studies should provide much needed data in terms of the true value of its use especially when considering that it is considerably expensive compared to other less expensive or more affordable alternatives. It is shown that recent studies have found promising results using more novel, emerging alternatives, such as: 1) doxycycline; 2) minocycline; 3) alendronate; or 4) intracanal medicaments such as Ledermix®.<sup>27</sup>

Based on these literatures, the factors that may prevent replantation from ankylosis and root resorption are as follows: 1) dry time < 60 min; 2) decontamination of root surface; 3) application of preserving PDL agent (i.e. Emdogain®); 4) direct extirpation without endodontic treatment; 5) ART that includes intracanal medicaments limited to topical corticosteroids and antibiotics,  $\text{Ca}(\text{OH})_2$  is applied after 7–10 days; chlorhexidine mouthwash and systemic doxycycline; 6) semi-rigid splinting for 2–3 weeks, and 7) endodontic treatment. These factors are beneficial for reducing the ongoing inflammatory process and promoting PDL healing. Nevertheless, it is interesting that successful results were significantly higher in open apex teeth, even though they also have necrosed pulp.

Therefore, our new concept is to create an open apex



**Figure 2.** Apex opening direction should be wider apically to facilitate maximal intracanal medicaments contact with the survived PDL on the tooth or the remaining PDL on the alveolar bone, and removes the "delta area".<sup>18</sup>

condition by widening the apical orifice which are also able to remove, although not perfectly, the “delta area” which contains accessory canals (Figure 2). It is not the same procedure as apex resection which reduced root length and may be disadvantageous for avulsed teeth that are already prone to root resorption, thus may have shorter root predictably. This new concept that is considered as simple procedure had several benefits: 1) open apex facilitates the intracanal medicaments to enter the periapical area which reduce PDL inflammation; 2) it removes most of the accessory canals in “delta area” that are disadvantageous for pulp sterilization; and 3) it facilitates drainage of the pro-inflammatory mediators in the periapical area, thus also reduce inflammation. This “open apex” will gradually close with the apexification procedures, or with final root canal filling (i.e. with gutta percha). However, careful instrumentation should be done to prevent from direct stimulation of the healing PDL.

Additionally, other part of our simple procedures are the use of medicaments which usually available in dental office such as Ca(OH)<sub>2</sub>, CHKM and corticosteroid preparations i.e. Endomethazon® (dexamethazone, hydrocortisone acetate, thymol iodide etc.). If minocycline gel is available, it is beneficial for topical application in the sulcular area. In case of the absence of ideal wire for splinting with brackets, twisted ligature wire can be used instead and attached to the tooth with glass ionomer cements or composites. Patient must be also instructed to avoid biting at the avulsed tooth area for 2 weeks (periodontal healing time), to give periodontal stimulation, but the patient must avoid hard or tough food.

For the concluding remarks, it is concluded that main principle to prevent from ankylosis is by reducing the ongoing inflammation of the PDL. Inflammation leads to the altered function of the PDL transforming it into mineralized tissue-forming cells, which resulted to ankylosis. Therefore, this simple replantation protocol that stresses on facilitating the application of anti-inflammatory medicaments is logical. However, since it is still a new concept, further laboratory and clinical researches are required.

## REFERENCES

1. Endodontic Consideration in the management of traumatic dental injuries. Endodontic: colleagues for excellence. Published for the dental professional community by the American Association of Endodontists 2006. Available online from URL: [http://www.aae.org/trauma\\_dental](http://www.aae.org/trauma_dental). Accessed Oct 11, 2008.
2. Lin H. Causes and prevalence of traumatic injuries to the permanent incisors of school children aged 10–14 years in Maseru, Lesotho. A Thesis. 2006.
3. Tekin U, Filippi A, Pohl Y, Kirschner H. Expression of proliferating cell nuclear antigen in pulp cells of extracted immature teeth preserved in two different storage media. *Dental Traumatol* 2008; 24:38–42.
4. Campbell KM, Casas MJ, Kenny DJ. Ankylosis of traumatized permanent incisors: pathogenesis and current approaches to diagnosis and management. *J Can Dent Assoc* 2005; 71(10):763–8.
5. Pohl Y, Filippi A, Kirschner H. Results after replantation of avulsed permanent teeth. II. Periodontal healing and the role of physiologic storage and antiresorptive-regenerative therapy. *Dent Traumatol* 2005; 21:93–101.
6. Management of Acute Dental Trauma. Reference Manual V29/No.7 07/08. Available online from URL: [www.aapd.org/media/Policies\\_Guidelines/GTrauma.pdf](http://www.aapd.org/media/Policies_Guidelines/GTrauma.pdf). Accessed October 15, 2008.
7. Yoshizawa T, Takizawa F, Iizawa F, Ishibashi O, Kawashima H, Matsuda A, *et al.* Homeobox protein Msx2 acts as a molecular defense mechanism for preventing ossification in ligament fibroblasts. *Mol Cell Biol* 2004; 24(8):3460–72.
8. Yamada S, Tomoeda M, Ozawa Y, Yoneda S, Terashima Y, Kazuhiko I, *et al.* iPLAP-1/Asporin, a novel negative regulator of periodontal ligament mineralization. *J Biol Chem* 2007; 282(32):23070–80.
9. Saif LS, Tordik PA. Avulsed permanent teeth - new treatment guidelines. *Clinical Update* 2004; 26(2):1–4.
10. McIntyre JD, Lee JY, Trope M, Vann Jr WF. Management of avulsed permanent incisors: a comprehensive update. *Pediatr Dent* 2007; 29:56–63.
11. Kenny DJ, Barret EJ, Casas MJ. Avulsions and intrusions: the controversial displacement injuries. *J Can Dent Assoc* 2003; 69(5):308–13.
12. Flores MT, Andersson L, Andreasen JO, Bakland LK, Malmgren B, Barnett F, *et al.* Guidelines for the management of traumatic dental injuries. II. Avulsion of permanent teeth. *Dental Traumatol* 2007; 23(3):130–6.
13. DiAngelis AJ. Bruised, broken and bedeviled teeth: contemporary management of traumatic dental injuries. Available from: URL [www1.umn.edu/dental/courses/dent\\_5501/diangelis\\_handout.pdf](http://www1.umn.edu/dental/courses/dent_5501/diangelis_handout.pdf). Accessed October 7, 2008.
14. Chen CC, Kanno Z, Soma K. Occlusal forces promote periodontal healing of transplanted teeth with enhanced nitric oxide synthesis. *J Med Dent Sci* 2005; 52(1):59–64.
15. Hu FW, Hosomichi J, Kanno Z, Soma K. The influence of occlusal stimuli on basic fibroblast growth factor expression in the periodontal healing of replanted teeth. *J Med Dent Sci* 2008; 55:129–35.
16. Kenny DJ, Barrett EJ, Johnston DH, Sigal MJ, Tennenbaum HC. Clinical management of avulsed permanent incisors using Emdogain: initial report of an investigation. *J Can Dent Assoc* 2000; 66(1):21.
17. Moule AJ, Moule CA. The endodontic management of traumatized permanent anterior teeth: a review. *Aus D J Supplement* 2007; 52(Suppl1):S122–S37.
18. Lumley P, Adams N, Tomson P. *Practical clinical endodontics*. 1<sup>st</sup> ed. Burke FJT, editor. Edinburgh: Churchill Livingstone; 2006. p. 82.
19. Tsukiboshi M. *Treatment planning for traumatized teeth*. 1<sup>st</sup> ed. Chicago: Quintessence Pub; 2000. p. 66.
20. Becktor KB, Nolting D, Becktor JP, Kjær I. Immunohistochemical localization of epithelial rests of Malassez in human periodontal membrane. *Eur J Orthod* 2007; 29:350–3.
21. Fujiyama K, Yamashiro T, Fukunaga T, Balam TA, Zheng L, Takano-Yamamoto T. Denervation resulting in dento-alveolar ankylosis associated with decreased Malassez epithelium. *J Dent Res* 2004; 83(8):625–9.
22. Talic NF, Evans CA, Daniel JC, Zaki AE. Proliferation of epithelial rests of Malassez during experimental tooth movement. *Am J Orthod Dentofac Orthop* 2003; 123:527–33.
23. Mine K, Kanno Z, Muramoto T, Soma K. Occlusal forces promote periodontal healing of transplanted teeth and prevent dentoalveolar ankylosis: an experimental study in rats. *Angle Orthod* 2005; 75(4):637–44.
24. McIntosh JE, Anderton X, Flores-De-Jacoby L, Carlson DS, Shuler CF, Diekwisch TGH. Caiman periodontium as an intermediate between basal vertebrate ankylosis-type attachment and mammalian ‘true’ periodontium. *Micr Res Tech* 2002; 59(5):449–59.
25. Chen H, Teixeira FB, Ritter AL, Levin L, Trope M. The effect of intracanal anti-inflammatory medicaments on external root resorption of replanted dog teeth after extended extra-oral dry time. *Dental Traumatol* 2008; 24:74–8.
26. Trope M. *Clinical management of the avulsed tooth*. Mexico: OOTS Summit V–Monterrey; 2005. p. 1–5.
27. Filippi A, Pohl Y, von Arx T. Treatment of replacement resorption by intentional replantation, resection of the ankylosed sites, and Emdogain—results of a 6-year survey. *Dental Traumatol* 2006; 22(6):307–11.