

Case Report

The role of proper treatment of maxillary sinusitis in the healing of persistent oroantral fistula

David B. Kamadjaja

Department of Oral and Maxillofacial Surgery
Faculty of Dentistry Airlangga University
Surabaya – Indonesia

ABSTRACT

Background: Oroantral communication (OAC) is one of the possible complications after extraction of the upper teeth. If not identified and treated properly, a large OAC may develop into oroantral fistula (OAF) which means that there is a permanent epithelium-lined communication between antrum and oral cavity. Such fistulas may cause ingress of microorganism from oral cavity into the antrum leading to maxillary sinusitis. Oroantral fistula usually persists if the infection in the maxillary antrum is not eliminated. Therefore, treatment of oroantral fistula should include management of maxillary sinusitis in which surgical closure of oroantral fistula should be done only when the sinusitis has been cured. **Purpose:** This case report emphasizes on the importance of proper management of maxillary sinusitis in the healing of oroantral fistula. **Case:** A case of an oroantral fistula following removal of upper left third molar is presented. As the maxillary sinusitis was not identified pre-operatively, two surgical procedures to close the fistula had ended up in dehiscence. **Case management:** The diagnosis of maxillary sinusitis was finally made and the sinusitis subsequently treated with combination of trans-alveolar sinus wash out, insertion of an acrylic splint, and two series of nasal and sinus physiotherapy procedures. The size of the defect decreased gradually during the treatment of the sinusitis and finally closed up without any further surgical intervention. **Conclusion:** This case report points out that it is important to detect intraoperatively an antral perforation after any surgery of the maxillary teeth and to close any oroantral communication as early as possible and that it is important to treat properly any pre-existing maxillary sinusitis before any surgical method is done to close the fistula.

Key words: persistent oroantral fistula, treatment of maxillary sinusitis

Correspondence: David B. Kamadjaja, c/o: Departemen Bedah Mulut dan Maksilofasial, Fakultas Kedokteran Gigi Universitas Airlangga. Jln. Mayjend. Prof. Dr. Moestopo no. 47 Surabaya 60132. Email: davidbk@sby.dnet.net.id

INTRODUCTION

Perforation of maxillary sinus, referred to as oroantral communication, which may lead to formation of oroantral fistula is a relatively uncommon condition. It may occur as a complication of trauma, surgery, irradiation, infection, cyst or neoplasm. One of the common causes of oroantral fistula is extraction of maxillary molars especially in cases where the roots of the teeth are in close relationship with a large antrum.¹ Although extraction of upper second premolars, first and second molars are the procedures most frequently associated with antrum perforation removal of upper third molars may also cause oroantral communication

especially when surgical intervention, either with or without ostectomy, is performed.²

Once the diagnosis of oroantral fistula is confirmed it should be closed surgically. However, successful closure of chronic oroantral fistula can only be achieved if there is no antral infection. Therefore, the first aim of the treatment of oroantral fistula is to eliminate any coexisting maxillary sinus infection.³

This paper presents a case of oroantral fistula following surgical removal of impacted upper left third molar. As maxillary sinusitis was not suspected and treated accordingly, a couple of surgical methods to close the fistula ended up in dehiscence. After maxillary sinusitis had been

diagnosed and treated properly the oroantral fistula closed up gradually and uneventfully. This case report emphasizes on the importance of proper management of maxillary sinusitis in the healing of oroantral fistula.

CASE

A 36-year-old female patient came to private clinic to have her all wisdom teeth removed as was suggested by her physician because of chronic gastric problem. Panoramic x-ray showed all of her four third molars were impacted. It was also noted from the x-ray film that the upper third molars on both sides were closely related to the maxillary sinuses (Figure 1). As requested by the patient, all of the impacted teeth were surgically removed in one visit under local anesthesia. Upon removal of the upper right third molar an oroantral communication was confirmed clinically and was subsequently closed with pedicle buccal fat pad graft as it was readily available during the excision of the tooth. The left upper third molar, on the other hand, was removed with less difficulty and clinically no oroantral communication was suspected, therefore the surgical wound was closed primarily with interrupted suturing. The patient was instructed to avoid strong gargling and

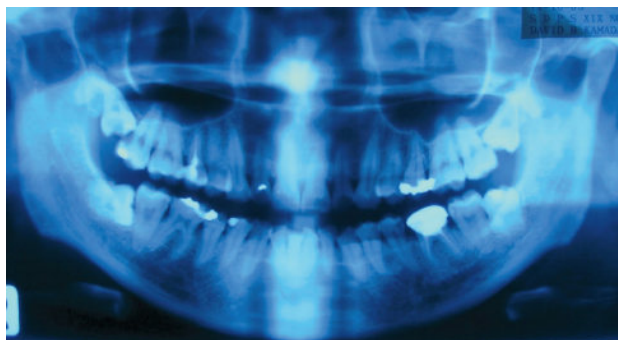

Figure 1. Panoramic x-ray showing four impacted third molars and the close relationship between maxillary sinuses and the upper third molars on both sides.

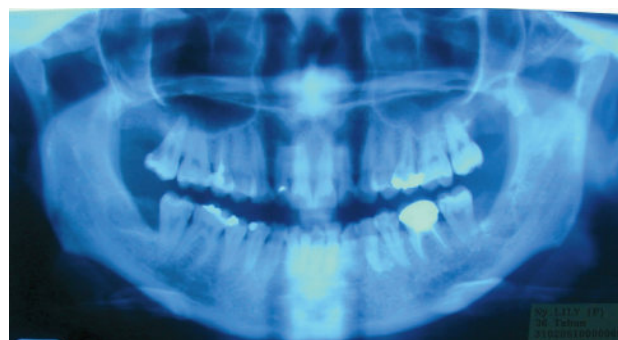


Figure 2. Post operative panoramic x-ray showing that all post excision socket are clear of root fragments and the antral floor in the area of post excision sockets seem to be partly missing which might indicate antral perforations on both sides.

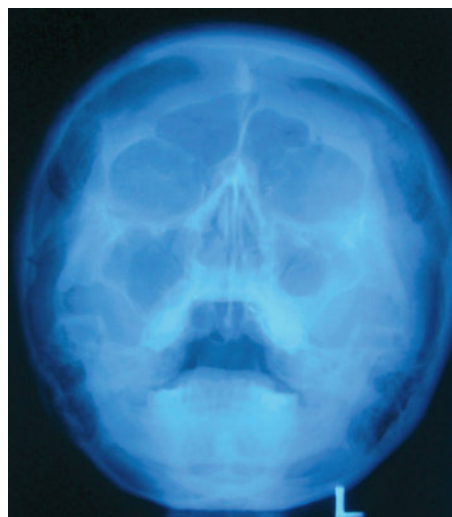

Figure 3. Water's film showing reduced radiolucency of the left antrum with obvious thickening of the antral lining indicating chronic inflammation of the left maxillary sinus. The right antrum appears normal.

nose blowing for one week and she was put on a course of amoxicillin/clavulanic acid 500 mg 3 times daily for 5 days.

Seven days after the surgery the patient complained of fluid leakage into the left nose during drinking and tooth brushing. She admitted having history of chronic nasal discharge through her left nostril particularly in the morning way before the surgery but no foul smell was noted by the patient. Intra orally, the surgical wound on the left upper third molar was still open and the socket measuring 8 mm in diameter was not filled with adequate amount of granulation tissue. Irrigation through the socket with normal saline solution indicated that there was minimal fluid leakage into the left maxillary sinus but did not reveal any sign of infection. Diagnosis of oroantral communication was made and two days later the patient was operated on to close the communication with primary closure using buccal flap method.

One week after the surgery the patient came back with a complaint of fluid leakage from mouth to her left nose but it was still considered as minimal by the patient. On clinical examination dehiscence of the previous surgical wound was again noted showing some pus discharge from the socket. Post operative panoramic x-ray confirmed that there was no root fragment left in the socket and both antrum seemed to have similar appearance (Figure 2) which might indicate that the left antrum was not infected. Diagnosis of suppurative infection of the surgical wound was made. Under local anesthesia the wound was debrided and irrigated with 3% hydrogen peroxide solution and normal saline. Iodoform gauze was subsequently inserted to the wound and the patient informed that she would need another surgery to close the wound in order to prevent infection of the left antrum.

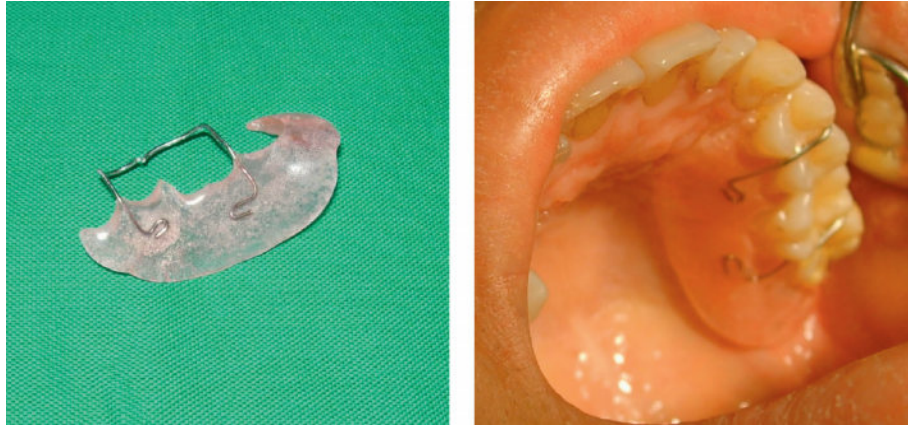


Figure 4. Unilateral palatal acrylic splint, the palatal plate is extended buccally at the region of upper left third molar to cover the fistula opening (left); the acrylic splint is inserted in the patient's mouth (right).

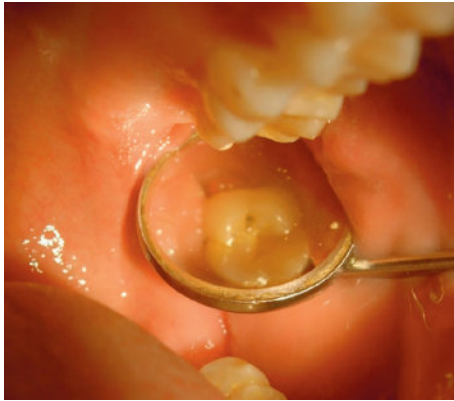

Figure 5. Intra oral examination showing that the fistula opening has closed completely, confirmed by the absence of fluid leakage into the nose upon saline irrigation of the post extraction socket.

Three days later, the wound was surgically closed applying buccal fat pad graft with the overlying mucosa being approximated and held in place with stay sutures to avoid compromising the graft. Nine days after the second closure surgery, however, almost all of the fat pad graft overlying the socket disappeared and the wound opened up again showing some pus coming out from the socket. Irrigation with normal saline to the socket indicated that there was a more obvious communication between the tooth socket and the antrum.

CASE MANAGEMENT

Diagnosis of oroantral fistula and coexisting maxillary sinusitis was made. The wound was debrided and washed out with normal saline solution and packed up with iodoform gauze. Impression of upper left dentition was taken for construction of an acrylic splint to cover the

wound. The patient was subsequently referred to an ENT doctor for management of the maxillary sinusitis.

From clinical examination and Water's x-ray (Figure 3) the ENT doctor confirmed the diagnosis of left maxillary sinusitis. The patient was given oral medications consisting of levofloxacin 500 mg once daily for five days, antihistamine, mucolytic agent, and nasal decongestant. She was also treated with two series of nasal and sinus physiotherapy using short wave diathermy and nasal nebulizing therapy using budesonide solution. During the above therapy trans-alveolar sinus wash out was done twice a week for consecutive two weeks and the patient was kept wearing a unilateral palatal acrylic splint (Figure 4) to cover the oral opening of the fistula and chlorhexidine mouth wash was prescribed to be used twice daily. The treatment of the maxillary sinusitis took a total of three weeks and at the end of the treatment the size of the fistula had shrunk considerably. The patient was instructed to wear the splint at all times, to be removed only during application of mouthwash and cleaning of the splint, and she was reviewed on a regular basis. Any surgery was postponed and any progress observed during the healing period. About two months after the initial non-surgical treatment the fistula was found to close up completely which was confirmed visually (Figure 5) and by the absence of fluid leakage into the left nose when intra socket saline irrigation was performed.

DISCUSSION

Extraction of maxillary molars may advertently create an oroantral communication especially in cases where the roots of the teeth are in close relationship with a large antrum. The most frequent cause underlying oroantral communication is surgical extraction of the second premolar and of the first and second molars of the upper jaw, the latter also being referred to as antral teeth⁴ which is primarily due to the proximity between the apexes of these teeth and the

maxillary sinus.^{5,6} The complication may also arise in the case of upper third molar extractions especially when an aggressive surgical technique or excessive post-extraction alveolar curettage are performed, or when the patient in the immediate post-operative period performs maneuvers that tend to increase intra antral pressure.² In the current case, the intimate relation of the upper left third molar to the inferior antral wall definitely contributed to the increased likelihood of the incidence of oroantral communication. The risk of such communication became higher as osteotomy was performed to surgically remove the bone overlying the impacted upper left third molar.

The intraoperative diagnosis of oroantral communication can be made with Valsalva maneuver⁷ which offers a sensitivity of 52% or by the use of a blunt-edged Bowman probe to assess perforations of the maxillary sinus floor with a sensitivity of 98%.⁸ However, since it is not a routine procedure to check for such communication after every tooth extraction the operator may miss its occurrence so that no specific treatment is done to close the defect. In the case presented here, following removal of the left upper third molar oroantral communication was not suspected thus no specific measure is performed to close it. It is a good practice, therefore, to implement diagnostic procedure mentioned above on a routine basis in cases where the risk for oroantral communication is considered high.

An oroantral communication which is less than 5 mm in diameter usually heals spontaneously. However, a sinus perforation of more than 5 mm in diameter frequently fails to close spontaneously and therefore requires proper surgical closure.^{1,9} If the oroantral communication is left untreated and remains open or if infection persists for a long period of time, chronic inflammation of the antral membrane may result with permanent epithelization of the oral-sinus fistula – a situation that further increases the risk of sinusitis.⁵ The left maxillary sinusitis in this patient was initially thought to be solely caused by the oroantral fistula, however the ENT doctor who examined her confirmed that it was actually of nasal origin as the patient had history of chronic rhinitis of the left nose. In my opinion, the sound judgment would be that the pre-existing maxillary sinusitis of nasal origin has impaired the healing capacity of the post-excision wound of upper left third molar and this gradually has led to the formation of oroantral fistula. The fistula has, in turn, exacerbated the infection of the left antrum due to invasion of microorganisms from the oral cavity. This may become the reason why the two surgical procedures has failed to close the defect and ended up in dehiscence. This is in accordance with Howe³ who mentioned that successful closure of chronic oroantral fistula can only be achieved if there is no antral infection and therefore the first

aim of treatment is to eliminate any coexisting maxillary sinus infection.

It is interesting to note, however, that after conservative treatment with combined oral medication and nasal and antral physiotherapies and covering the wound with splint for nearly two months the oroantral fistula finally closed up without further surgical intervention. This is in accordance with a case reported by Logan and Coates¹⁰ in which complete healing of an oroantral fistula was evident following eight weeks of wearing a surgical splint. Sokler *et al.*¹¹ suggested that with permanent wearing of a palatal plate, occasional rinsing of the sinus with physiological solution, and enteral application of antibiotic, it is possible to cure an inflamed sinus and achieve spontaneous closure of the fistula, even in cases which have existed for more than a month.

This case report points out two important things. First, it is a good practice that after removal of an impacted upper third molar which is closely related to maxillary sinus a thorough examination should be done to confirm any existence of oroantral communication and primary closure of the wound be performed accordingly if it exists. Second, it is important that the pre-existing antral infection be properly treated in every case of oroantral fistula before deciding to close the fistula surgically no matter what surgical methods are used.

REFERENCES

1. Awang MN. Closure of oroantral fistula. *Int J Oral Maxillofac Surg* 1988; 17:110–5.
2. del Rey-Santamaría M, Valmaseda-Castellón E, Berini-Aytés L, Gay-Escoda C. Incidence of oral sinus communications in 389 upper thirmlolar extraction. *Med Oral Patol Oral Cir Bucal* 2006; 11: E334–8.
3. Howe GL. *Minor oral surgery*. 3rd ed. Bristol: John Wright & Sons Ltd; 1985. p. 207–23.
4. Güven O. A clinical study on oroantral fistulae. *J Cranio-Maxillofac Surg* 1998; 26:267–71.
5. Skoglund LA, Pedersen SS, Holst E. Surgical management of 85 perforations to the maxillary sinus. *Int J Oral Surg* 1983; 12:1–5.
6. Punwutikorn J, Waikakul A, Pairuchvej V. Clinically significant oroantral communications- a study of incidence and site. *Int J Oral Maxillofac Surg* 1994; 23:19–21.
7. Kretzschmar DP, Kretzschmar CJL, Salem W. Rhinosinusitis. Review from a dental perspective. *Oral Surg Oral Med Oral Pathol Oral Radiol Endod* 2003; 96:128–35.
8. Ehrl PA. Oroantral communication. *Int J Oral Surg* 1980; 9:351–8.
9. Kruger GO. *Textbook of oral surgery*. 4th ed. CV Mosby Co; 1974. p. 255–60.
10. Logan RM, Coates EA. Non-surgical management of an oro-antral fistula in a patient with HIV infection. *Australian Dental Journal* 2003; 48(4):255–8.
11. Sokler K, Vuksan V, Lauc T. Treatment of oroantral fistula. *Acta Stomatol Croat* 2002; 36(1): 135–40.