

CASE REPORT:**Frozen section allows more accurate management in suspected ovarian malignancy in young women****Laila Nuranna, Ditha Adriana Loho*, Christin Wigina Hia**

Gynecologic Oncology Division, Department of Obstetrics and Gynecology, Faculty of Medicine in University of Indonesia, Cipto Mangunkusumo General Hospital (RSCM), Jakarta, Indonesia

ABSTRACT

Objectives: To present three cases of young women with suspected ovarian malignancy with the aim to evaluate the role of intraoperative frozen section in suspected malignant ovarian neoplasms in women with young age.

Case Report: Mrs. M, 25 years old, is a nullipara with a history of fertility treatment. She presented with bilateral ovarian cysts suspected to be malignant and an elevated CA-125 level. Intraoperative frozen section showed borderline ovarian tumor, allowing for conservative management. Mrs. A, 32-years old, with right cystic ovarian neoplasm suspected to be malignant and elevated CA-125. Frozen section showed results of cystadenocarcinoma, patient's family was informed of the result during the surgery and the operator continued to manage the patient conservatively. Ms. N, 27 years old, was referred with suspected ovarian malignancy and the differential diagnosis of peritoneal tuberculosis. Frozen section confirmed the presence of tuberculosis infection, and the patient was managed accordingly.

Conclusion: Despite conservative management being top priority treatment in young-aged women with ovarian neoplasm, additional information of frozen section allows for more accurate management.

Keywords: frozen section, malignancy, ovarian, young women

ABSTRAK

Tujuan: Melaporkan tiga kasus pada wanita muda dengan dugaan keganasan ovarium dengan tujuan mengevaluasi peran potong beku intraoperatif pada dugaan neoplasma ovarium ganas pada wanita dengan usia muda.

Laporan Kasus: Ny. M, 25 tahun, nullipara dengan riwayat pengobatan fertilitas. Pasien datang dengan kista ovarium bilateral yang diduga ganas dan peningkatan kadar CA-125. Potong beku intraoperatif menunjukkan tumor ovarium borderline, memungkinkan untuk diberikan manajemen konservatif. Ny. A, 32 tahun, dengan neoplasma ovarium kistik kanan yang diduga ganas dan peningkatan CA-125 meningkat. Potong beku menunjukkan hasil cystadenocarcinoma. Keluarga pasien diberitahu tentang hasil selama operasi dan operator terus menangani pasien secara konservatif. Nona N, 27 tahun, dirujuk dengan dugaan keganasan ovarium dan diagnosis banding tuberkulosis peritoneal. Potong beku mengkonfirmasi adanya infeksi tuberkulosis, dan pasien ditangani dengan tepat.

Simpulan: Meskipun penatalaksanaan konservatif menjadi pengobatan prioritas utama pada wanita usia muda dengan neoplasma ovarium, informasi tambahan dari potong beku memungkinkan penatalaksanaan yang lebih akurat.

Kata kunci: potong beku, keganasan, ovarium, wanita muda

***Correspondence:** Ditha Adriana Loho, Gynecologic Oncology Division, Department of Obstetrics and Gynecology, Faculty of Medicine in University of Indonesia, Cipto Mangunkusumo General Hospital (RSCM), Jakarta, Indonesia. E-mail: hanni.dayang@gmail.com

pISSN:0854-0381 • eISSN: 2598-1013 • doi: <http://dx.doi.org/10.20473/mog.V28I32020.135-139>

• Maj Obs Gin. 2020;28:135-139 • Received 11 Mar 2020 • Accepted 22 Oct 2020

• Open access under CC-BY-NC-SA license • Available at <https://e-journal.unair.ac.id/MOG/>

INTRODUCTION

Suspected malignant ovarian neoplasms at a young age have their own uniqueness in terms of treatment. Intraoperative frozen section as a diagnostic role often has been controversial because most cases will end up with conservative treatment. We present three cases of young women with suspected ovarian malignancy with the aim to evaluate the role of intraoperative frozen section in suspected malignant ovarian neoplasms in women with young age.

CASE REPORT

First Case

Mrs. M, 25 years old, is nulliparous after 3 years of marriage. During the course of infertility treatment by ovulation induction with clomiphene citrate, we discovered bilateral papillary ovarian cysts suspected to be malignant. The patient did not report any complaints that may be attributed to the cyst. The right ovary was 98x58x82 mm with intracystic papillae and intra mass vascular resistance of -0.2 , while the left ovary was 35x15x25 mm in size (Figure 1 and 2). The patient's Ca-125 value was 119.5 U/ml. During laparotomy, 75 ml of serous ascites was obtained. A normal uterus was visualized, as well as enlargement of the right ovary sized 9x8x8 cm comprised of cystic tumor and a 2x2x1 cm tumor mass in the left ovary. Such appearance represented clinical staging of Ib ovarian tumor. A right salpingo-oophorectomy and tumor excision of the left ovary was performed. Intraoperative frozen section diagnosis shows a borderline serous ovarian cystadenoma. Thus, the procedure was continued by right pelvic lymphadenectomy and omentectomy. The patient was then monitored for one year and no residual disease was encountered, with Ca-125 value of 22.6 U/ml. After the treatment, patient was able to conceive and she has given birth twice. Based on the frozen section results, conservative treatment was the appropriate action for this patient. Moreover, operators can be more confident in performing conservative surgery and avoid unnecessary surgery.

Second Case

Mrs. A, a 32-years old nullipara, has been married for 1 year. She presented with the chief complaint of intraabdominal mass for 3 months prior. During examination, a cystic ovarian neoplasm suspected to be malignant was identified and the Ca-125 value of 960 U/ml. In intraoperative procedure, they obtained ascites and a 15x12x12 cm mass in her right ovary with

irregular surface. The uterus and left ovary does not show any abnormalities. Right salpingo-oophorectomy and frozen section were performed and the result was suggestive for stage IIIB ovarian cancer. Frozen section results showed a cystadenocarcinoma, allowing the operator to be more confident in performing the next procedure, namely omentectomy, pelvic lymphadenectomy and appendectomy. There was minimal residual tumor (<1 cm). Patient was given postoperative chemotherapy consisting of Carbosin 600 mg and epirubicin 160 mg for 6 series. Patient was monitored for 7 years, in which period she has not gotten pregnant yet and no recurrent tumor with Ca-125 value of 1.2 U/ml.

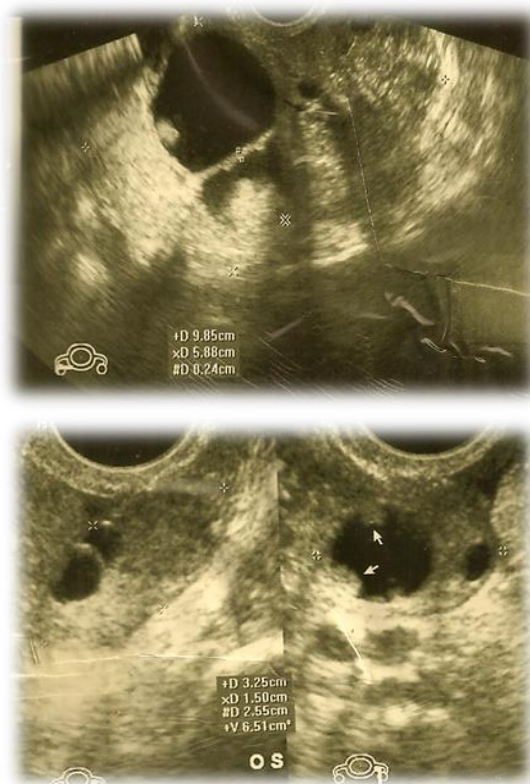

Figure 1. Ultrasound image of ovarian cystic mass with papillary appearance

Third Case

Ms. N, 27 years old, unmarried, presented with the chief complaint of abdominal pain for 1 month and weight loss. She was referred by general surgery with suspected multicystic ovarian tumor and ascites identified through CT-Scan with Ca-125 value of 485 U/ml. Ultrasound examination showed ascites and right ovarian mass sized 30x24mm. Thus, the initial working diagnosis was cystic ovarium neoplasm suspected to be malignant with ascites and the differential diagnosis was peritoneal

tuberculosis. The operator decided to perform frozen section examination during laparotomy. Intraoperatively, there was omental cake and casseous appearance covering the internal genitalia. Frozen section result showed evidence of tuberculosis infection (Figure 3B), therefore the operator ended the procedure and the treatment was continued with tuberculosis treatment. Patient was monitored for 2 years and was shown to be in good condition.

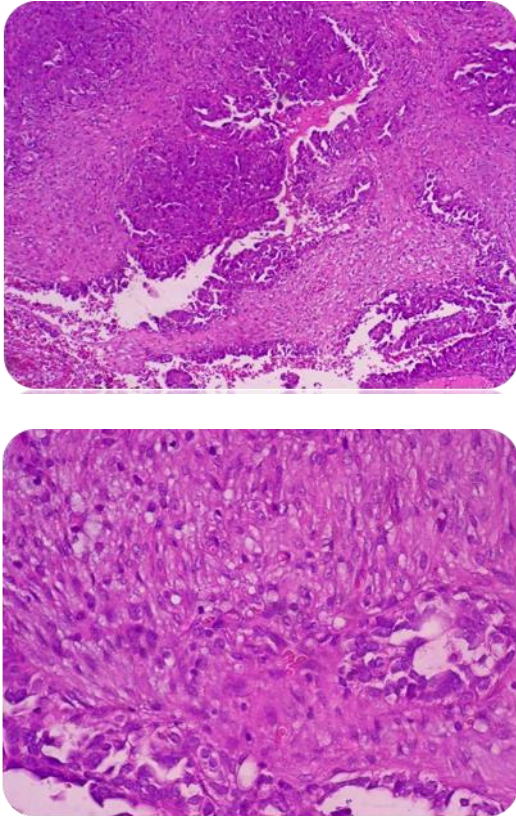


Figure 2. Histopathology results of Mrs. A showing cystadenocarcinoma

DISCUSSION

The role of frozen section in suspected ovarian malignancies in young women has been previously debated. This is due to the fact that surgical procedures in young women will generally end up in conservative management with the aim of fertility preservation. Interestingly, several opinions have supported the role of frozen section in due to the same reason, aiming at fertility sparing in young women.^{1,2} In a study, sensitivity of frozen section for benign, borderline, and malignant ovarian tumors are 98.2%, 57.1%, and 86.1%

respectively, while the specificity are 87%, 96.4%, and 98.5% respectively. While the consistency of frozen section and paraffin block in borderline tumor was shown to be 60%.¹

The capability of frozen section is limited in large specimens, especially in mucinous type ovarian tumors. Furthermore, sensitivity for borderline ovarian tumor has been found to be low owing to the morphological complexity of such tumors. In the case of a discrepancy between frozen section examination and paraffin block, re-evaluation involving surgeons and pathologists must be done.^{1,3}

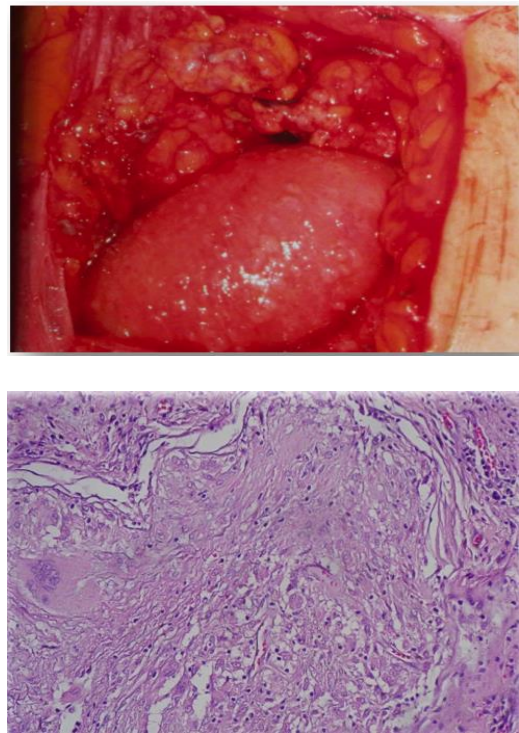


Figure 3. Laparotomy and frozen section results. (A) Intraoperative appearance of peritoneal tuberculosis. (B) Frozen section showing tuberculosis infection.

In the first case, the ovarian mass was discovered while the patient (aged 25 years old) was undergoing fertility treatment using clomiphene citrate for 3 cycles. The presence of a mass in the ovaries prior the ovulation induction is unknown. A cohort study conducted in Denmark shows no increased risk of ovarian cancer after gonadotropin, clomiphene citrate, human chorionic gonadotropin, or gonadotropin releasing hormone regimen.^{4,5}

Table 1. Resume of the cases

Identity	Pre-Operative diagnosis	Intraoperative	Frozen section result	Post-Operative diagnosis	Role of Frozen section
Mrs. M, 25 years old POA0	Bilateral cystic ovarian neoplasm with papillary appearance suspected malignant.	Serous ascites 75 cc. Normal uterus and enlargement of right ovary cystic mass with spongy appearance 9x8x8 cm. The size of left ovary mass was 2x2x1 cm ~ clinical staging – ovarian cancer stage Ib	serous ovarian cystadenoma Borderline type	Serous cystadenoma papilliferum ovarii borderline	Prevent <i>overtreatment</i> Operator will be more confident in decision-making
Mrs. A, 32 years old POA0	Cystic ovarian neoplasm suspected malignant	Ascites and right ovarium mass with irregular surfaces (Diameter 15x12x12 cm). Normal uterus and left ovary. Clinical staging: Ovarian cancer stage IIIb	Cystadeno-carcinoma of the ovary stage IIIb	Ovarian cancer stage IIIb	Accurate <i>conservative management surgical staging</i> Intraoperative discussion with families will be clearer
Ms. N, 27 years old	Cystic ovarian neoplasm suspected malignant with ascites. Differential diagnosis of peritoneal tuberculosis	<i>omenta cake</i> dan caseous appearance covering the internal genitalia	Tuberculosis	Peritoneal tuberculosis	Prevent unnecessary surgery

Within six months of therapy, an ovarian mass was identified and patient's Ca-125 value was 119 U/ml leading to suspicion of ovarian malignancy. Therefore, laparotomy with frozen section examination was performed. Intraoperatively, she was clinically diagnosed with ovarian cancer stage Ib but from the frozen section result showed a serous cystadenoma papilliferum borderline ovarian tumor. Frozen section results provided good information, correcting the clinical diagnosis of malignancy giving the surgeon more confidence in applying conservative management in this patient.

In the second case, the frozen section showed results of cystadenocarcinoma, allowing the operator to be more confident in discussing further plans for the patient with her family. There was indeed an ovarian malignancy in the right ovary but a normal contralateral ovary, therefore the suitable action in this patient is conservative surgery by leaving the uterus and contralateral ovary. In the third case, the role of frozen section is very crucial in this patient in order to determine further treatment. The symptoms for peritoneal tuberculosis are unspecific such as abdominal pain, ascites, pelvic mass and weight loss. Diagnosis in peritoneal tuberculosis is often difficult as the clinical picture may mimic ovarian carcinoma. Further complicating the pre-operative diagnosis, patients with tubal tuberculosis may present with an irregular adnexal mass. Moreover, CA-125 levels may be markedly elevated, further supporting the suspicion for ovarian malignancy. Such patients are commonly submitted to unnecessary surgery due to this suspicion.^{6,7} As was the case in this case, patient was

suspected to have an ovarian malignancy due to the presence of ascites and ovarian mass, therefore indicating for laparotomy with frozen section. By evidence from frozen section, the patient was avoided from overtreatment and un-necessary surgery.

CONCLUSION

Despite conservative management being top priority treatment in young-aged women with ovarian neoplasm, additional information of frozen section allows for a more accurate management. We presented three cases of suspected ovarian malignancy in young women with different outcomes, in which frozen section results was able to aid in determining further management. Moreover, with the evidence of frozen section we could obtain data, in order to provide better communication with patient and families; therefore they may also be involved in decision making.

REFERENCES

1. Wootipoom V, Dechsukhum C, Hanprasertpong J, et al. Accuracy of intraoperative frozen section in diagnosis of ovarian tumors. J Med Assoc Thai. 2006;89(5):577-82
2. Malipatil R, Crasta JA. How accurate is intraoperative frozen section in the diagnosis of ovarian tumors? J Obstet Gynaecol Res. 2013;39(3):710-3.

3. Yarandi F, Eftekhari Z, Izadi-Mood N, et al. Accuracy of intraoperative frozen section in the diagnosis of ovarian tumors. *Aust N Z J Obstet Gynaecol.* 2008;48:438-41.
4. Cetin I, Cozzi V, Antonazzo P. Infertility as a cancer risk factor - a review. *Placenta.* 2008;29 (Suppl 2):169-77.
5. Jensen A, Sharif H, Frederiksen K, et al. Use of fertility drugs and risk of ovarian cancer: Danish population based cohort study. *BMJ* 2009;338 (7694):580-3.
6. Protopapa A. Miliary tuberculous peritonitis mimicking advanced ovarian cancer. *Gynecol Obstet Invest.* 2003;56(2):89-92.
7. Tan O, Luchansky E, Rosenman S, et al. Peritoneal tuberculosis with elevated serum Ca-125 level mimicking advanced stage ovarian cancer: a case report. *Arch Gynecol Obstet.* 2009;280:333-5.