

CASE REPORT:**Acute Respiratory Distress Syndrome and septic shock in pregnant woman with COVID-19**Jesselyn Kristanti^{1*}, Fransiscus OH Prasetyadi²¹Emergency Department, Dr Ramelan Naval Hospital, Surabaya, Indonesia, ²Obstetrics and Gynecology Department, Dr Ramelan Naval Hospital, Surabaya, Indonesia**ABSTRACT**

Objectives: To prove that pregnancy do not worsen the clinical course of COVID-19 compared with nonpregnant individuals as found in the first case of COVID-19 pregnant woman died in our center.

Case Report: A 27-year-old female, G2P0A1 23/24 weeks without comorbidities, complaint of diarrhea and 4 days later got fever, cough, and dyspnea. She was referred to our hospital for further evaluation because of deterioration. SARS CoV-2 RT-PCR tested positive. Blood, sputum, and urine cultures tested negative. She was intubated and given LMWH. She was worsened rapidly despite being on intensive care for 3 days with last vital signs recorded: blood pressure 66/24 mmHg with vasopressors, heart rate 136 beats/minutes, temperature 41°C, oxygen saturation 62%, cardiac arrest and expired.

Conclusion: COVID-19 pregnant women need proper care so that they will not fall into conditions such as ARDS and septic shock. Close monitoring on clinical and laboratory course is recommended. We suggest clinicians to be aware so as rapid deterioration and death can be avoided.

Keywords: COVID-19; pregnant woman; ARDS; septic shock

ABSTRAK

Tujuan: Membuktikan bahwa kehamilan tidak memperburuk gejala klinis dari COVID-19 dibanding populasi tidak hamil seperti pada kasus pertama kematian ibu hamil dengan COVID-19 di sebuah rumah sakit.

Laporan Kasus: Wanita 27 tahun G2P0A1 usia kehamilan 23/24 minggu, tanpa komorbid dengan keluhan diare dan 4 hari kemudian mengeluh demam, batuk, dan sesak napas. Lalu dirujuk ke rumah sakit kami karena mengalami perburukan sehingga membutuhkan penanganan lebih lanjut. Hasil swab PCR SARS-CoV-2 positif. Kultur sputum, darah, dan urin tidak menunjukkan pertumbuhan kuman. Pasien terintubasi dan mendapatkan LMWH. Dalam perkembangannya selama 3 hari di ICU, pasien mengalami deteriorasi cepat dengan tanda vital terakhir tekanan darah 66/24 mmHg dengan vasopresor, nadi 136x/menit, suhu 41°C, saturasi oksigen 62%, henti jantung dan tidak tertolong.

Simpulan: Wanita hamil dengan COVID-19 membutuhkan penanganan yang tepat sehingga tidak jatuh pada kondisi seperti ARDS dan syok septik. Pemantauan secara ketat baik klinis maupun laboratorium berkala direkomendasikan. Penulis mengusulkan para klinisi mewaspadai hal tersebut sehingga potensi deteriorasi cepat dan kematian pada wanita hamil dengan COVID-19 dapat dihindari

Kata kunci: COVID-19; wanita hamil; ARDS; syok septik

***Correspondence:** Jesselyn Kristanti, Emergency Department, Dr Ramelan Naval Hospital, Surabaya, Indonesia.
E-mail: fjesselynkrstanti@gmail.com

INTRODUCTION

Coronavirus disease 2019 (COVID-19), a disease caused by SARS-CoV-2, a newly emergent coronavirus, was firstly identified in Wuhan, China, in December 2019.¹ Epidemiology and virologic studies suggest that transmission mainly occurs from symptomatic people to others by close contact through respiratory droplets, by direct contact with infected persons, or by contact with contaminated objects and surfaces.^{2,3} Available data from multiple small series and case Pregnancy and childbirth, according to most studies, do not raise the risk of SARS-CoV-2 infection, do not exacerbate the clinical course of COVID-19 as compared to nonpregnant individuals of the same age, and most (>90 percent) infected mothers recover without giving birth.⁴ In the medical literature, many maternal deaths due to cardio-pulmonary complications, including multiorgan failure, have been recorded.⁵⁻⁷ Most of these women were generally healthy prior to the SARS-CoV-2 infection. This is the first death case of a pregnant woman with COVID-19 in our hospital, specifically a severe one with complications of acute respiratory distress syndrome (ARDS) and septic shock. A permission had been obtained to report this case.

CASE REPORT

This case study reported the circumstances surrounding a pregnant woman who contracted COVID-19 and died as a result of her illness. We presented a case of a 27-year-old female in her second pregnancy at 23/24 weeks gestation with a history of miscarriage on her first pregnancy in October 2019. We did history taking with her husband, he stated that she has been admitted to the previous hospital for 1 week with chief complaint of diarrhea prior to admission, and four days after she was admitted she got additional complaints of fever, cough, and dyspnea and was moved to isolation ward. She did not have any history of hypertension, diabetes, obesity, alcohol use, drug use, or other significant comorbidities. She was referred to our hospital for further management and evaluation because of deterioration. Her RT-PCR swab for SARS-CoV-2 was positive; with blood, sputum, and urine cultures result tests are negative. Due to severe acute respiratory distress syndrome she was intubated and put under mechanical ventilation. She was given azithromycin 500 mg iv qd, chloroquine phosphate 500 mg po bid, oseltamivir 75 mg po bid, vitamin C 1 gram iv qd, other than that she was given low molecular weight heparin (enoxaparin 0.4 ml sc qd). She was worsened rapidly despite being on intensive care for 3 days with last vital signs recorded: blood pressure was 66/24 mmHg with vasopressors, heart rate was 136 beats/minute, temperature 41°C,

oxygen saturation 62% on ventilator. Finally, due to this rapid deterioration, she was on cardiac arrest and expired following unsuccessful cardiopulmonary resuscitative efforts.

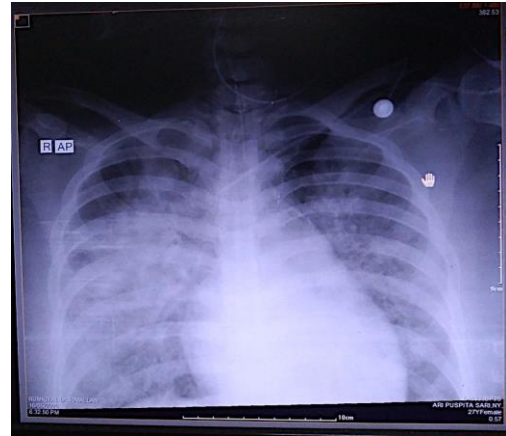


Figure 1. Patient's chest radiology

DISCUSSION

This patient first came with a chief complaint of gastrointestinal symptom (diarrhea) which has been reported in some medical literatures as a possible presenting complaint of COVID-19.^{8,9} Since accumulated evidence supports SARS-CoV-2 transmission via feces, suspected COVID-19 patients with GI symptoms such as nausea, vomiting, and diarrhea should be seriously considered.¹⁰ Four days later she was complaining of fever, cough, and shortness of breath which were the most emphasized symptoms of COVID-19.

Pregnancy and childbirth, according to available evidence from several small series and case reports, do not raise the risk of SARS-CoV-2 infection, do not exacerbate the clinical course of COVID-19 when compared to nonpregnant individuals of the same age, and most (>90 percent) infected mothers recover without giving birth. Older adults, especially those with comorbidities, are those demographically most affected by serious disease, and most pregnant women are younger than middle age; however, they may have comorbid conditions that increase their risk (eg, obesity, diabetes).⁴

It is known that some patients with severe COVID-19 have laboratory evidence of an exuberant inflammatory response (similar to cytokine release syndrome), which has been associated with critical and fatal illnesses.⁴ It is unclear if pregnancy's normal immunologic changes

influence the occurrence and course of this response.⁴ Symptomatic infection can range from mild to critical disease. As for this patient, based on WHO Interim Guidance on Clinical Management of COVID-19 which was published on 27 May 2020, from the COVID-19 disease severity, criteria of critical disease which is severe acute respiratory distress syndrome, sepsis and septic shock is obtained.¹

Severely ill COVID-19 patients are often managed in the prone position in the ICU. While even a semi-prone position can be difficult to place a pregnant woman in the last half of pregnancy, some ICUs have applied this approach to pregnant women.¹¹ and so did in this patient.

This patient was given low molecular weight heparin (enoxaparin). We have learned that coagulopathy is common in patients with severe COVID-19, and both venous and arterial thromboembolism have been reported⁵⁻⁷ so that per WHO recommendation a prophylaxis should be given.¹

An antiviral agent, Remdesivir, is a treatment for COVID-19 which resulted in faster time to recovery.¹² Remdesivir is a novel nucleotide analogue that has activity against severe acute respiratory syndrome coronavirus 2 (SARS-CoV-2) in vitro.¹³ It was not given to this patient as the medication unfortunately is not yet available in our country.

Convalescent plasma which may possible in providing clinical benefit was not given because it is too, not yet available in our hospital by the time the patient was admitted. However, according to a recent randomized controlled trial, convalescent plasma therapy applied to standard treatment did not result in a statistically significant increase in time to clinical improvement within 28 days for patients with serious or life-threatening COVID-19, as compared to standard treatment alone.. Early termination of the experiment, which may have been underpowered to identify a clinically significant difference, has limited the interpretation.¹⁴

CONCLUSION

We report herein the first maternal death in our hospital due to COVID-19. Pregnant women with COVID-19 need proper care so that they will not fall into critical conditions such as ARDS and septic shock. Close monitoring on clinical and laboratory courses is recommended. We suggest clinicians that it is prudent to be aware of the potential of rapid deterioration and maternal death among pregnant women diagnosed with

COVID-19 despite knowing that information about COVID-19 and its management including specific therapy is still evolving rapidly, and interim guidance by multiple organizations is constantly being updated and expanded.

ACKNOWLEDGMENT

We thank Dr Ramelan Naval Hospital staffs for their efforts to deal with COVID-19. We also thank the Almighty God for reasons too numerous to mention. We declare no competing interests.

REFERENCES

1. World Health Organization (WHO). Clinical Management of COVID-19 Interim Guidance 27 May 2020 [Internet]. 2020. Available from: <https://www.who.int/publications/i/item/clinical-management-of-covid-19>
2. Lauer SA, Grantz KH, Bi Q, et al. The incubation period of coronavirus disease 2019 (CoVID-19) from publicly reported confirmed cases: Estimation and application. *Ann Intern Med.* 2020;172(9):577–82.
3. Chan JFW, Yuan S, Kok KH, et al. A familial cluster of pneumonia associated with the 2019 novel coronavirus indicating person-to-person transmission: a study of a family cluster. *Lancet* [Internet]. 2020;395 (10223):514–23. Available from: [http://dx.doi.org/10.1016/S0140-6736\(20\)30154-9](http://dx.doi.org/10.1016/S0140-6736(20)30154-9)
4. Vincenzo B, Lockwood CJ, Barss VA. Coronavirus disease 2019 (COVID-19): Pregnancy issues [Internet]. 2020. Available from: https://www.uptodate.com/contents/coronavirus-disease-2019-covid-19-pregnancy-issues?source=history_widget
5. Karami P, Naghavi M, Feyzi A, et al. Mortality of a pregnant patient diagnosed with COVID-19: A case report with clinical, radiological, and histopathological findings. *Travel Med Infect Dis* [Internet]. 2020;(March):101665. Available from: <https://doi.org/10.1016/j.tmaid.2020.101665>
6. Hantoushzadeh S, Shamshirsaz AA, Aleyasin A, et al. Maternal death due to COVID-19 disease. *Am J Obstet Gynecol* [Internet]. 2020; Available from: <https://doi.org/10.1016/j.ajog.2020.04.030>
7. Ahmed I, Azhar A, Eltaweel N, et al. First Covid-19 maternal mortality in the UK associated with thrombotic complications. *Br J Haematol* [Internet]. 2020;bjh.16849. Available from: <https://onlinelibrary.wiley.com/doi/abs/10.1111/bjh.16849>

8. Jin X, Lian JS, Hu JH, et al. Epidemiological, clinical and virological characteristics of 74 cases of coronavirus-infected disease 2019 (COVID-19) with gastrointestinal symptoms. *Gut*. 2020;1–8.
9. Wang D, Hu B, Hu C, et al. Clinical Characteristics of 138 Hospitalized Patients with 2019 Novel Coronavirus-Infected Pneumonia in Wuhan, China. *JAMA - J Am Med Assoc*. 2020;323(11):1061–9.
10. Holshue ML, DeBolt C, Lindquist S, et al. First case of 2019 novel coronavirus in the United States. *N Engl J Med*. 2020;382(10):929–36.
11. Pacheco LD, Saad A. Ventilator management in critical illness. *Crit Care Obstet*. 2018;215–48.
12. Beigel JH, Tomashek KM, Dodd LE, et al. Remdesivir for the Treatment of Covid-19 - Preliminary Report. *N Engl J Med* [Internet]. 2020; Available from: <http://www.ncbi.nlm.nih.gov/pubmed/32445440>
13. Wang M, Cao R, Zhang L, et al. Remdesivir and chloroquine effectively inhibit the recently emerged novel coronavirus (2019-nCoV) in vitro. *Cell Res*. 2020;30(3):269–71.
14. Li L, Zhang W, Hu Y, et al. Effect of convalescent plasma therapy on time to clinical improvement in patients with severe and life-threatening COVID-19: A randomized clinical trial. *JAMA* [Internet]. 2020; Available from: <http://www.ncbi.nlm.nih.gov/pubmed/32492084>