

CASE REPORT

Early diagnosis and appropriate management of vaginal leiomyoma in rural areas

Ihya Ridlo Nizomy<sup>ID\*</sup>, Pribakti Budinurdjaja<sup>ID</sup>, Ferry Armanza<sup>ID</sup>, Hariadi Yuseran<sup>ID</sup>,  
Joyce<sup>ID</sup>, Inas Tsurayya Fauziah Lahdimawan<sup>ID</sup>

Department of Obstetrics and Gynecology, Faculty of Medicine, Universitas Lambung Mangkurat,  
Ulin Hospital, Banjarmasin, South Kalimantan, Indonesia.

Article Info	ABSTRACT
Received Oct 16, 2023 Revised Jan 10, 2024 Accepted Feb 16, 2024 Published Apr 1, 2024  <b>*Corresponding author:</b> Ihya Ridlo Nizomy <a href="mailto:irinizomy@ulm.ac.id">irinizomy@ulm.ac.id</a>  <b>Keywords:</b> Vaginal leiomyoma Vaginal mass Vaginal tumor Appropriate management Maternal health	<b>Objective:</b> To describe the challenges of early diagnosis and appropriate management of vaginal leiomyoma in rural areas. <b>Case Report:</b> A 26-year-old woman, P1A0, was referred from a rural hospital and presented a chief complaint of vaginal mass. The patient was admitted to the tertiary hospital with suspected malignant vaginal tumor and underwent a biopsy, which revealed leiomyoma on pathological examination. Despite conservative treatment, the mass continued to grow, unaffected by the menstrual cycle, causing discomfort. Following a second hospital admission, the patient underwent surgical management of extirpation and vaginal reconstruction. The microscopic finding of the tumor showed myositis cell proliferation with hyperplastic growth, monotonous nuclei, and variable cell shapes, supporting the diagnosis of vaginal leiomyoma. During postoperative monitoring, there was no vaginal bleeding. Thereafter, on the day following surgery, it was found that the right labium major was swollen. This was treated with anticoagulants, topical NSAIDs, and a sitz bath. The patient was discharged from the hospital in good condition and had an uneventful postoperative recovery. <b>Conclusion:</b> Although the incidence of vaginal leiomyoma is uncommon, precise early diagnosis and appropriate management might improve outcomes, particularly in rural areas.

Copyright: © 2024 Majalah Obstetri & Ginekologi. pISSN:0854-0381 eISSN:2598-1013  
This is an open-access article distributed under the terms of the Creative Commons Attribution License as stated in <https://creativecommons.org/licenses/by-nc-sa/4.0/deed.id>



**How to cite:** Nizomy IR, Budinurdjaja P, Armanza F, et al. Early diagnosis and appropriate management of vaginal leiomyoma in rural areas. Majalah Obstetri & Ginekologi (Journal of Obstetrics & Gynecology Science). 2024;32(1):60-67. doi: 10.20473/mog.V32I12024.60-67.

Highlights:

- 1. Extrauterine leiomyoma, including vaginal leiomyoma, is an exceedingly rare condition with complex pathogenesis and management
- 2. Clinical evaluation and high-quality imaging are required to confirm the diagnosis of vaginal tumor. If there are insufficient facilities, referrals must be made.
- 3. Operative management using vaginal approach was described for treating vaginal leiomyoma.



## INTRODUCTION

Leiomyoma is a benign mesenchymal tumor originating from the clonal proliferation of uterine smooth muscle cells. The uterus is the most typical site. However, it can manifest in any part of the female reproductive system. This tumor is the most common benign gynecological tumor and affects around 30% of women by age 30. Extrauterine leiomyoma is a very uncommon condition characterized by complex pathogenesis and management.<sup>1</sup>

Diagnosing extrauterine leiomyoma can be somewhat difficult due to its histological characteristics as a benign tumor that originates from smooth muscle cells. It often develops in the genitourinary tract, including the vulva, ovaries, urethra, and vagina. Alternatively, it may also arise in close proximity to other anatomical structures within the genitourinary system. Unusual growth patterns of leiomyoma beyond the uterus include the benign leiomyoma metastasis, peritoneal leiomyomatosis, intravenous leiomyomatosis, parasitic leiomyoma, and retroperitoneal growth.<sup>1,2</sup>

Vaginal leiomyoma is an exceptionally uncommon neoplasm. Vaginal leiomyoma commonly affects individuals between the ages of 19 and 70, with tumor sizes ranging from 0.5 to 15 cm in diameter. Vaginal leiomyoma typically occurs on top the anterior mid-vaginal wall and is generally smaller than 6 cm in size. The recommended treatment option is surgical excision of the mass through the vagina, which has a low chance of recurrence.<sup>3-5</sup> This case report outlines a successful surgical treatment of a vaginal leiomyoma by removing the tumor with excision and enucleation using a vaginal approach.

## CASE REPORT

A 26-year-old woman, P1A0, was referred from Central Kalimantan's rural hospital with a diagnosis of vaginal wall solid tumor. The patient complained of a solid mass in the right vaginal canal for the past month, rapidly increasing in size, accompanied by vaginal discharge. The patient also reported discomfort, especially when sitting or standing. The patient confirmed the ability to have sexual intercourse, and there was no pain during intercourse. On gynecological examination, a solid mass was found on the right lateral vaginal wall, measuring approximately 4 cm, fixed to the surrounding area. The mass had a smooth surface and no tenderness upon palpation. Initially the gynecologist suspected this as a malignancy due to the mass being fixated to the lateral vaginal wall, although standard equipment for gynecologic examination such as speculum, and pelvic examination table were present at the time in the referring hospital, malignancy still need to be excluded. Lack of urogynecologist and gynecologic-oncologist pose a challenge in diagnosing this type of vaginal mass. Upon consideration of facility and need for further investigation by consultants, the patient was decided to be referred to the tertiary hospital. Availability of MRI and definitive surgery by urogynecologist were the main reason for referral.

The patient was admitted to a tertiary hospital and underwent a biopsy of the vaginal solid mass, suspected malignancy, by oncogynecologist which revealed leiomyoma in the vaginal region (Figure 1). The patient was then referred to an urogynecologist. Upon re-evaluation, the mass had enlarged to 6 cm and was accompanied by pain in the mass area, with a VAS of 3-4. Subsequently, a pelvic MRI was performed.

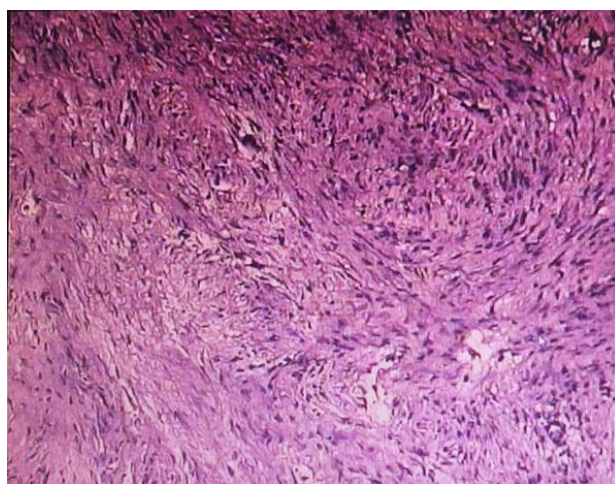


Figure 1. Biopsy histopathological finding consistent with a leiomyoma.

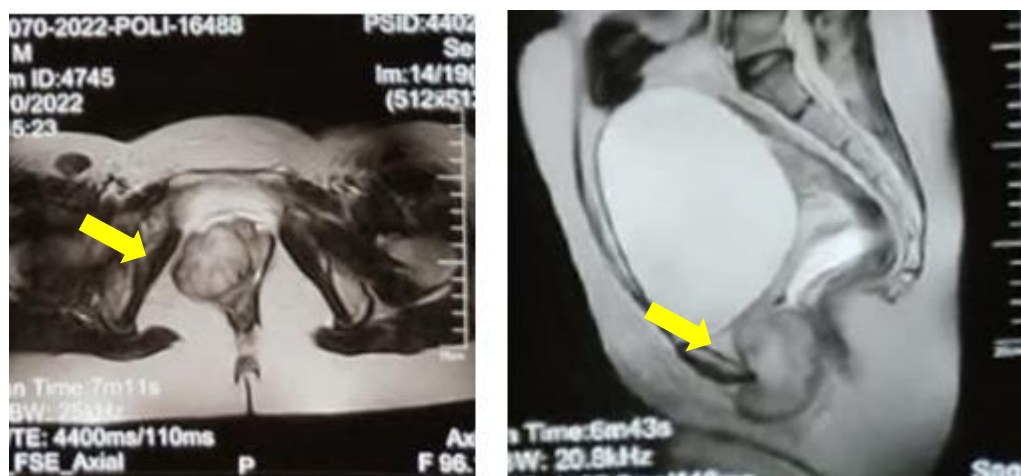


Figure 2. Pelvic MRI results (see yellow arrows).

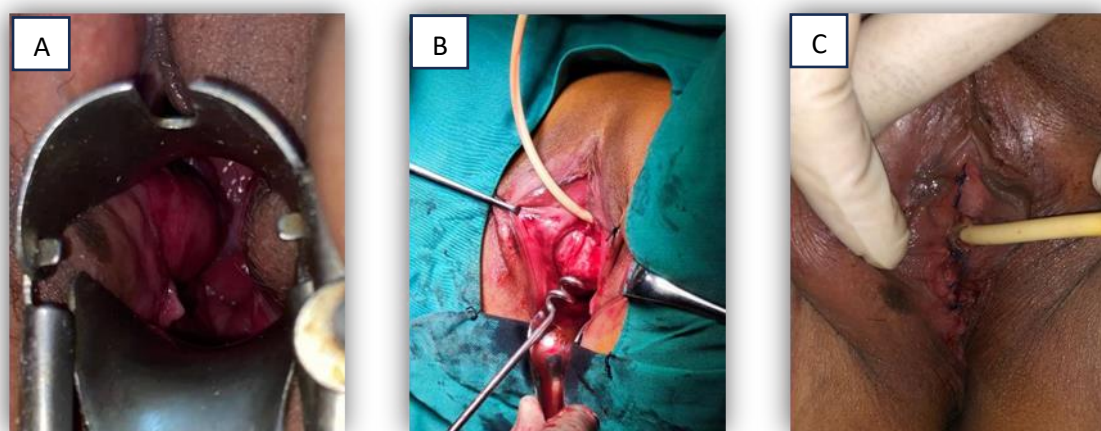


Figure 3A-C. Clinical pictures during preoperative (A), intraoperative (B), and postoperative (C) phases.

The MRI results concluded that there was a solid mass in the anterolateral right vaginal wall, suggestive of either a Bartholin gland mass, vaginal fibromyolipoma, or chronic abscess. The solid mass appeared to be unrelated to the surrounding bones (Figure 2).

The surgery was conducted four months after the biopsy (Figure 3A-C). During the intraoperative evaluation, a solid mass with a smooth surface was found on the upper lateral wall of the vagina, measuring 10 x 6 x 5 cm, attached to the M. bulbocavernosus, extending inferiorly to the pubic bone (right side), with its peak

surpassing the posterior part of the pubic symphysis (Figure 4A). The medial part of the mass was adherent to the urethral wall (right side) up to the bladder neck, while the lower part was free. Subsequently, the leiomyoma was excised (Figure 4B), and lateral vaginal wall reconstruction was performed. The excised mass was sent for histopathological examination. The results revealed a mass measuring 12 x 10 x 8 cm, consisting of myositis cell proliferation with hyperplastic growth, monotonous nuclei, and variable cell shapes, supporting the diagnosis of vaginal leiomyoma (Figure 5).

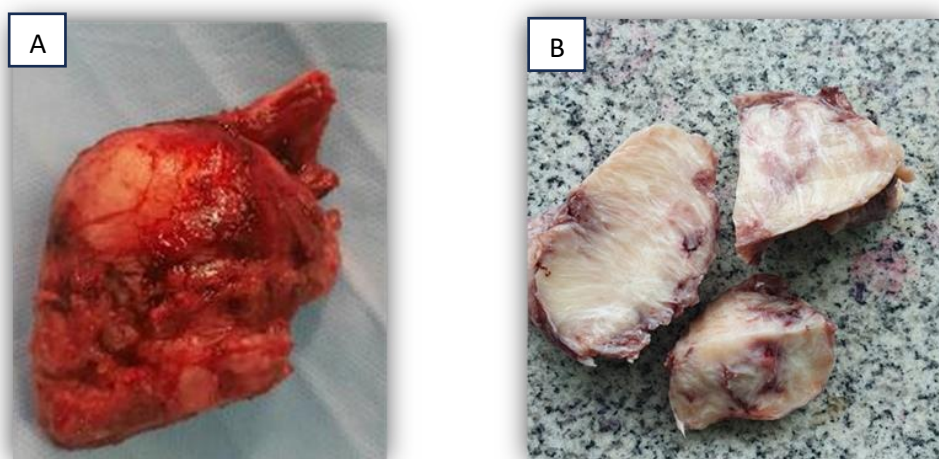


Figure 4A and B. Specimen of the mass.

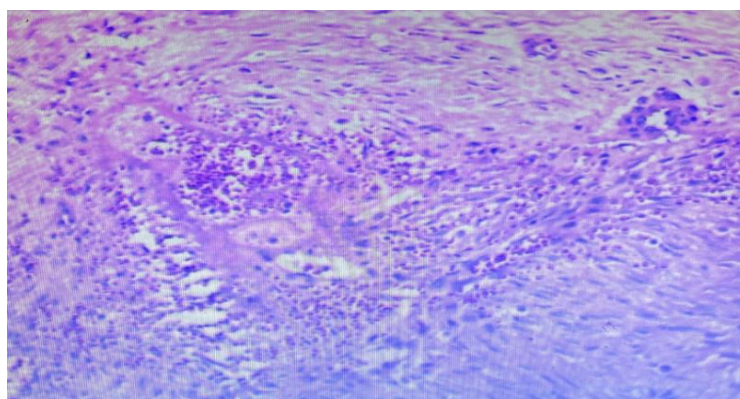


Figure 5. Mass histopathological result supporting a vaginal leiomyoma.

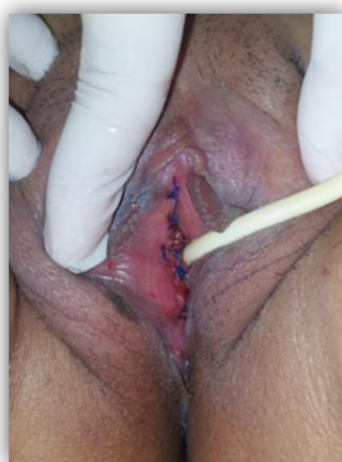

Figure 6. Postoperative day 7, no vaginal bleeding and good wound healing.

Following surgery, the patient spent four days in postoperative care, receiving antibiotics, analgesics, anti-inflammatories, and a one-time 24-hour vaginal tampon insertion. No vaginal bleeding was seen (Figure 6). Right labia majora swelling, however, occurred on the first day following surgery and was treated with topical anticoagulants, NSAIDs, and sitz baths. The patient was able to urinate on her own after the foley catheter was removed after three days of indwelling. The swelling of the right labia majora gradually diminished, and the patient was discharged.

## DISCUSSION

Vaginal leiomyoma is a rare condition, with a total of approximately 330 cases reported since its initial discovery in 1733 by Denys de Leyden. Vaginal leiomyoma primarily affects women between the ages of 35 and 50 and is more prevalent among individuals of Caucasian ethnicity. Vaginal mesenchymal tumors are highly prevalent. Vaginal leiomyoma commonly develops on the front part of the middle vaginal wall and infrequently on posterior vaginal wall. Typically, it manifests as a solitary, clearly delineated mass. Leiomyomas are frequently found in the female reproductive system, mostly in the uterus, to a lesser extent in the cervix, and also in the round ligament, utero-sacral ligament, ovary, and inguinal canal.<sup>6-8</sup>

The exact pathogenesis of vaginal leiomyoma develops is yet unknown. However, it is believed to be controlled by hormones, which means that it may regress during menopause. Vaginal leiomyoma exhibits same macroscopic and microscopic characteristics to uterine leiomyoma. Most published reports suggest that vaginal leiomyoma is not thought to come from myometrial cells. Instead, it is believed to develop from several sources such as vaginal smooth muscle, rectum, bladder, urethra, smooth muscle blood vessels, or embryonic remains within the vagina. Vaginal leiomyoma can manifest either as a component of other leiomyomas or as an independent occurrence.<sup>5,7</sup>

A retrospective study investigated twenty-six patients with vaginal leiomyoma.<sup>9</sup> Smooth muscle actin (SMA), S-100 protein (calcium-binding protein), CD34 (cluster of differentiation 34), ER (Estrogen receptor), and EGFR (Epidermal growth factor receptor) were detected using S-P immunohistochemistry. Immunohistochemical staining revealed a high positive expression of SMA and a negative expression of S-100 protein and CD 34 in all cases. The expression of ER and EGFR was positive in 38.5% (10 out of 26 cases) and 34.6% (9 out of 26 cases) respectively. A strong association was seen

between the expression of ER and EGFR. The study determined that estrogen hormone and EGF (epidermal growth factor) likely have a crucial function in the development and growth of vaginal leiomyoma.

The clinical manifestations of vaginal leiomyoma differ according on the size and location of the tumor. The most common complaint is the presence of a mass protruding from the vagina. Additional symptoms may include abdominal discomfort, vaginal discharge, dyspareunia (pain during sexual intercourse), infertility, frequent urination, inability to completely empty the bladder, urinary tract infections (UTIs), dysmenorrhea (painful menstruation), abnormal uterine bleeding, and pain in the right iliac fossa. Vaginal tumors can vary in size, ranging from 2 cm to as large as the umbilicus. These tumors have the potential to cause infection, necrosis, or rapid growth that resembles malignancy.<sup>10</sup> In our case, the main complaint was a rapidly enlarging mass in the vaginal canal with associated pain, no dyspareunia, and no urinary disturbances.

In the evaluation, it is important to differentiate between vaginal leiomyoma and malignancy. Establishing a diagnosis can be challenging due to the various clinical symptoms and diverse clinical manifestations of the tumor. Therefore, evaluation is necessary to distinguish vaginal leiomyoma from malignancy. A solid vaginal tumor can be identified through a physical examination, and it is important to differentiate it from other solid tumors in the vagina, such as fibroepithelial polyp, condyloma acuminatum, urethral leiomyoma, skene duct abscess, or, in rare cases, vaginal malignancy. The precise location of a solid mass can help to exclude differential diagnosis. When there is a solid mass positioned in half of the vagina, an examination is necessary to determine between vaginal leiomyoma, vaginal cyst, or uterine prolapse.<sup>11-13</sup>

Several diagnostic procedures such as transabdominal ultrasound (US), transvaginal US, translabial US, and MRI can be used to distinguish between vaginal leiomyoma and cancer. Magnetic Resonance Imaging (MRI) is advantageous for quickly proliferating leiomyomas that are difficult to visualize with Ultrasonography (US) and when there is a suspicion of malignancy. MRI is a highly reliable method for identifying leiomyoma, with a sensitivity ranging from 88% to 93% and a specificity ranging from 66% to 91%. MRI is a useful tool for identifying the location of a mass, determining the size of the mass, and distinguishing the composition of the mass. Magnetic resonance imaging (MRI) usually reveals a clearly defined, solid mass with signal intensity that falls between T1 and T2, and exhibits uniform enhancement

when contrast is applied. On the other hand, leiomyosarcomas and other types of vaginal cancers typically show an intense signal on T2 imaging, have irregular margins, and heterogeneous contrast enhancement in areas of necrosis or hemorrhage. Leiomyomas that are undergoing degeneration may exhibit regions with a high T2 signal intensity, suggesting a combination of swollen, deprived of blood myoma cells, cystic alterations, or myxoid degeneration.<sup>3,6,7,14</sup>

Several studies have indicated increased levels of tumor markers, including Ca125, Ca19-9, and Ca15.3, in respectively 19.7%, 6.6%, and 5.1% of women diagnosed with vaginal leiomyoma, as observed in laboratory tests. Additional studies have shown that increased LDH levels are significant in the preoperative diagnosis of sarcoma. In our case, however, laboratory studies for tumor markers were not performed.<sup>3</sup>

Biopsy or fine-needle aspiration biopsy (FNAB) can be performed preoperatively for diagnostic confirmation. Histopathological confirmation is the gold standard for diagnosis with an ability to rule out any potential focus of malignancy. Vaginal leiomyoma consists of spindle-shaped cells with elongated and oval nuclei with minimal mitotic activity. The presence of atypical cells, hypercellularity, and numerous mitoses indicates malignancy on histopathological examination.<sup>6,7,15</sup>

In our case, the MRI results showed a mass with an isointense signal on T1W1 and T2W1 with relatively well-defined borders, seemingly surrounded by fat, no connection to the surrounding bones, and a size of 5.85x6.03x4.04 cm, located in the right anterolateral wall of the vagina. This mass exhibited mild inhomogeneous enhancement on T1 with contrast. Vaginal leiomyoma can be diagnosed precisely when MRI shows low signal intensity on T1 and T2 weighted images. However, the pathognomonic findings in MRI will change depending on histological changes. Preoperative biopsy results indicated a tumor mass composed of round, oval, and spindle-shaped cells grouped in fascicles, with cell nuclei within normal limits and no malignant cells, supporting the diagnosis of vaginal leiomyoma.<sup>16,17</sup>

The management of this tumor typically involves vaginal enucleation in most cases, but sometimes an abdominopelvic approach may be required depending on the size and location of the mass. An abdominal approach is also performed in cases where the tumor is located proximally in the vagina and the upper part of the tumor cannot be reached via the vaginal route. If vaginal leiomyoma is diagnosed before surgery, GnRH analogs or selective progesterone receptor modulators

(SPRMs) may be administered to shrink the mass, and an embolization before surgery has also been reported to reduce mass vascularity, thereby reducing intraoperative bleeding. The operator should consider the risk of urethral or bladder injury during vaginal surgery. A urethral catheter insertion during tumor removal surgery via vaginal approach is preferred to prevent urethral injury.<sup>3,4,6,7,18</sup>

Hemostatic suturing and proper closure are necessary following effective mass removal to avoid dead spaces. In this case, mass enucleation was performed by making a vertical incision parallel to the labia on the distal vaginal wall, 5 cm above the tumor mass, until the myoma capsule was visible. A myoma screw was placed to pull the mass. Subsequently, sharp and blunt extirpation of the myoma tissue was carried out until the mass was detached from the surrounding tissue. A foley catheter was placed as a marker before freeing the mass attached to the right urethral wall. Sutures were used to provide hemostatic care after the mass was removed. An absorbable hemostatic gelatin sponge was applied, and then the reconstruction of the lateral vaginal wall was performed with layered sutures using PGA 2.0. Histopathological examination for diagnosis confirmation is crucial to rule out malignancy. After surgery, it is recommended for an indwelling 24 hours foley catheter to be inserted for overseeing visceral injuries. Vaginal packing placement could also be implemented for hemostasis.<sup>6,19</sup>

Routine postoperative monitoring is required to evaluate recurrences. Furthermore, several studies have reported sexual intercourse disturbances following the diagnosis and management of vaginal tumors. Therefore, psychological support is essential to improve sexual function and quality of life.<sup>20</sup>

Rural areas refer to regions that are distinct from urban areas. These locations typically consist of habitats surrounded by trees in forests, accessible via footpaths or, at most, unpaved or previously paved roads. The residents are primarily composed of peasant farmers, low-grade artisans, and other individuals with modest incomes.<sup>21</sup> The obstetric and gynecologist in rural areas is involved in general obstetric and gynecologic surgery. Due to the unique setting, they may also perform procedures in urogynecology, oncology, reproductive-endocrinology-infertility, and maternal-fetal medicine.

Patients may undergo incomplete investigations due to a lack of facilities, necessitating outsourcing with added inconvenience and higher costs for the patient. To address this issue, it is essential to have trained consultants working in rural areas, either on a full-time or part-time basis. This approach aims to minimize the

time lost in referring patients to distant tertiary hospitals and enhance the overall quality of service. As for our patient, she needed further investigation not only by general obstetrician and gynecologist but also urogynecologist and oncogynecologist. She was referred to the tertiary hospital which took hours by road in consideration to seek urogynecology consult and biopsy. Further management also done in the same tertiary hospital. Challenges such as transportation, funds, and time from referral until complete case management remain a problem especially during the Indonesian universal health coverage program as referral needed multiple sequence starting from primary health care facility until it reaches the tertiary care facility.

This is the first case report for vaginal leiomyoma in Indonesia. We tried to provide insights on how to diagnose and manage vaginal leiomyoma case, especially in a resource-limited area. The limitation of this study was that tumor markers such as Ca 125, Ca19-9, Ca15.3, and LDH were not examined to rule out the diagnosis of malignancy.

## DISCLOSURES

### Acknowledgment

We would like to express our gratitude to Ulin Hospital and Faculty of Medicine, Universitas Lambung Mangkurat, who have facilitated this report. We would also like to thank all staffs of Department of Pathological Anatomy and Department of Radiology, Ulin Hospital, for their help gathering the images needed to support our case study.

### Conflict of interest

The authors report no conflicts of interest in this work.

### Patient consent for publication

Written informed consent was obtained from the patient for publication of this case report and any accompanying images.

### Funding

This research has no receive no external funding.

### Author contribution

All authors have contributed to all process in this research, including preparation, data gathering, drafting and approval for publication of this manuscript.

## REFERENCES

1. Tang Y, Nadarajah R. Challenges in the diagnosis and treatment of extrauterine leiomyomas: case series. *Int J Reprod Contracept Obstet Gynecol*. 2021;11(1):232-6. doi: [10.18203/2320-1770.ijrcog.20215109](https://doi.org/10.18203/2320-1770.ijrcog.20215109).
2. Chen M, Li Y, Chi Y, et al. Diagnosis and management of vaginal leiomyoma: a case report and literature review. *Ginek Pol*. 2023;94(10): 858-61. doi: [10.5603/GP.a2022.0145](https://doi.org/10.5603/GP.a2022.0145). Epub 2023 Jan 4. PMID: 36597753.
3. Egbe TO, Kobenge FM, Metogo JAM, et al. Vaginal leiomyoma: medical imaging and diagnosis in a resource low tertiary hospital: case report. *BMC Womens Health*. 2020;20(1):12. doi: [10.1186/s12905-020-0883-2](https://doi.org/10.1186/s12905-020-0883-2). PMID: 31964370; PMC ID: PMC6975035.
4. Costa C, Barba M, Cola A, et al. Transvaginal excision of vaginal paraurethral leiomyoma: A video case report. *Eur J Obstet Gynecol Reprod Biol*. 2023;290:11-3. doi: [10.1016/j.ejogrb.2023.09.008](https://doi.org/10.1016/j.ejogrb.2023.09.008). Epub 2023 Sep 11. PMID: 37708657.
5. Dunphy L, Wood F, Siraj M, et al. Leiomyoma presenting as an anterior vaginal mass. *BMJ Case Rep*. 2023;16(3):e253081. doi: [10.1136/bcr-2022-253081](https://doi.org/10.1136/bcr-2022-253081). PMID: 36863759; PMCID: PMC9990660.
6. Wethmar EI, D Mouton A, Dreyer G. Vaginal leiomyoma presenting as a lateral vaginal wall mass. *Southern African Journal of Gynaecological Oncology*. 2017;9(1):16–8. doi: [10.1080/20742835.2017.1314630](https://doi.org/10.1080/20742835.2017.1314630).
7. Harada K, Ishikawa Y, Fujiwara H, et al. Female paraurethral leiomyoma successfully excised through a vaginal approach: A case report. *J Obstet Gynaecol Res*. 2018;44(6):1174-6. doi: [10.1111/jog.13641](https://doi.org/10.1111/jog.13641). Epub 2018 Apr 2. PMID: 29607582.
8. Kant RH, Mir N, Sharma P, Najeel R. Vaginal Wall Leiomyoma: A Rare Entity-Case Report Case Report. *IOSR Journal of Dental and Medical Sciences (IOSR-JDMS)*. 2015;14(5):60–1. doi: [10.9790/0853-14556061](https://doi.org/10.9790/0853-14556061).
9. Asnani M, Srivastava K, Gupta HP, et al. A rare case of giant vaginal fibromyoma. *Intractable Rare Dis Res*. 2016;5(1):44-6. doi: [10.5582/irdr.2015.01037](https://doi.org/10.5582/irdr.2015.01037). PMID: 26989649; PMCID: PMC4761584.
10. Patil RR, Vijay NR, Joshi S. An unusual presentation of vaginal leiomyoma. *J Midlife Health*. 2019;10(4):204-5. doi: [10.4103/jmh.JMH\\_40\\_19](https://doi.org/10.4103/jmh.JMH_40_19). PMID: 31942157; PMCID: PMC6947721.
11. Woo J, Choi SY, Kim HK, et al. Extremely Rare CT and MRI Findings of Peritoneal Leiomyoma Mimicking Hepatic Mass: A Case Report. *J Korean Soc Radiol*. 2023;84(4):946-51. doi: [10.3348/jksr.2022.0032](https://doi.org/10.3348/jksr.2022.0032). Epub 2023 Jul 10. PMID: 37559801; PMCID: PMC10407062.



12. Ashraf Muhammed P, Karim HA, Majeed NG, et al. A rare case of benign vulvovaginal leiomyoma: Case report and literature review. *Ann Med Surg (Lond)*. 2022;77:103720. doi: [10.1016/j.amsu.2022.103720](https://doi.org/10.1016/j.amsu.2022.103720). PMID: 35637979; PMCID: PMC9142705.
13. Singh R, Yadav P, Kaur H. Vaginal leiomyoma: A rare presentation. *Journal of SAFOG*. 2014;6(2): 112–3. doi: [10.5005/jp-journals-10006-1284](https://doi.org/10.5005/jp-journals-10006-1284).
14. Gupta A, Gupta MM, Manaktala U. Vaginal leiomyoma: MRI features with pathologic correlation. *Egyptian Journal of Radiology and Nuclear Medicine*. 2015;46(2):507–9. doi: [10.1016/j.ejrnrm.2015.01.010](https://doi.org/10.1016/j.ejrnrm.2015.01.010).
15. Ning Y, Ling R, Zhang F, et al. Common and uncommon lesions of the vulva and vagina on magnetic resonance imaging: correlations with pathological findings. *BJR Open*. 2023;5(1): 20230002. doi: [10.1259/bjro.20230002](https://doi.org/10.1259/bjro.20230002). PMID: 37389007; PMCID: PMC10302693.
16. do Amaral CC, Castro PT, Frota R, et al. Vaginal leiomyoma: Advantages of clinical sonovagino-graphy and ultrasound dynamic evaluation of uterine cervix-related lesions. *J Clin Ultrasound*. 2023;51(9):1509-11. doi: [10.1002/jcu.23580](https://doi.org/10.1002/jcu.23580). Epub 2023 Oct 6. PMID: 37800472.
17. Gao Y, Qin Y, Li J, et al. Vaginal leiomyoma: A case report. *Exp Ther Med*. 2022;24(5):661. doi: [10.3892/etm.2022.11597](https://doi.org/10.3892/etm.2022.11597). PMID: 36168424; PMCID: PMC9475341.
18. Agarwal S, Trigunait P, Meena M. A rare case of vaginal fibroid presenting as urethrocele. *Indian Journal of Basic and Applied Medical Research* [Internet]. 2016;(5):824–7. Available from: <https://www.ijbamr.com/assets/images/issues/pdf/march%202016%20824-827.pdf.pdf>
19. Costa C, Barba M, Cola A, et al. Transvaginal excision of vaginal paraurethral leiomyoma: A video case report. *Eur J Obstet Gynecol Reprod Biol*. 2023;290:11-3. doi: [10.1016/j.ejogrb.2023.09.008](https://doi.org/10.1016/j.ejogrb.2023.09.008). Epub 2023 Sep 11. PMID: 37708657.
20. Nowosielski K, Pałka A. Couples' sexual health after gynaecological cancer diagnosis - an unexplored area for further research. *Contemp Oncol (Pozn)*. 2023;27(1):47-56. doi: [10.5114/wo.2023.127308](https://doi.org/10.5114/wo.2023.127308). Epub 2023 Apr 27. PMID: 37266338; PMCID: PMC10230241.
21. Umunna J. The scope and challenges of rural surgical practice in Nigeria. *Nigerian Journal of Surgery*. 2011;17(1):25-8. doi: [10.4314/njs.v17i1.70708](https://doi.org/10.4314/njs.v17i1.70708).