

ORIGINAL ARTICLE:**Ovarian cancer with pleural and lung metastasis in Dr. Soetomo Hospital, Surabaya, Indonesia, in 2014-2015**Fitria Khusnul Khotimah*¹, Anna Febriani², Pungky Mulawardhana¹¹Department of Obstetrics and Gynecology, ²Department of Pulmonology, Faculty of Medicine, Universitas Airlangga, Dr. Soetomo Hospital, Surabaya, Indonesia**ABSTRACT**

Objectives: To know the characteristics of ovarian cancer patients with pleural and lung metastasis, and survival rates of ovarian cancer patients with pleural and lung metastasis in Dr. Soetomo Hospital Surabaya in 2014-2015.

Materials & Methods: This was a descriptive observational study using secondary data from medical records in Dr. Soetomo Hospital, Surabaya, Indonesia, in 2014 and 2015

Results: Number of new patients of ovarian cancer in Dr. Soetomo Hospital, Surabaya in 2014 was 170 patients (14%) and 122 patients (12%) in 2015. Ovarian cancer patients most often came at the stage IIIC (33.38%) with the most histopathological type was epithelial ovarian cancer. There were 5 patients with ovarian cancer with pleural metastasis and 7 patients with lung metastasis. Pleural metastasis was 80% diagnosed at the time of ovarian cancer's diagnosis, whereas 57.15% of lung metastasis were diagnosed >12 months after the ovarian cancer's diagnosis. Pleural metastasis was established by pleural fluid cytology, while lung metastasis with radiological features and/or biopsies. The most common feature of lung metastasis was nodal (71.42%). Ascites was found in 80% of ovarian cancer with pleural metastasis, but only 42.86% in lung metastasis. In 2 patients receiving NAC chemotherapy and continued by interval debulking, both had negative residues. Median survival rate in ovarian cancer with pleural metastasis was 7 months, whereas in lung metastasis was 12 months.

Conclusions: Number of new patients of ovarian cancer in 2014-2015 in Dr. Soetomo Hospital was on rising and was the second largest number of visits after cervical cancer. In 2014-2015, there were 5 patients with ovarian cancer and pleural metastasis and 7 patients with ovarian cancer patients and lung metastasis. Median survival rate in ovarian cancer with pleural metastasis was 7 months, whereas in lung metastasis it was 12 months.

Keywords: Ovarian cancer; pleural metastasis; lung metastasis

ABSTRAK

Tujuan: Mengetahui karakteristik penderita kanker ovarium dengan metastasis pleura dan paru, dan tingkat ketahanan hidup penderita kanker ovarium dengan metastasis pleura dan paru di Dr. Soetomo Hospital Surabaya pada tahun 2014-2015.

Bahan dan Metode: Penelitian observasional deskriptif menggunakan data sekunder dari rekam medis di Dr. Soetomo Hospital Surabaya, Indonesia, pada tahun 2014 dan 2015.

Hasil: Jumlah penderita baru kanker ovarium di Dr. Soetomo Hospital Surabaya pada tahun 2014 dan 2015 adalah 170 (14%) dan 122 (12%) pasien. Pasien kanker ovarium paling sering datang pada stadium IIIC (33,38%) dengan tipe histopatologi paling banyak adalah kanker ovarium epitelial. Ada 5 pasien dengan kanker ovarium dengan metastasis pleura dan 7 pasien dengan metastasis paru. Sebanyak 80% metastasis pleura didiagnosis pada saat diagnosis kanker ovarium, sedangkan 57,15% metastasis paru didiagnosis >12 bulan setelah diagnosis kanker ovarium. Metastasis pleura ditegakkan dengan sitologi cairan pleura, sedangkan metastasis paru dengan gambaran radiologis dan/atau biopsi. Fitur yang paling umum dari metastasis paru adalah nodal (71,42%). Asites ditemukan pada 80% kanker ovarium dengan metastasis pleura, tetapi hanya 42,86% pada metastasis paru. Pada 2 pasien yang menerima kemoterapi NAC dan dilanjutkan dengan interval debulking, keduanya memiliki residu negatif. Tingkat kelangsungan hidup rata-rata pada kanker ovarium dengan metastasis pleura adalah 7 bulan, sedangkan pada metastasis paru 12 bulan.

Simpulan: Jumlah penderita baru kanker ovarium tahun 2014-2015 di Dr. Soetomo Hospital terus meningkat dan merupakan jumlah kunjungan terbesar kedua setelah kanker serviks. Pada 2014-2015, ada 5 pasien kanker ovarium dengan metastasis pleura dan 7 pasien kanker ovarium dengan metastasis paru. Angka kelangsungan hidup rata-rata pada kanker ovarium dengan metastasis pleura adalah 7 bulan, sedangkan pada metastasis paru 12 bulan.

Kata kunci: kanker ovarium; metastasis pleura; metastasis paru

***Correspondence:** Fitria Khusnul Khotimah, Department of Obstetrics and Gynecology, Faculty of Medicine, Universitas Airlangga, Dr. Soetomo Hospital, Surabaya, Jl Prof. dr. Moestopo 6-8, Surabaya 60286, Indonesia. Phone: +62816560312, Email: fit.khusnul@gmail.com

INTRODUCTION

The GLOBOCAN 2012 data by World Health Organization (WHO) stated that ovarian cancer was the sixth cause of cancer in women in all over the world, with incidence rate was 3.6%, mortality rate were 4.3% and 5 years survival rate was only 3.4%. Cancer patients data in Indonesia were not sufficient enough, but it was estimated that there were 347.792 cancer patients in the year 2013 (1.4%), and mostly were breast and cervical cancer. Ovarian cancer were divided into two types, which is epithelial and non epithelial ovarian cancer. Between those two types, epithelial ovarian cancer was more common (85–90%).¹

The majority of ovarian cancer patients had unspecific sign and symptoms. At advanced stage, the most common sign and symptoms were the effects of ascites, omental metastasis or intestinal metastasis which is enlargement of the abdomen, nausea, constipation, and anorexia. These symptoms usually occurred in advanced stage.¹

Ovarian cancer was related to parity and infertility, eventhough there were other risk factors. Early menarche and late menopause increase the risk of ovarian cancer. Genetic factor was also play important role as ovarian cancer risk factors. Hereditary ovarian cancer was related to the mutation of BRCA-1 gene that was located in chromosome 17 and BRCA-2 gene in chromosome 13. Both of those gene were related to the incidence of ovarian and breast cancer.¹

Tumor marker value and ultrasonography as screening tool of ovarian cancer had not been established with prospective research. Annual pelvic clinical examination had disappointed results as screening tool. CA 125 was usefull to monitor epithelial ovarian cancer during chemotherapy, but CA 125 role as screening tool is still debatable, because CA 125 was also increased in other condition.¹

Ovarian cancer diagnosis was established by exploration laparotomy. Pre-surgery examination must be done to eliminate the possibility from other organ. In advanced stage ovarian cancer, the management was not different with early stage, but the clinical condition and tumor residue size must be considered. Most of the advanced stage ovarian cancer patients received empirical chemotherapy for few cycles. If the clinical condition of the patients was stable, the surgical management was done to take the tumor as much as possible. This surgery was called cytoreduction or debulking.¹

The outcome of epithelial ovarian cancer can be seen as survival rate and it was effected by some risk factors.

Morphology and histology of the cancer including structure and grade were important prognosis factors. Clinically, tumor residue size, rupture of the tumor capsul before the surgery, ascites volume, patient's age, and patient's clinical performance could determine the patient's prognosis. Five years survival rate of ovarian cancer were 94% in stage I, 73% in stage II, and 28% in stage III and IV.¹

Metastasis is the ability of the cell to leave the primary tumor and enter the circulation to distant organ and form the secondary tumor. This process was a result of cancer cell adaptation to micro environment of distant organ. Stephen Paget (1889) stated that metastatic process was not a random process but because of intrinsic factors from ther cancer cell and respon from the microenvironment of the secondary organ. The compatibility between the cancer cell and microenvironment cause this metastaic process to succeed. This theory was known as "seed and soil hypothesis".⁶

A tumor cell for metastasis must undergo a series of events: (1) escape from the primary mass, (2) invade the surrounding tissue stroma, (3) penetration of blood vessels and local lymph vessels, (4) persist in the circulation, (5)) stops in capillaries or venules in other organs, (6) penetration of the nearby parenchyme, (7) adapts to new colonies or alters localized microenvironment according to tumor cell needs, (8) divides to form new tumor mass.⁷ Epithelial ovarian cancer spread due to the release of cancer cells to the peritoneal cavity, lymphatic spreading, and hematogenous spread. Transcoelomic spread is the most common type of epithelial ovarian cancer and is due to the escape of epithelial cancer cells and attaches to the surface of the peritoneal cavity.¹

Pleural metastasis was established by the presence of cancer cells in the pleural fluid, and also called malignant pleural effusion. Malignant pleural effusions reflect an advanced stage and generally have a poor prognosis. Thoracentesis diagnosis was the most commonly performed method for diagnosing metastasis into the pleural cavity. Pleural fluid cytology sensitivity ranges from 62-90%. The choice of therapy for pleural effusion is by pleural fluid drainage.⁸

Lung metastasis were tumors of the lung parenchyme originating from extra-pulmonary sites and have no association with primary tumors of the lung. A typical radiologic feature lung metastasis was the presence of multiple nodules with firm borders, located in peripheries (hematogenic spread) or interstitial thickening (lymphangitic carcinomatosis). A routine thoracic photo in patients with malignancy is an effective mechanism in detecting lung metastasis. CT scans provide a higher

resolution, and sometimes show additional lesions that are not visible in ordinary thoracic photographs. Sputum examination, bronchial washes, transtracheal, transbronchial, or transthoracic fine needle aspiration are helpful in the diagnosis of lung metastasis as well as in primary lung cancer.⁹⁻¹⁰

MATERIALS AND METHODS

This research was observational descriptive research with secondary data from medical records. The subjects of this research were patients that were diagnosed with ovarian cancer with lung metastasis and/or pleural metastasis in dr. Soetomo Hospital Surabaya between 2014-2015. The data were collected from the medical records from Obstetric and Gynecologic Department of dr. Soetomo Hospital Surabaya.

RESULTS AND DISCUSSION

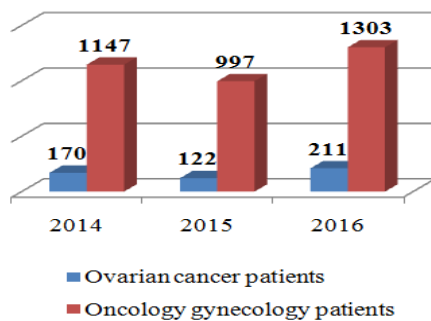


Figure 1. Ovarian cancer patients in dr. Soetomo Hospital Surabaya periode 2014-2016

Number of visits of ovarian cancer patients in Dr. Soetomo Hospital increased from 2014 to 2016. In 2014, 170 patients were visited with a diagnosis of ovarian cancer, this number had decreased in 2015 with the number of visits were 122 patients, and again increased in 2016 with 211 patients. The number of visits of ovarian cancer patients ranks second visit of new patients in Dr. Soetomo Hospital 2014-2015 after cervical cancer (14% in 2014 and 12% in 2015).

Patients with ovarian cancer in 2014-2015 most often came at the stage IIIC (39.38%) followed by the IC stadium (26.30%). Patients who came in the early stages of IA and I B were only 8.22% and 1.03%. Patients with ovarian cancer who had a distant metastasis or stage IV were 1.71% in stage IV A and 5.14% in stage

IVB and there were 2.74% of unstage cancer patients (not yet underwent surgical staging).

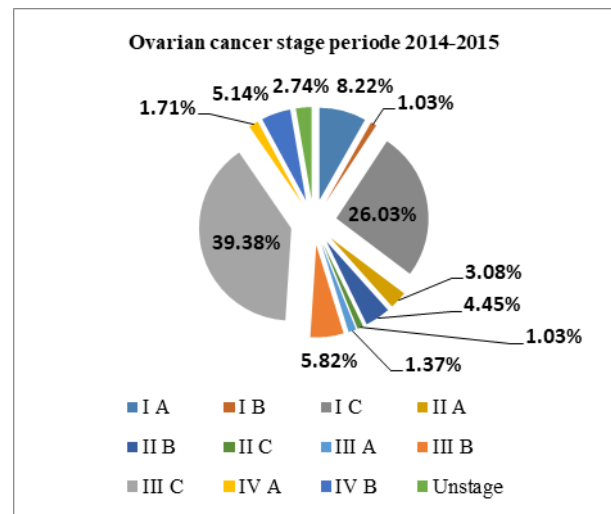


Figure 2. Percentage of ovarian cancer patients based on stage dr. Soetomo Hospital periode 2014-2015

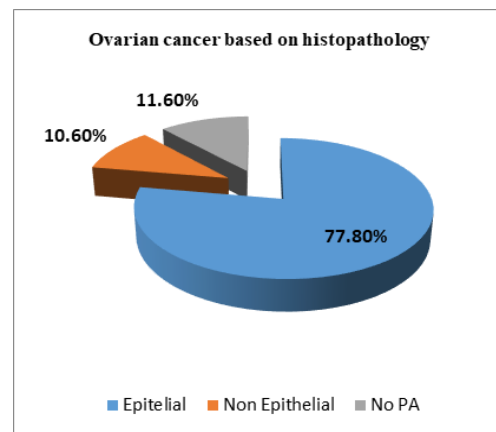


Figure 3. Ovarian cancer based on histopathology in dr. Soetomo Hospital periode 2014-2015

Epithelial ovarian cancer was the most common type of ovarian cancer histopathology with 77.8%, while non epithelial was 10.60%. There were 11.60% of ovarian cancer patients have not undergone surgery so there were no histopathologic data. Based on the histopathology type of epithelial ovarian cancer, most of them were serous papillary type with 33.50%, while the mucinous type were 23.80%, the endometrioid were 19.90%, the clear cell carcinoma were 9.20%, and non-specific were 13.60%. In non epithelial ovarian cancer, 41.94% were granulosa cell tumor that was one of

stromal sex cord tumor, whereas dysgerminoma that was one of germ cell were 16.12%, 32.58% yolk sac tumor, 9.68% were embryonal tumor, and 9.68% were immature teratoma.

Of 292 patients with ovarian cancer in Dr. Soetomo hospital between 2014-2015, there were 5 patients with pleural metastasis and 7 patients with lung metastasis.

Table 1. Number of patients with ovarian cancer stage IV in Dr. Soetomo hospital periode 2014-2015

	n	%
IV A	5	25
IV B	15	75
Lung	7	35
Others	8	40

The age range of ovarian cancer patients with pleural and lung metastasis at diagnosis were 25-68 years with median 51.5 years. Based on parity, 75% of patients are multiparous. 41.67% of patients had menarche at age > 14 years, 33.33% had menarche at <12 years, and 25% had menarche at 13-14 years. There were 83.33% of ovarian cancer patients with pleural and lung metastasis had already menopause at diagnosis.

In 5 patients with pleural metastasis, 4 patients (80%) were diagnosed during the first diagnosis of ovarian cancer, while 1 patient (20%) was diagnosed <6 months from the initial diagnosis of ovarian cancer. Whereas in lung metastasis, 2 patients (28.57%) were diagnosed with first- diagnosis of ovarian cancer, 1 patient (14.28 %) were diagnosed lung metastasis at 7-12 months from first diagnosis of ovarian cancer, and 4 (57.15%) patients were diagnosed lung metastasis > 12 months from first diagnosis of ovarian cancer.

Pleural metastasis was diagnosed with positive cytology results in pleural fluid, whereas lung metastasis was diagnosed radiologically either thoracic x-ray or thoracic CT or biopsy.

Diagnosis of lung metastasis was established only through radiological examination in 4 of 7 patients (57.14%), while biopsy was performed in 3 patients (42.86%). Radiological features of lung metastasis may be nodules (71.42%), pneumonic type (14.29%) and reticuloglanular pattern (14.29%). There were 9 of 12 patients with pleural and lung metastasis with histopathologic results, 8 of which were obtained by surgical staging and 1 histopathology result were obtained from FNAB guiding CT scan of tumor mass.

Table 2. Characteristic of ovarian cancer patients with pleural and lung metastasis.

	n	%
Parity		
Nulipara	3	25
Multipara	9	75
Age of menarche		
≤ 12 years	4	33.33
13-14 years	3	25
> 14 years	5	41.67
Menopause		
Yes	10	83.33
No	2	16.67
Age of menopause		
≤ 45 years	2	16.66
46-50 years	4	33.33
>50 years	4	33.33
Not yet menopause	2	16.66
Surgery		
Yes	8	66.67
No	4	33.33
Age		
Range	25-68	
Median	51.5	

Tabel 3. Time of pleura and lung metastasis diagnosis from ovarian cancer diagnosis

	Metastasis diagnosis	
	n	%
Pleura		
First ovarian cancer diagnosis	4	80
≤ 6 months	1	20
7-12 months	0	0
> 12 months	0	0
Lung		
First ovarian cancer diagnosis	2	28.57
≤ 6 months	0	0
7-12 months	1	14.28
> 12 months	4	57.15

Table 4. Diagnosis and radiologic imaging in lung metastasis of ovarian cancer

	N=7	%
Diagnosis		
Radiologic	4	57.14
Radiologic and biopsy	3	42.86
Radiologic imaging		
Nodal	5	71.42
Pneumonic Type	1	14.29
Reticulonodular pattern	1	14.29

Table 5. Histopathology type in ovarian cancer with pleural and lung metastasis

	Pleura		Lung	
	n	%	n	%
Epithelial	2	66.67	6	100
Serous papillary	2	66.67	1	16.66
Mucinous	0	0	2	33.33
Clear Cell	0	0	1	16.66
Endometrioid	0	0	1	16.66
Pseudomyxoma Peritonii	0	0	1	16.66
Germ cell	1	33.33	0	0
Sex cord	0	0	0	0
Grade				
1	0	0	2	33.33
2	2	100	2	33.33
3	0	0	1	33.33

In 4 patients with ovarian cancer with pleural or lung metastasis, metastasis was found in many other organs. There were 3 patients with liver metastasis, and 1 patient with metastasis in umbilicus.

Table 6. Other distant metastasis in ovarian cancer patients with pleura and lung metastasis

	Pleura (n=5)	Lung (n=7)
Lung	1	2
Biopsy (+)	0	1
Biopsy (-)	1	1
Umbilicus	0	1
Biopsy (+)	0	1
Biopsy (-)	0	0

Ovarian cancer patients were often accompanied by ascites. Ascites was obtained in 7 of 12 patients (58.33 %) with pleural and lung metastasis, 6 of them with positive cytology.

Table 7. Ascites in ovarian cancer patients with pleural and lung metastasis

	Pleura		Lung	
	n = 5	%	n = 7	%
Positive	4	80	3	42.86
Cytology(+)	4	80	2	28.57
Cytology(-)	0	0	1	14.29
Negative	1	20	4	57.14

In pleural metastasis 80% were accompanied by ascites and all of them had positive ascites cytology results. In lung metastasis, only 3 of 7 patients (42.86%) had ascites.

In ovarian cancer patients with pleural and lung metastasis almost entirely had chemotherapy, only 1 in 12 patients who did not undergo chemotherapy. There were 5 patients (41.67%) underwent NAC chemotherapy prior to surgery to improve operability, 4 with pleural metastasis and 1 patient with lung metastasis. Of the 6 patients who received adjuvant post-primary debulking chemotherapy, only 1 patient (8.33%) under-nt first line chemotherapy, paclitaxel carboplatin, and 5 patients (41.67%) underwent chemotherapy up to second-line chemotherapy, gemcitabin carboplatin. One patient did not undergo chemotherapy because he died before optimal conditions for chemotherapy.

Table 8. Chemotherapy management in ovarian cancer patients with pleural and lung metastasis

	n	%
NAC chemotherapy	5	41.67
Chemotherapy after primary debulking	6	50
First Line	1	8.33
Second Line	5	41.67
No chemotherapy	1	8.33

Surgery in were performed in 8 of 12 ovarian cancer patients with pleural and lung metastasis, 6 were primary debulking and 2 were interval debulking. From 6 patients who underwent primary debulking, 1 was done in Dr. Soetomo Hospital Surabaya and 5 others were in outer hospital. There were 2 patients underwent interval debulking in Dr. Soetomo Hospital after chemotherapy NAC paclitaxel carboplatin 3 cycles. There were 4 ovarian cancer patients with pleural and lung metastasis had been given NAC chemotherapy but no interval debulking can be made due to disease progression and unoptimal patient's condition.

In patients who underwent primary debulking, only 2 patients (33.33%) obtained residue after surgery <1 cm, while the rest (66.67%) the mass residue after surgery were more than 1 cm. In patients receiving NAC chemotherapy, a negative residue were found in 2 patients (100%). Of the 12 patients with ovarian cancer with pleural and lung metastasis there were 2 patients with secondary debulking.

In 12 patients with ovarian cancer with pleural and lung metastasis during this study, 11 patients had died, and there was 1 patients still alive with lung metastasis. In pleural metastasis the survival range of the patient since the pleural metastasis is declared to death or until the study were 2-18 months with a median of 7 months. Whereas in ovarian cancer with lung metastasis, from 7 patients range of survival since lung metastasis was

declared to death or until this study was 2 -22 months with median 12 months.

Table 9. Surgery in ovarian cancer patients with pleural and lung metastasis

	n	%
Surgical staging		
Primary Debulking	6	50
Interval Debulking	2	16.67
Secondary debulking	2	16.67
No surgery	4	33.33
Primary Debulking	6	100
Soetomo hospital	1	16.67
Other hospital	5	83.33
Mass residue < 1 cm	2	33.33
Mass residue > 1 cm	4	66.67
Interval debulking	2	100
Mass residue < 1 cm	2	100
Mass residue > 1 cm	0	0

Table 10. Survival of ovarian cancer patients with pleural and lung metastasis

	Survival (months)
Pleura	
Range	2-18
Median	7
Lung	
Range	2-22
Median	12

Ovarian cancer overview in dr. Soetomo Hospital, Year 2014- 2015

Epidemiology

Number of visits of ovarian cancer patients in dr. Soetomo was increased from year to year. In 2014, there were 170 patients visit with a diagnosis of ovarian cancer, this number had decreased in 2015 with a total of 122 patients, and again increased in 2016 with 211 patients. Based on GLOBOCCAN data in 2012, ovarian cancer was ranked seventh most common cancer in women in the world with 239,000 cases (3.6%), and the eighth leading cause of cancer deaths among women in the world with 152,000 deaths (4.3%) in 2012. Ovarian cancer was higher in developing countries with 7.5 per 100,000. The risk of death from ovarian cancer before age 75 is higher in developing countries than in developed countries. In Southeast Asia, based on GLOBOCCAN data in 2012 there were 19,900 new cases of ovarian cancer and 13,000 deaths from ovarian cancer. Ovarian cancer was the fifth leading cause of death in

women in the world. Epidemiologic data of ovarian cancer in Indonesia had not been recorded well but it was estimated that there were 347,792 cancer patients (1.4%) in 2013, and most cancer in women were breast cancer and cervical cancer ²⁻³.

Stage

Ovarian cancer patients generally come at an advanced stage. This is because there were no method of early detection of ovarian cancer, and symptoms were felt by patients when the tumor had grown to a large mass. In 2014-2015, the stage of ovarian cancer mostly were at IIIC stage (39.38%). Even in developed countries like England , ovarian cancer patients come at an advanced stage. In the study by Doufekas in 2014, 60% of ovarian cancer patients in the UK come at an advanced stage (stage III and IV) and only 30% come in the early stages (stage I and II) ¹¹.

Symptoms of ovarian cancer were non-specific and patients and doctors may inadvertently ignore the complaints. On some retrospective studies, delayed diagnosis were caused by both patients and physicians as well. The study by Wikborn et al (1995) mentions that patients with serous epithel ovarian cancer had longer complaints than other types of ovarian epithelial cancer. The average duration of complaints in serous epithelial cancer were 12 weeks compared with other epithelial ovarian cancer types with 7 weeks, although time spans duration of complaint were very large which was between 1-52 weeks. Delayed diagnosis by doctors occurs because of a delay from the first time the patient checked into a definitive diagnosis. Patients with early-stage ovarian cancer (stage I and II) had a shorter time in diagnosis. In patients with ovarian cancer with pleural and lung metastasis in this study 58.33% had complaints less than 6 months before first visit to doctors, 25% had complaints for 7-12 months and 16.67% had complaints more than 12 months before first visit to doctors ¹².

Screening

In addition to non-specific ovarian cancer complaints, the cause of ovarian cancer patients coming at an advanced stage is the absence of early detection methods in ovarian cancer. The methods that can be used in early detection of ovarian cancer are Ca 125 and transvaginal sonography (TVUS). Increased CA 125 is only found in 50% of stage I ovarian epithelial cancer and 75-90% in advanced ovarian epithelial cancer. In the Prostate, Lung, Colorectal and Ovarian Cancer Screening (PLCO) studies of 28,000 women aged 55-74 who underwent CA 125 and transvaginal sonography (TVS) examinations, only 402 (1.4%) had elevated CA

125. During the study only 29 cases of ovarian malignancy were found, 16 of which were accompanied by an increase of CA 125, while 14 cases were in advanced stage without an increase in CA 125. Based on the PLCO study also, the positive predictive value of CA 125 were low which is 4%¹³⁻¹⁴.

Ultrasound examination is able to provide a clear picture of the ovaries and detect morphological changes leading to malignancy, especially transvaginal sonography (TVS). One study of TVS as an early detection was performed by Van Nagell et al in 25,000 women with a family history of ovarian cancer. TVS sensitivity and specificity as a detection of ovarian cancer from this study is quite high at 85% and 98%, whereas positive predictive value and negative predictive value were 14.01% and 99.9%. Although the results of these studies show that TVS has good sensitivity and specificity, it should be remembered that variations of TVS screening operators greatly influence the examination results^{13,15}.

Histopathology

Epithelial ovarian cancer was the most common type of ovarian cancer histopathology with 77.8%, while non epithelial was 10.60%. In this study there were 11.60% of ovarian cancer patients have not undergone surgery so that no result of histopathologic type of ovarian cancer. Based on the histopathology type of epithelial ovarian cancer, the most common type were serous papillary type with 33.50%, while the mucinous type were 23.80%, the endometrioid were 19.90%, the clear cell carcinoma were 9.20%, and non-specific were 13.60%. The results of this study were consistent with other research, which is 75 to 80% of epithelial ovarian cancers were serous, whereas endometrioid types were 10%, clear cell were 5%, mucinous were 5%, while Brenner and undifferentiated tumors were 1% of all epithelial ovarian tumors. In western countries, 5% of ovarian cancers came from germ cells, whereas in Asia and Africa 15% of ovarian cancers came from germ cells and 30-40% of them were dysgerminomas. Ovarian sex cord tumors occurred in about 5-8% of all ovarian cancers¹.

Overview of Ovarian Cancer with Pleural and Lung Metastasis in Dr Soetomo Hospital In 2014-2015

In 2014-2015 at Dr. Soetomo Hospital, there were 292 patients with ovarian cancer, 5 patients had metastasis to the pleura and 7 patients had metastasis to the lung. Distant metastasis in ovarian cancer was quite rare. Cormio and colleagues conducted a retrospective study in 2003 about distant metastasis in ovarian cancer with the study subjects of patients with epithelial ovarian

cancer during the years 1991 - 2000 with 162 patients. There were 67 metastasis from 50 patients. The most common sites of distant metastasis were in the liver (21 patients), pleura (11 patients), lung (8 patients), central nervous system and skin with each 7 patients, spleen and extra abdominal KGB each 5 patients, bone (2 patient) and breast (1 patient)⁴.

In another study by Kerr et al (1985) with autopsy, 159 out of 357 ovarian cancer patients (44%) had intrathoracic metastasis and 46 of them had multiple intrathoracic metastasis. The intrathoracic metastasis is pleural effusion, parenchymal or solid metastasis, hilar or nodal metastasis, solid pleural metastasis, and also ribs, pericardial and intravascular lung metastasis¹⁶.

The age range of patients with pleural and lung metastasis at diagnosis was 25-68 years with a median of 51.5 years. This result is not much different from that of Kerr in 1985, where the median age of ovarian cancer patients with thoracic metastasis was 56.6 years, and this age was higher than in patients with ovarian cancer who did not have thoracic metastasis (53.7 years) although this difference was not significant. The peak incidence of thoracic metastasis in ovarian cancer was 55-64 years, where this age peak was higher than ovarian cancer who do not have thoracic metastasis which was 45-54 years¹⁶.

Nulliparous and low parity were associated with an increased incidence of ovarian cancer. In general, ovarian cancer studies show a decreased risk of ovarian cancer by increasing the number of term pregnancies experienced. Multiparous women have a 50% lower risk of ovarian cancer than nulliparous. In nulliparous patients also have a worse prognosis. In the study by Basevic et al showed that nulliparous ovarian cancer patients had a higher fatal case of 50.9% than in multiparous with only 49.7%¹⁶⁻¹⁷.

Time of diagnosis of pleural and lung metastasis

In pleural metastasis patients, 80% have been diagnosed since the diagnosis of ovarian cancer through examination of thoracic images that showing pleural effusion, followed by pleural fluid cytology examination with positive results. There was 1 patient with ovarian cancer with pleural metastasis that was diagnosed 3 months after diagnosis of ovarian cancer. In this patient, salphingo-oophorectomy surgery had been performed at RSUD Nganjuk with malignant PA results, but on examination of pre-operative thoracic x-ray image there were abnormalities. This gap was due to disease progression or early examination was unable to detect any metastasis either radiologically or the presence of malignant cells on pleural cytology examination.

Positive cytologic examination was found only in 60% of malignant pleural effusions, so pleural cytology studies should be repeated if complaints still remain ¹⁸.

Lung metastasis was diagnosed at the same time as the diagnosis of ovarian cancer in 2 patients. In these patients, the initial radiological examination showed the description of lung metastasis so the initial stage in this patient was IVB. There were two patients had undergone surgical treatment at other hospital in 2009 and 2012 with malignant histopathology, but the patient did not immediately go to dr. Soetomo. Preoperative examination did not show lung metastasis in both patients. In both patients the distance between the diagnosis of ovarian cancer and lung metastasis may be due to disease progression or limitations of thoracic examination so that the presence of metastasis can not be detected. In both patients the thoracic radiological examination only with x-ray thoracic images. Examination of thoracic photographs is a preliminary examination to detect lung metastasis, but the sensitivity and specificity of this examination is quite low. In a 2011 study in the United States comparing the use of thoracic CT scans with thoracic x-ray images in 53.454 patients with high-risk lung cancer, the positive screening was higher in the CT scan group (24.2%) than in thoracic x-ray group (6.9%) ¹⁹.

There were 2 patients with ovarian cancer with lung metastasis that was diagnosed 12 months and 20 months after diagnosis of ovarian cancer. In both of these patients had undergone early surgery in the other hospital, 1 patient with debulking and 1 patient with supravaginal hysterectomy. The first patient had first line chemotherapy paclitaxel carboplatin 3x and second line chemotherapy gemcitabine carboplatin 3x, then in radiological examination there were lung metastasis 3 months after last chemotherapy. The second patient had chemotherapy paclitaxel carboplatin 6x after the first operation and continued with surgical optimalization. The patient then underwent follow-up in the gynecological oncology outpatient clinic for 12 months and complained lung disturbances and then confirmed lung metastasis radiologically. The majority of epithelial ovarian/fallopian tube cancer patients will recurrent with a median time of 16 months ²⁰.

There were 1 ovarian cancer patients who had surgical staging (TAH-BSO-peritoneal fluid cytology) in Dr. Soetomo Hospital and declared stage IA so it does not require adjuvant chemotherapy. However, 6 years post-surgical staging there was recurrent mass in the lung. Some studies say that although clinically ovarian cancer is still in its early stages (cancer cells are limited to the ovaries), it is possible that there has been metastasis to the abdominal lymph nodes. A study by Powless in

2011 found that 10 out of 125 patients (8%) of patients with clinically stage IA-IC had metastasis to the lymph nodes. Another study by Uker et al (2013) mentioned that of 62 patients with IA-IC clinical stage, 8 of them (12.9%) had already metastasis to the abdominal lymph nodes. In a study by Rose et al showed that abdominal lymph node metastasis were associated with lung metastasis ^{5,21,22}.

Study by Kerr et al showed 15% of ovarian cancer patients were diagnosed with thoracic metastasis at the start of the diagnosis, whereas 30% were diagnosed with thoracic metastasis during follow-up. While from Cormio's study (2003), 13 patients (18%) were diagnosed with distant metastasis during early diagnosis of ovarian cancer (stage IV), while 37 patients (22%) had distant metastasis in the course of disease progression. The earliest organs metastasis are liver, brain, and skin, whereas bone and pleural metastasis take the longest time ^{4,5}.

Diagnosis of pleural and lung metastasis

Pleural metastasis in cancer was established with positive pleural fluid cytology. Patients with malignant pleural effusions have dyspnea complaints, and the volume of pleural fluid varies from 500 to 2.000 ml. Pleural effusions of 500 cc may not provide complaints to patients. Pleural effusion diagnosis was commonly done with x-ray thoracic images, thoracic CT scan, MRI (magnetic resonance imaging) for minimal effusion, thoracentesis, pleural fluid analysis and pleural biopsy. Examination with thoracic x-ray imaging was able to detect the pleural fluid at least 100 cc ^{18,19,23}.

Positive cytology results were found in 60% of malignant pleural effusions. Negative test results were associated with tumor type (generally negative in mesothelioma, sarcoma, and lymphoma), the number of tumor cells in pleural cavity, and cytological capability. 10 cc of pleural fluid is adequate for cytologic examination. A second cytologic examination should be performed if malignancy is suspected although the first pleural cytology results give a negative result ¹⁸.

Diagnosis of lung metastasis was established only through radiological examination in 4 of 7 patients (57.14%) while biopsy was performed in 3 patients (42.86%). Radiological features of lung metastasis may be nodules (71.42%), pneumonic type (14.29%) and reticuloglanular pattern (14.29%). Radiological examination of lung metastasis might be done with thoracic image or with a thoracic CT scan. In patients with lung metastasis, only 2 patients were diagnosed with thoracic x-ray images, while the other 5 were confirmed by thoracic CT scan.

A routine thoracic x-ray in patients with malignancy is an effective mechanism in detecting lung metastasis. CT scans provide a higher resolution, and sometimes show additional lesions that are not visible in ordinary thoracic x-ray images. PET scans are very useful, although inflammatory conditions can also give positive results on PET scans. Lung function tests rarely help, unless bronchial obstruction or endovascular area metastasis occurred. Sputum examination, bronchial washes, transtracheal, transbronchial, or transthoracic fine needle aspiration are helpful in the diagnosis of lung metastasis as well as in primary lung cancer. A typical feature of radiological lung metastasis is the presence of multiple nodules with firm borders, located in peripheral (hematogenic spread) or interstitial thickening (lymphangitic carcinomatosis). Clinically, there were atypical radiological features that should be distinguished from non-malignant image^{9,24}.

In 7 ovarian cancer patients with radiological features suggesting lung metastasis only 3 of them underwent FNAB (fine needle aspiration biopsy) with guiding CT scan. In another patient with no lung biopsy, 1 patient had a pneumatic type radiograph, 1 patient with reticulonodular pattern, 1 patient with a single nodule of 1.01 cm in left inferior lobe on CT thoracic scan, and 1 patient with left parahilar nodule on thoracic x-ray images but not confirmed by CT thoracic scan. All of four lung metastasis patients without lung biopsy was due to technical difficulty.

Percutaneous needle biopsy guided by CT scan is a very important diagnostic method in evaluating lung abnormalities due to high accuracy, sensitivity and specificity. Lung biopsy has an important role to prove malignancy, staging and management. Needle biopsy can be done by using a fine needle biopsy (FNAB) or core needle biopsy (CNB). Lung FNAB has a sensitivity of 82-99%, specificity 86-100%, and accuracy 64-97%²⁵.

Histopathology of ovarian cancer in pleura and lung metastasis

In ovarian cancer patients with pleural and lung metastasis, there were nine patients with histopathologic results, 8 of which were obtained by surgical staging and 1 histopathology result were obtained from FNAB guiding CT scan of tumor mass.

Based on the histopathological type of ovarian cancer, 8 of them were epithelial and 1 was non epithel (dysgerminoma). In 5 patients with pleural metastasis (stage IVA), 3 of whom had histopathological results, 2 were serous papillary adenocarcinoma (66.67%) and 1 patient (33.33%) in the form of dysgerminoma (germ cell). In 7

patients with lung metastasis, 6 of whom had histopathologic results, 1 patient (16.67%) with serous papillary adenocarcinoma, 2 patients (33.33%) with mucinous adenocarcinoma, 1 patient (16.67%) with clear cell carcinoma, 1 patient (16.66%) with endometrioid carcinoma, and 1 patient (16.67%) with pseudomyxoma peritonii.

Based on the grade of histopathology, 100% pleural metastasis were grade 2. While in lung metastasis, 2 patients (33.33%) were histopathologically grade 1, 2 patients (33.33%) were grade 2, and 2 patients (33.33%) were grade 3. In Rose et al study in 1989, all types of histopathology of ovarian cancer generally spread most widely in the peritoneum and abdominal lymph nodes, but no statistically significant association was found between histopathology of ovarian cancer and pleural and thoracic metastasis. In ovarian epithelial cancer there was an association between intraperitoneal metastasis with lung metastasis, kidney and adrenal glands. It also found an association between abdominal lymph node metastasis with lung metastasis, heart and pericardium, kidney, adrenal glands and bone. In another study by Cormio in 2003, no association was found between histopathologic types of ovarian cancer and distant metastasis. From the Cormio study also mentioned that factors associated with distant metastasis are the grade of tumor cells, the stage of cancer and the presence of metastasis of the abdominal lymph nodes^{4,5}.

Based on the histopathology type of epithelial ovarian cancer, high grade serous carcinoma (HGSC) and low grade serous carcinoma (LGSC) have transcoelomic spread, with HGSC transcoelomic spreading was faster than LGSC. Mucinous carcinoma (MC) is generally confined to the ovaries, whereas endometrioid carcinoma and clear cell carcinoma are generally limited to the pelvis. The study by Jenison et al found different results. The spreading to distant organs (liver, lung, bone, spleen, brain, etc.) were more common in clear cell type than serous adenocarcinoma^{26,27}.

In ovarian cancer patients with pleural and lung metastasis, there were 1 patient with histopathological results of pseudomyxoma peritonii (PMP). This patient underwent debulking surgery at an other hospital and no evaluation was done on his appendix. PMP is very rare and is characterized by the diffusion of intra-abdominal mucin fluid (belly jelly). PMP comes from the appendix in men, whereas in women it can come from appendix and ovary. The molecular markers of PMP derived from the appendix are MUC-2. Progressivity of PMP is slow and extra abdominal metastasis is very rare. Although rare, extra-abdominal metastasis in PMP generally occurs in the pleura and lung. Pleural metastasis in PMP occurs due to diaphragmatic injuries during surgery or

direct invasion through the diaphragm, whereas lung metastasis in PMP occur via lymph vessels or blood vessels. Based on the literature review, 11 PMP patients with pleural and lung metastasis were found, 4 of whom were women^{28,29}.

Other distant metastasis in ovarian cancer patients with pleural and lung metastasis

There were 4 ovarian cancer patients with multiple metastasis, 3 patients were lung and hepatic metastasis and 1 patient with lung and umbilicus metastasis.

Cormio et al. study (2003) showed in patients with distant metastasis, 37 patients had only single metastasis, while 10 patients had metastasis in two sites, 2 patients in three sites, and 1 patient in four sites. Factors that significantly influence the distant metastasis from this study are stage, grade, and lymph node involvement. Another study by Sood et al mentions that distant metastasis in ovarian cancer are greater in tumor cells with p53 gene mutations than tumor cells without p53 gene mutations (66% versus 8%). Distant metastasis in ovarian cancer is rare without any intra-abdominal spread. In the Cormio study (2003), 72% of distant metastasis was accompanied by another spreading elsewhere, especially intra-abdominal. In Rose et al (1989) research, distant metastasis of the lung, kidneys and adrenal glands were associated with intraperitoneal spread, and the spreading to abdominal lymph nodes was associated with lung, cardiac and pericardial, kidneys, adrenal glands, and brain metastasis. Rose also mentioned that lung metastasis were associated with other distant metastasis in the brain, bone and adrenals. Multiple metastasis did not affect the survival rate of ovarian cancer patients^{4,5,30}.

Metastatic epithelial ovarian cancer may occur via transcoelomic, haematogenic and lymphatic pathways. Of these three pathways, the most common were transcoelomic metastasis and were associated with patient morbidity and mortality. Metastasis via transcoelomic pathway occurred through several stages including tumor cell release, ascites fluid flow, immune system avoidance, spheroid formation, further formation of ascites, and tumor cell implantation. Transcoelomic pathways have access to the circulatory system. The ascites fluid that carries epithelial cancer cells enters subperitoneal lymphatic lacuna located between the diaphragm muscle cells. From the lacuna, the liquid passes through the diaphragm and then reaches the lymphatic collecting duct under the aperture of the diaphragm. The lymphatic fluid then goes to the retrosternal lymphatic vessels and enters the thoracic ductus and finally into the subclavian vein. However,

hematogenous metastasis is very rare in epithelial ovarian cancer³¹.

Ascites in ovarian cancer patients with pleural and lung metastasis

Ascites was found in 7 patients (58.33%) with pleural and lung metastasis, 6 of them with positive cytology. In pleural metastasis patients, 80% were accompanied by ascites and entirely with positive ascites cytology results. In lung metastasis, 3 of 7 patients (42.86%) had ascites, and 2 (28.57%) had positive ascites cytology results

Malignant ascites are common in ovarian cancer patients. The definition of malignant ascites is the accumulation of fluid containing cancer cells in the abdomen. Ascites result from lymphatic obstruction, mesothel cell activation due to metastasis, and increased vascular permeability mediated by vascular endothelial growth factor (VEGF), interleukins 6 and 8 (IL6 and IL8)²¹.

Research by Powless (2011) suggests that ascites were associated with abdominal lymph node metastasis. Metastatic abdominal lymph nodes were found in 11 of 39 patients (28.2%) with ascites compared to patients without ascites (9.3%)³².

Chemotherapy in ovarian cancer patients with pleural and lung metastasis

Some experts suggest that in certain patients with stage III-IV and with pleural effusion and or massive ascites should receive chemotherapy before debulking. Two to three cycles of chemotherapy prior to cytoreduction surgery in patients with ascites permagna or massive pleural effusion will decrease the amount of ascites / pleural effusion, improve patient condition and decrease postoperative morbidity. Rosen et al in 2014 mentioned that in patients who received neo adjuvant chemotherapy, the presence of residuals was seen less frequently than patients who underwent primary debulking (50% versus 41.5%). But survival up to 7 years was greater in the primary debulking group than in neo adjuvant chemotherapy group, 41.1% compared with 8.6%. In another study by Gill et al (2016) in 87 patients receiving neuro-adjuvant chemotherapy (NAC), no residuals were found after debulking interval in 66.7% of patients, and the remainder had <1 cm residual mass (optimal cytoreduction)^{33,34}.

In ovarian cancer patients with pleural and lung metastasis, 5 patients (41.67%) underwent NAC chemotherapy prior to surgery to improve operability, 4 with pleural metastasis and 1 patient with lung metastasis. Of

the 5 patients undergoing NAC chemotherapy, only 2 were subsequently subjected to interval debulking, while the other 3 patients did not have interval debulking because of lost of follow-up in 1 patient and disease progression in 2 patients. In two patients receiving NAC chemotherapy, they underwent TAH-BSO-omentectomy (total abdominal hysterectomy-bisalphingo oophorectomy) with negative residue. In 2 of these patients, one of whom received no adjuvant chemotherapy after interval debulking because the patient did not come again after surgery, while one other patient underwent 3x adjuvant paclitaxel carboplatin chemotherapy but then recurred 8 months after the last chemotherapy. In this patient then given back chemotherapy paclitaxel carboplatin 3x then gemcitabine carboplatin 1x.

Advanced ovarian cancer patients who have undergone primary debulking should receive adjuvant chemotherapy after surgery. The standard protocol for chemotherapy is platinum-based chemotherapy (carbo-platin or cisplatin) and taxane (paclitaxel or docetaxel) groups. Giving chemotherapy can be done intravenously or intraperitoneally. Giving intraperitoneal chemotherapy prolongs survival for up to 15.9 months. Intra-peritoneal chemotherapy can only be performed in patients with advanced cancer who have undergone optimal debulking with tumor residue <1cm and should be done in an experienced center. The addition of bevacizumab which is an anti VEGF (vascular endo-helial growth factor) every 3 weeks can extend progression-free survival²⁰.

In ovarian cancer patients with pleural and lung metastasis, 6 patients received adjuvant post-primary debulking chemotherapy, only 1 patient (8.33%) who underwent first-line chemotherapy with paclitaxel carboplatin, and 5 patients (41.67%) underwent chemotherapy up to the second line of chemotherapy (gemcitabine carboplatin). In one patient who received only a first line of chemotherapy in the form of paclitaxel carboplatin, chemotherapy was given only 2x and then the patient's condition worsened. Of the 5 patients who received second line chemotherapy, 3 of which were recurrent cases. There was 1 recurrent case within 3 months after last second line gemcitabine carboplatin chemotherapy. There was 1 recurrent patient after 12 months after last first line paclitaxel carboplatin chemotherapy and because of recurrent mass in the lung then given second line gemcitabine carboplatin chemotherapy. While 1 other patient was recurrent after 6 years post operation, then given first line chemotherapy paclitaxel carboplatin 6x but did not give good response so replaced with second line gemcitabine carboplatin chemotherapy.

In general, epithelial ovarian cancer patients will be recurrent with a median of 16 months. One of the defining prognoses is "platinum free interval" which was the time interval between the last platinum-based chemotherapy with recurrence. If the time interval with last chemotherapy less than 6 months, it is called platinum resistant whereas if more than 6 months, it is called platinum sensitive. In patients with progressive ovarian cancer during treatment or recurrent within 4 weeks after the last chemotherapy, it is called platinum refractory. In platinum-sensitive patients administering paclitaxel carboplatin chemotherapy improves survival and progression-free survival. In patients with neurotoxicity, giving gemcitabine or liposomal doxorubicin may replace paclitaxel. The addition of bevacizumab is also capable of improving progression - free survival. In patients with platinum-resistant, non-platinum chemotherapy treatment should be considered include liposomal doxorubicin, tapotecan, etoposide, and gemcitabine²⁰.

Surgical staging in ovarian cancer patients with pleural and lung metastasis

In ovarian cancer patients with pleural and lung metastasis, 6 patients underwent primary debulking, 5 of them in the other hospital and sent to dr. Soetomo because of malignant histopathology results. Of the 6 patients, only 2 had residues <1 cm after surgery, while the other 4 had residues > 1 cm after surgery. In 2 patients who underwent interval debulking after NAC chemotherapy with paclitaxel carboplatin 3 cycles, all of them (100%) had negative residue.

Research by Rosen et al in 2014 showed that the interval debulking after NAC chemotherapy gave less residue than primary debulking (50% versus 41.5%). Gill et al (2016) stated that no residue was found after interval debulking in 66.7% of patients receiving NAC chemotherapy, and the rest had <1 cm residue (optimal cytoreduction). Research by du-Bois et al (2009) in 3.126 ovarian cancer patients showed that progression free survival and overall survival were higher in the group with complete resection compared to the 1-10 mm residual group, and residues > 10 mm³³⁻³⁵.

Survival rate in ovarian cancer patients with pleural and lung metastasis

At the time of this study, 11 ovarian cancer patients with pleural and lung metastasis died, and 1 surviving patient was found with lung metastasis. In the pleural metastasis the survival range of the patient since the pleural metastasis was declared to death or until the study was 2-18 months with a median of 7 months. Whereas in ovarian cancer with lung metastasis, from 7

patients the range of survival since declared lung metastasis to death or until the study was 2-22 months with median 12 months. This results was not much different from research by Kerr (1985), ovarian cancer with pleural metastasis had a mean survival of 9.2 months compared to lung parenchymal metastasis (10.6 months). While the 5-year survival rate in pleural metastasis was much lower than the lung parenchymal metastasis (2.6% vs 14.8%)⁵.

The 5-year survival rate in stage IV ovarian cancer is very low at less than 20%. In the Cormio study(2003), the prognostic factors that significantly affected the median survival were performance status, staging, multiple metastasis, and intervals between the diagnosis of ovarian cancer and metastasis. The better the performance status, the lower the stage at diagnosis, the absence of multiple metastasis, and the short interval between the diagnosis of ovarian cancer and metastasis will lengthen the median survival of ovarian cancer patients with distant metastasis. Other factors affecting survival are age, histopathology type, tumor grade, tumor residue size, and presence of ascites^{4,35}.

CONCLUSIONS

Number of new ovarian cancer patients in 2014-2015 in dr. Soetomo Hospital oncology gynecology department increased each year and was the second largest number of visits after cervical cancer. Ovarian cancer patients most often came in stage IIIC and most common histopathologic types were ovarian epithelial cancer.

During 2014-2015, there were 5 ovarian cancer patients with pleural metastasis and 7 ovarian cancer patients with lung metastasis. The most common histopathological type of these patients was epithelial. Pleural metastasis was commonly diagnosed early in the diagnosis of ovarian cancer, whereas lung metastasis was diagnosed commonly >12 months after the diagnosis of ovarian cancer. Lung metastasis were established by radiological examination and / or biopsy. Metastatic ovarian cancer may occur in multiple cases. More than half of ovarian cancer patients with pleural and lung metastasis accompanied by ascites. NAC chemotherapy followed by interval debulking gives negative residual results.

The survival range of ovarian cancer patients with pleural metastasis was 2-18 months with a median of 7 months. While in ovarian cancer with lung metastasis the survival range was 2-22 months with median 12 months

REFERENCES

1. Novak E. Berek & Novak's Gynecology. Lippincott Williams & Wilkins; 2007.
2. Ferlay J, Soerjomataram I, Dikshit R, et al. Cancer incidence and mortality worldwide: sources, methods and major patterns in GLOBOCAN 2012. *International Journal of Cancer*. 2015;136(5).
3. Ministry of Health, Republic of Indonesia. Hari Kanker Sedunia. Jakarta: Pusat Data dan Informasi Kementrian Kesehatan RI; 2015.
4. Cormio G, Rossi C, Cazzolla A, et al. Distant metastases in ovarian carcinoma. *International Journal of Gynecological Cancer*. 2003;13(2): 125-9.
5. Rose PG, Piver MS, Tsukada Y, Lau T. Metastatic patterns in histologic variants of ovarian cancer. An autopsy study. *Cancer*. 1989;64(7):1508-13.
6. Fidler IJ. The pathogenesis of cancer metastasis: the 'seed and soil' hypothesis revisited. *Nature Reviews Cancer*. 2003;3(6):453-9.
7. Bacac M and Stamenkovic I. Metastatic cancer cell. *Annu. Rev. Pathmechdis. Mech. Dis.* 2008; 28(3):221-47.
8. Hsia D and Musani A. Management of Malignant Pleural Effusions. Turner White Communications, Inc; 2014.
9. Travis WD, Brambilla E, Muller-Hermelink HK, Harris C. *Tumor of The Lung*. Lyon, France: IARC; 2004.
10. Seo JB, Im JG, Goo JM, et al. Atypical pulmonary metastases: spectrum of radiologic findings. *Radiographics*. 2001;21(2):403-17.
11. Doufekas K and Olaitan A. Clinical epidemiology of epithelial ovarian cancer in the UK. *International Journal of Women's Health*. 2014;6:537.
12. Wikborn C, Pettersson F, Moberg PJ. Delay in diagnosis of epithelial ovarian cancer. *International Journal of Gynecology & Obstetrics*. 1996;52(3): 263-7.
13. Rauh-Hain JA, Krivak TC, del Carmen MG, Olawaiye AB. Ovarian cancer screening and early detection in the general population. *Reviews in obstetrics and gynecology*. 2011;4(1):15.
14. Pepin K, del Carmen M, Brown A, Dizon DS. CA 125 and epithelial ovarian cancer: Role in screening, diagnosis, and surveillance. *American Journal of Hematology/Oncology*. 2014;10(6).
15. van Nagell JR, De Priest PD, Ueland FR, et al. Ovarian cancer screening with annual transvaginal sonography. *Cancer*. 2007;109(9):1887-96.
16. Kerr VE and Cadman ED. Pulmonary metastases in ovarian cancer analysis of 357 patients. *Cancer*. 1985;56(5):1209-13.
17. Bešević J, Gunter MJ, Fortner RT, et al. Reproductive factors and epithelial ovarian cancer survival in

- the EPIC cohort study. *British Journal of Cancer*. 2015;113(11):1622.
18. Porcel JM and Light RW. Diagnostic approach to pleural effusion in adults. *Am Fam Physician*. 2006;73(7):1211-20.
 19. The American Thoracic Society. Management of malignant pleural effusions. *Am J Respir Crit Care Med*. 2000.
 20. Berek JS, Crum C, Friedlander M. Cancer of the ovary, fallopian tube, and peritoneum. *International Journal of Gynecology & Obstetrics*. 2015;131(S2).
 21. Powless CA, Aletti GD, Bakkum-Gamez JN, Cliby WA. Risk factors for lymph node metastasis in apparent early-stage epithelial ovarian cancer: implications for surgical staging. *Gynecologic Oncology*. 2011;122(3):536-40.
 22. Ulker V, Kuru O, Numanoglu C, et al. Lymph node metastasis in patients with epithelial ovarian cancer macroscopically confined to the ovary: review of a single-institution experience. *Archives of Gynecology and Obstetrics*. 2014;289(5):1087-92.
 23. Zarogoulidis K, Zarogoulidis P, Darwiche K, et al. Malignant pleural effusion and algorithm management. *Journal of Thoracic Disease*. 2013;5(Suppl 4):S413.
 24. Seo JB, Im JG, Goo JM, et al. Atypical pulmonary metastases: spectrum of radiologic findings. *Radiographics*. 2001;21(2):403-17.
 25. Winokur RS, Pua BB, Sullivan BW, Madoff DC. Percutaneous lung biopsy: technique, efficacy, and complications. In: *Seminars in Interventional Radiology*. 2013;30(02):121-7.
 26. Prat J. Ovarian carcinomas: five distinct diseases with different origins, genetic alterations, and clinicopathological features. *Virchows Archiv*. 2012 Mar 1;460(3):237-49.
 27. Jenison EL, Montag AG, Griffiths CT, et al. Clear cell adenocarcinoma of the ovary: a clinical analysis and comparison with serous carcinoma. *Gynecologic oncology*. 1989;32(1):65-71.
 28. Macrì A. New approach to peritoneal surface malignancies. *World Journal of Gastrointestinal Oncology*. 2010;2(1):9.
 29. Kitai T. Pulmonary metastasis from pseudomyxoma peritonei. *Gastroenterology Research and Practice*. 2012;12:2012.
 30. Sood AK, Sorosky JI, Dolan M, et al. Distant metastases in ovarian cancer: association with p53 mutations. *Clinical Cancer Research*. 1999;5(9):2485-90.
 31. Tan DS, Agarwal R, Kaye SB. Mechanisms of transcoelomic metastasis in ovarian cancer. *The lancet oncology*. 2006;7(11):925-34.
 32. Smolle E, Taucher V, Haybaeck J. Malignant ascites in ovarian cancer and the role of targeted therapeutics. *Anticancer Research*. 2014;34(4):1553-61.
 33. Rosen B, Laframboise S, Ferguson S, et al. The impacts of neoadjuvant chemotherapy and of debulking surgery on survival from advanced ovarian cancer. *Gynecologic Oncology*. 2014;134(3):462-7.
 34. Gill SE, McGree ME, Weaver AL, et al. Optimizing the treatment of ovarian cancer: Neoadjuvant chemotherapy and interval debulking versus primary debulking surgery for epithelial ovarian cancers likely to have suboptimal resection. *Gynecologic Oncology*. 2017;144(2):266-73.