

Case Report

Comprehensive Rehabilitation of Severe Tuberculous Meningitis: A Case Series

Yohan Christian Suisan^{1*}, Khamim Thohari²

¹Department of Medical Profession, Faculty of Medicine, Universitas Ciputra Surabaya, Surabaya, East Java, Indonesia

²Dr. Mohammad Soewandhi Hospital, Surabaya, East Java, Indonesia

*Corresponding Author:

Yohan Christian Suisan, Department of Medical Profession, Faculty of Medicine, Universitas Ciputra, Citraland CBD Boulevard, Sambikerep Surabaya, East Java, Indonesia

Email: yohan.suisan@ciputra.ac.id

Article info:

Received: August 28th, 2021;

Received in revised: December 10th, 2021;

Accepted: December 10th, 2021;

Published: February 25th, 2022

This is an open access article under the CC-BY license

(<https://creativecommons.org/licenses/by/4.0/>)



Cite this as: Nawangsari Suisan Y, Thohari K. Comprehensive Rehabilitation of Severe Tuberculous Meningitis: A Case Series. *SPMRJ*. 2022;4(1):32-36.

ABSTRACT

Tuberculous Meningitis (TBM) is a severely disabling condition that often leads to death. It requires the right intensive treatment to minimize disability, speed up recovery, and reduce the risk of death. Rehabilitation is one of the key components in managing TBM. Rehabilitation is expected to speed up recovery and prevent disabilities. The purpose of this case series was to highlight the effectiveness of a comprehensive rehabilitation program in severe TBM patients at Intensive Care Unit (ICU) settings. We present two cases of severe TBM that showed significant changes after the rehabilitation program started. Both patients were at GCS 111. Rehabilitation program was a therapist-based multimodal sensory stimulation in a comprehensive ICU setting with approximately 2 weeks duration. After 5 days of rehabilitation, the first patient's consciousness began to improve. The second patient's consciousness began to improve after 1 week of rehabilitation. After approximately 2 weeks, both of them were already at GCS 456 and then transferred to the High Care Unit (HCU). There were only minor disabilities as they were transferred. The rehabilitation program was adapted and continued at HCU. After 1 month, both of them got discharged to home. These cases highlight the importance of rehabilitation programs to be included in the management of TBM patients.

Keywords: *infectious disease, Intensive Care Unit, rehabilitation, tuberculosis, tuberculous meningitis*

Introduction

Tuberculosis is an infectious disease that often leads to death, especially in developing countries. It is estimated that every year 2 billion people are diagnosed with TB and 1.3 billion people die each year. The majority (99%) of deaths occur in developing countries.¹ Indonesia is ranked the second highest in the number of TB incidents per year. The incidence rate of TB is 391 per 100.000 population. Tuberculous meningitis (TBM) was the fifth most common form of extrapulmonary TB.²

Tuberculous meningitis is a form of severe infection of the central nervous system caused by *Mycobacterium tuberculosis* and is the most common infection of the central nervous system. Mortality and serious long-term sequelae occur in approximately 50% of patients with TBM, despite receiving anti-tuberculosis drugs.³

Rehabilitation programs are an effective way to prevent and reduce disabilities caused by severe disease, especially if they are started in the early course of the disease. If the rehabilitation program starts only after the illness is cured, it will be very difficult to deal with the disability that has already occurred.⁴

In Indonesia, rehabilitation programs are not yet included as standard care in managing TBM in Intensive Care Unit (ICU) settings. Some TBM patients just started to get their rehabilitation program just before they were discharged home. Some even do not get a rehabilitation program at all. That's why the purpose of this case series was to highlight the effectiveness of a comprehensive rehabilitation program in severe TBM patients at ICU settings.

Material and Methods

During May 2021, two patients with severe TBM were admitted. First patient was admitted in the first week of May, the second patient was admitted in the last week of May. Both were male, Javanese, 27 and 35 years old. Both of them had no history of previous tuberculosis infection. But their families reported that the patients were having specific symptoms of tuberculosis infection

(chronic cough, fever at night, progressive weight loss) 2 months prior to hospitalization. Both were admitted to the Emergency Room with decreased consciousness, high fever, meningeal sign positive, and rhonchi in bilateral lungs. Blood pressure was 130/80 and 120/90, oxygen saturation was 91% and 93% for the first and second patient respectively. Radiograph shows marked increase of bronchovascular pattern. GeneXpert TB results came out positive for both patients. Complete blood tests showed leukocytosis for both. After initial treatment and stabilization, patients then transferred to the ICU.

After 12 days of medication in ICU, the fever and leukocytosis of the first patient were normalized but he still needed oxygen supplementation at 15 lpm to maintain oxygen saturation above 95%. Ronchi were persistent in bilateral lungs. No improvement in consciousness. The pulmonologist then consulted the first patient to the Rehabilitation Department. The second patient follows a similar history (improved in laboratory results but no improvement in lung condition and consciousness), and was consulted to Rehabilitation Department after 10 days in the ICU.

Level of consciousness was assessed with Glasgow Coma Scale. The Glasgow Coma Scale (GCS) is used to objectively describe the extent of impaired consciousness in all types of acute medical and trauma patients. The scale assesses patients according to three aspects of responsiveness: eye-opening, motor, and verbal responses. The Glasgow Coma Scale divides into three parameters: best eye response (E), best verbal response (V) and best motor response (M). The levels of response in the components of the Glasgow Coma Scale are 'scored' from 1, for no response, up to normal values of 4 (Eye-opening response) 5 (Verbal response) and 6 (Motor response). Reporting each of these separately provides a clear, communicable picture of a patient. The findings in each

component of the scale can aggregate into a total Glasgow Coma Score which gives a less detailed description but can provide a useful summary of the overall severity. The Glasgow Coma Scale and its total score have since been incorporated in numerous clinical guidelines and scoring systems for victims of trauma or critical illness. There is a clear relationship between assessments of the GCS (typically reported as the total GCS Score) and mortality rate.⁵ Both of our patient's GCS was 111 (total score was 3) by the time they were consulted to Rehabilitation Department.

We use multimodal sensory stimulation (MSS) utilizing tactile, auditory, light, and proprioceptive stimulation to promote patient's arousal. Patients were also positioned according to the night and day rhythm (partial sit during day time, slight head up during night) to increase patients awareness of their environment. We also carried out a comprehensive program such as passive range of motion exercise, scheduled turning, and use of air mattresses to prevent complications of prolonged immobilization. Chest physical therapy (including postural drainage, chest wall percussion and vibration, passive chest expansion exercise, manual chest wall compression) was also performed to improve airway clearance, optimize lung expansion, and restore ventilation. Medication from pulmonologist, internist, and neurologist was continued. The medication did not change before and after the initiation of the rehabilitation program.

Results

Three days after the rehabilitation program started, the first patient showed improvement in his lungs. No ronchi detected, X-ray also showed reduction of bronchovascular pattern. Oxygen supplementation required also decreased gradually (figure 1). The second patient showed similar improvement beginning from the fifth day.

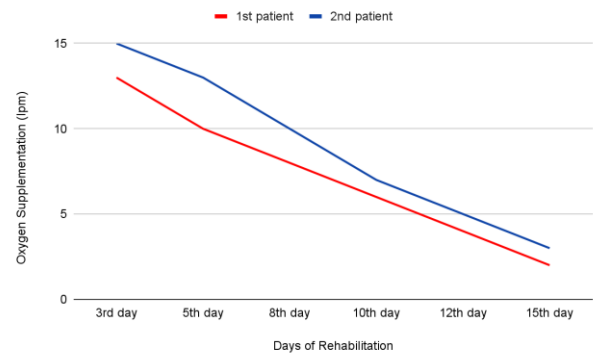


Figure 1. Patient's Oxygen Supplementation

After 5 days of rehabilitation, the first patient's consciousness began to improve. The second patient's consciousness began to improve after 1 week of rehabilitation. This improvement developed gradually as seen in figure 2. After the 15th day of rehabilitation, both of the patients had regained their full consciousness. After the 17th day, both of the patients were transferred to the High Care Unit (HCU) where they stayed 2 more weeks before they got discharged. At the HCU, we continue our rehabilitation program with some increase in intensity and duration. The passive exercises also changed to active exercises.

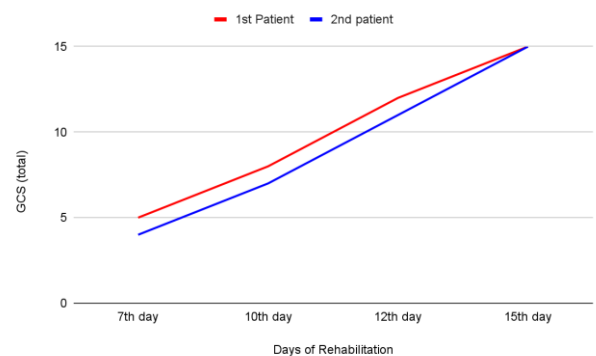


Figure 2. Patient's GCS

The first patient developed a grade 1 decubitus ulcer on his upper back. The second patient developed some stiffness on his fingers. Both of these conditions already existed at the 1st day of rehabilitation because both of the patients have been immobilized for more than 1 week. We include passive range of motion exercise, scheduled turning, and use of air mattresses to prevent worsening of these

conditions. At discharge, the ulcer healed nicely. There was no stiffness on the 2nd patient's fingers.

Discussion

Increased mucus secretion and impaired ciliary movement are pathological changes that occur in acute lung infections. These changes highly correlate with increased morbidity and mortality. Therefore improving airway clearance is always an important goal in treating patients with this condition.⁶ Pulmonary rehabilitation has also been proven to improve symptomatology, degree of functional independence, quality of life, and independence of TB patients in performing ADL.⁷ Improvement in lung condition is the first development that can be observed in these two cases. With improved ventilation, oxygen supply to the brain is increased. This provides an optimum condition for brain recovery.⁸

In these two cases, the patients remained in a coma (GCS 111) for 10-12 days even after receiving medications in the ICU. After the rehabilitation program started, the patients started to regain consciousness. Their consciousness gradually increased until they finally regained their full level of consciousness after 2 weeks of rehabilitation. This showed the importance of MSS to be included in the rehabilitation program of comatose patients. The literature shows that MSS can improve consciousness based on the development of the theory of consciousness itself. Consciousness is the ability of the human brain to integrate various kinds of information. This depends on the brain's ability to synchronize complex activity patterns from various areas of the cortex. Patients with decrease of consciousness still have remains of high-order cognitive functioning that can be excited by giving complex, simultaneous, meaningful, and adequate intensity stimuli.⁹ Similar research for MSS in head injury comatose patients also showed significant improvement in GCS compared to conventional physiotherapy.¹⁰

There were no adverse events during the rehabilitation program. The vital sign was stable throughout the therapy session. Both patients could adapt very well as we increase our therapy intensity.

From these cases, we learned that the rehabilitation program can be helpful for patients with TBM even in an ICU setting.

Unfortunately, there has not been much research on the role of rehabilitation in dealing with TBM. Current TBM guidelines still list rehabilitation as a "non-evidence based treatment suggestions for patients falling to respond to standard therapy".¹¹ Therefore we hope these case series can be used as the basis for more extensive research to fill the evidence gap of rehabilitation in managing TBM.

Conclusion

These case series underline the importance of rehabilitation in managing TBM. Hopefully with increasing research, one day rehabilitation programs can be included in main TBM guidelines.

Acknowledgement

The authors declare there are no competing interests in this paper.

References

1. Mohajan HK. Munich Personal RePEc Archive Tuberculosis is a Fatal Disease among Some Developing Countries of the World. *Am J Infect Dis Microbiol.* 2015;3(1):1–19.
2. Kemenkes RI. Indonesia National TB Program. Curr status Integr community based TB Serv Deliv Glob Fund Work plan to find missing TB cases. 2018;1–25.
3. Mahalini DS. Update diagnosis meningitis tuberkulosis pada anak. *Univ Udayana Fak Kedokt.* 2017;(July 2017):1–15.
4. Braddom RL, Cifu DX, Kaelin DL. *Braddom's Physical Medicine & Rehabilitation.* Elsevier; 2016.
5. Jain S, Iverson LM. Glasgow Coma Scale. *StatPearls [Internet]. Treasure Island (FL): StatPearls Publishing; 2021.*
6. Gai L, Tong Y, Yan B. The effects of pulmonary physical therapy on the patients with respiratory failure. *Iran J Public Health.* 2018;47(7):1001–6.
7. Mahler B, Croitoru A. Pulmonary rehabilitation and tuberculosis: A new approach for an old disease. *Pneumologia.* 2019;68(3):107–13.
8. Lacerte M, Shapshak HA, Mesfin FB. Hypoxic Brain Injury. In: *StatPearls [Internet]. Treasure Island (FL): StatPearls Publishing; 2021.*
9. Abbate C, Trimarchi PD, Basile I, Mazzucchi A, Devalle G. Sensory stimulation for patients with disorders of consciousness: From stimulation to rehabilitation. *Front Hum Neurosci.* 2014;8(AUG):1–5.
10. Megha M, Harpreet S, Nayeem Z. Effect of frequency of multimodal coma stimulation on the consciousness levels of

traumatic brain injury comatose patients. *Brain Inj.* 2013;27(5):570–7.
11. Davis A, Meintjes G, Wilkinson RJ.

Treatment of Tuberculous Meningitis and Its Complications in Adults. *Curr Treat Options Neurol.* 2018;20(3).