



RESEARCH

Posterior Capsule Opacification (PCO) Cases at Lamongan Eye Clinic: Two Years of Retrospective Data

Authors:Irma Suryani^{ORCID}Uyik Unari^{ORCID}**Affiliations:**Klinik Mata Utama Lamongan,
Lamongan, Indonesia.**Corresponding author:**Uyik Unari
unariuyik53@gmail.com**Dates:**

Received: 02 September 2021

Revised: 19 June 2022

Accepted: 22 June 2022

Published: 28 July 2022

DOI:<https://doi.org/10.20473/vsehj.v1i3.2022.67-71>**Copyright:**

© 2022 Author(s). Open access under Creative Commons Attribution-Share Alike 4.0 International Licence (CC-BY-SA).

**Abstract**

Introduction: Posterior capsular opacity (PCO) is the most common complication of cataract surgery. PCO is caused by the lens epithelial cells (LEC), which then proliferate in the capsular bag after surgery. Several complications can occur, such as increased intraocular pressure (IOP), cystoid macular edema (CME), retinal hemorrhage, retinal detachment, and implanted lens (IOL) damage. Capsule Nd:YAG laser is currently the standard procedure for treating PCO, with a success rate of 95%. **Purpose:** This study aimed to provide an overview of PCO incidence and the success rate of PCO handling in the eye clinic. **Methods:** This study was a retrospective observational study. Data was taken from medical records of patients diagnosed with PCO who came to the Lamongan Eye Clinic for two years (May 2018 to April 2020). Data regarding the profile of the subject was analyzed descriptively. The data distribution was tested using the Kolmogorov-Smirnov test. **Results:** From May 2018 to April 2020, 134 patients with PCO came to the Lamongan Eye Clinic. Mean pre-laser best-corrected visual acuity (BCVA) was 0.76 ± 0.44 (logMAR), post-laser was 0.40 ± 0.40 (logMAR). There was a significant difference in the mean refraction correction of the PCO patients before and after Nd:YAG laser capsulotomy, whereas the mean BCVA after undergoing YAG laser was higher than before. Mean pre-laser IOP was 15.00 ± 3.55 mmHg and post-laser was 14.20 ± 3.27 mmHg. The mean post-laser IOP was lower than the pre-laser IOP. The Nd:YAG laser capsulotomy significantly affected IOP. **Conclusions:** There is a statistically significant improvement in BCVA before and after capsulotomy. Capsulotomy had a significant effect on improving BCVA up to 7%; however, had no effect on IOP.

Keywords: posterior capsule opacification (PCO); neodymium-doped yttrium aluminum garnet (Nd:YAG) laser; profile

Introduction

Posterior capsular opacity (PCO) is the most common complication of cataract surgery, occurring in patients after phacoemulsification cataract surgery with intraocular lens (IOL) implantation. PCO is a secondary cataract or after cataract caused by the proliferation of lens epithelial cells (LEC) within the capsular bag after surgery, which then migrates to transform myofibroblasts and cause capsular opacification. Sinskey and Cain first reported a PCO incidence of 43% at 26 months of evaluation.^[1] Schaumberg et al.^[2] reported PCO incidence of 11.8% at one year, 20.7% after two years, and 28.5% after three years postoperatively.

PCO development is a dynamic process involving three basic phenomena: proliferation, migration, and differentiation of residual LEC.^[3] Furthermore, PCO is classified into three types based on morphology and cell origin: fibrotic type and Elschnig pearls type, and the third type is Soemmering's ring type.^[3] PCO can be managed by capsulotomy, and it is a non-invasive eye surgery done by making an incision in the clear glass-like capsule that wraps around the lens. A capsulotomy is performed using a Nd:YAG laser to open the posterior capsule. The success rate of the Nd:YAG laser capsulotomy procedure is up to 95%.^[4] Nevertheless, complications such as increased intraocular pressure (IOP), cystoid macular edema (CME), retinal hemorrhage, retinal detachment, and implanted lens damage can occur.^[5]

This study aims to determine the profile of PCO patients who came to the Lamongan Eye Clinic from May 2018 to April 2020.

Methods

This study was a retrospective observational study. Data were taken from medical records of patients diagnosed with PCO who came to Lamongan Eye Clinic for two years (May 2018 to April 2020). Research data include gender, age, length of time of established PCO diagnosis, eye surgery location, best corrected visual acuity (BCVA) before and after capsulotomy with Nd:YAG laser, and IOP before and after capsulotomy with Nd:YAG laser. This study measured BCVA in logMAR using an auto refractometer and Snellen chart.

The subjects were patients who met the inclusion criteria. The inclusion criterias in this study were PCO patients seeking treatment at the Lamongan Eye Clinic from May 2018 to April 2020. Exclusion criterias in this study were patients with incomplete medical records and patients with thin PCO. Patients with thin PCO did not undergo Nd:YAG laser capsulotomy because the visual acuity was still quite good.

All data obtained were analyzed with the 16.0 SPSS version. Data on subject profiles were analyzed descriptively. Categorical scale data were described in terms of frequency and percentage. The distribution of the data were tested using the Kolmogorov-Smirnov test. Data transformation were carried out if the data were not normally distributed, then analyzed through a test using the Wilcoxon signed-rank test and correlation and regression tests to determine the correlation of the data.

Results

From May 2018 to April 2020, 134 posterior capsule opacification patients came to the Lamongan Eye Clinic. Table 1 showed that 46.3% of the patients were between 55-65 years old (prasenium phase), and 56.0% were male (Table 2). Table 3 showed the location of the eye surgery; 52.2% had been performed at Lamongan Eye Clinic. Table 4 showed patient's previous eye surgery history; 42.5% had eye surgery in the past year.

Table 5 showed the significant result from the comparison of the average refractive correction (BCVA) in PCO patients before and after the Nd:YAG laser capsulotomy. The average post-surgery refractive correction (BCVA) was higher than the average pre-surgery refractive correction (BCVA), 0.76 logMAR and 0.40 logMAR, respectively.

Table 6 showed the significant result from the comparison of the average IOP in PCO patients before and after the Nd:YAG laser capsulotomy procedure. The mean post-surgery IOP was higher than the average IOP

Table 1. The age range of respondents.

Age	Frequency	Percentage (%)
25-40 years (Inventus phase)	1	0.7
40-54 years (Virility phase)	13	9.7
55-65 years (Prasenium phase)	62	46.3
> 65 years (Senium phase)	58	43.3
Total	134	100

Table 2. The gender of respondents.

Gender	Frequency	Percentage (%)
Male	75	56.0
Female	59	44.0
Total	134	100

Table 3. Frequency distribution of respondent's surgery location.

Location of surgery	Frequency	Percentage (%)
Gresik Eye Clinic	25	18.7
Lamongan Eye Clinic	70	52.2
Non Eye Clinic	37	27.6
dr. Soegiri General Hospital Lamongan	2	1.5
Total	134	100

Table 4. Frequency distribution of time of surgery.

Location of surgery	Frequency	Percentage (%)
< 1 year	22	16.4
1 year	57	42.5
2 years	41	30.6
3 years	14	10.4
Total	134	100

at the time of surgery, which was 15.00 mmHg and 14.20 mmHg, respectively.

Table 7 showed the relationship between the increase of BCVA in PCO patients before and after Nd:YAG laser capsulotomy, in which BCVA with Nd:YAG laser capsulotomy ($r = -0.400$) had a significant correlation ($p = 0.000$) with a weak negative correlation direction. The correction of refraction (BCVA) post Nd:YAG laser capsulotomy procedure tend to increase compared to pre-Nd:YAG laser capsulotomy procedure.

Table 8 showed PCO patients' IOP before and after the Nd:YAG laser capsulotomy procedure. The IOP with the Nd:YAG laser capsulotomy procedure ($r = -0.106$, $p = 0.035$) had a significant correlation with a strong positive correlation direction (because the correlation coefficient was positive). The IOP after the Nd:YAG laser capsulotomy procedure tends to increase compared to IOP before the Nd:YAG laser capsulotomy procedure.

Figure 1 showed a significant effect of administering Nd:YAG laser capsulotomy in improving refractive correction (BCVA). The regression line between Nd:YAG laser capsulotomy and refractive correction (BCVA)

Table 5. Comparison of mean refraction correction (logMAR) in PCO patients before and after Nd:YAG laser capsulotomy.

	Pre			Post			p-Value
	Mean	SD	Median	Mean	SD	Median	
BCVA ^w	0.76	0.44	0.70	0.40	0.40	0.40	0.000

Table 6. Comparison of mean IOP (mmHg) in PCO patients before and after Nd:YAG laser capsulotomy.

	Pre			Post			p-Value
	Mean	SD	Median	Mean	SD	Median	
IOP	15.00	3.55	14.80	14.20	3.27	13.90	0.003 ^w

points to the upper right. It proved the linearity of the Nd:YAG laser capsulotomy with refractive correction (BCVA). The Nd:YAG laser capsulotomy procedure tend to increase the refractive correction (BCVA).

Figure 2 showed the effect of the Nd: YAG laser capsulotomy procedure on increased intraocular pressure (IOP). The regression line between the Nd: YAG laser capsulotomy procedure and the intraocular pressure (IOP) tend to be horizontal although slightly pointed to the upper right. It proved no linearity in administering Nd: YAG laser capsulotomy with intraocular pressure (IOP). Nd: YAG laser capsulotomy procedure did not affect intraocular pressure (IOP) level.

Discussion

PCO is an opacity that occurs in the posterior capsule of the lens following the months or years after cataract surgery. Risk factors affecting PCO occurrence include systemic and local factors of the eye. The worldwide incidence of PCO varies from 8% to 34.3% in adult patients and is the most common complication after cataract extraction. The most effective management of PCO is a capsulotomy using an Nd:YAG laser, with a success rate of up to 95%.^[6]

In this study, PCO was more prevalent in men (56.0%) than women (44.0%). Research by Raj et al.^[3] and Wren et al.^[7] suggested no correlation between PCO and gender. Ayuningtyas et al.^[8] also stated the same thing, while the study by Hashemi et al.^[9] found that the incidence was higher in women.

In this study, most patients were in the age range between 55-65 years (46.3%), with a mean age of 63.55

Table 7. Result of correlation test between BCVA and Nd:YAG laser capsulotomy.

	Correlation coefficient	p-Value
BCVA with Nd:YAG laser capsulotomy	-0.400	0.000

Table 8. Result of correlation test between IOP and Nd:YAG laser capsulotomy.

	Correlation coefficient	p-Value
IOP with Nd:YAG laser capsulotomy	-0.106	0.035

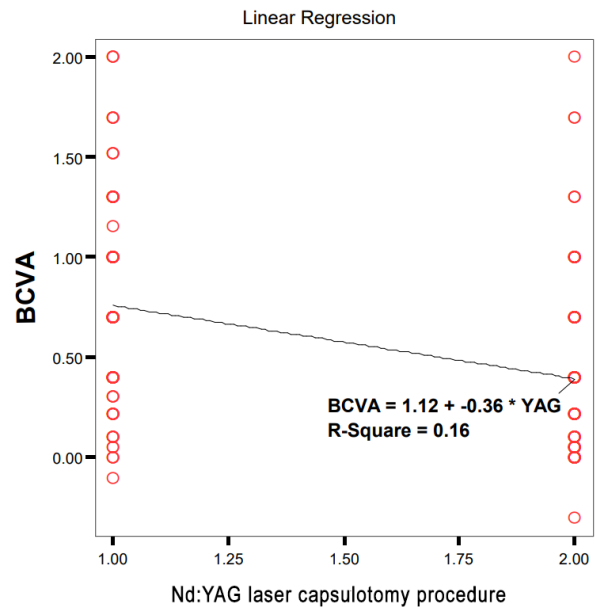


Figure 1. Linearity between Nd:YAG laser capsulotomy and refraction correction (BCVA).

± 8.72 years. Previous research^{[4],[10]} found that most patients were in the age range of 41 years to 80 years, and Ayuningtyas et al.^[8] showed a median age of 65 years with a range of 42 years to 87 years.

In various studies^{[11],[12],[13],[14],[15],[16]}, the period between patients who underwent cataract surgery and PCO formation has been reported to occur from five months to three years. In this study, PCO diagnosis was established after a median of 12 months, ranging from 8.2 months to 26.3 months after cataract extraction. Ayuningtyas et al.^[8] found that the duration of the PCO diagnosis was established since surgery with a median of 21 months with a range from one month to 34 months, while Kwon et al.^[17] found the duration of the PCO diagnosis was established in 16 months after surgery with a range of 6 to 18 months. It can be concluded that the results obtained in this study were following previous research.

The most common symptom in patients with PCO is blurred vision due to blockage of the visual axis caused by the migration and proliferation of lens epithelial cells from the equator to the visual axis, which causes reduced visual acuity several months years after cataract surgery.^[8] It was also found in this study that the best visual acuity after refraction correction on arrival or at the time of PCO diagnosis was obtained with a median of 0.5 logMAR

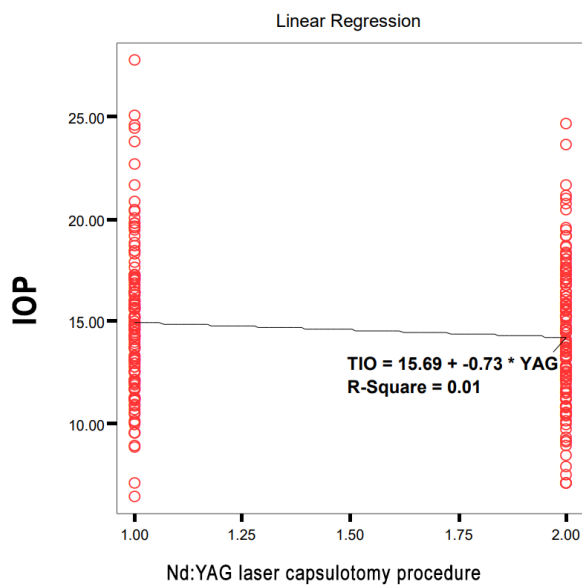


Figure 2. Linearity between Nd:YAG laser capsulotomy and IOP.

with a range of 0.00 logMAR to 2.80 logMAR. Similar findings were also found by Ayuningtyas et al.^[8], with the BCVA logMAR at the time of diagnosis being 0.50 ± 0.26 .

BCVA pre and post-laser showed a significant increase. The BCVA average before capsulotomy with Nd:YAG laser was 0.2673 ± 0.242 ; after capsulotomy with Nd:YAG laser, 147 patients had a BCVA average of 13.3078 ± 5.51 . The test results showed a significant difference ($p < 0.05$). It followed a previous study by Ayuningtyas et al.^[8] with an increased visual acuity after laser treatment with a visual acuity range of 0.7 to 1.00. Kumar et al.^[18] also obtained similar results with increased visual acuity in 91.42% of cases. Until now, the most effective action for PCO management was capsulotomy with Nd:YAG laser. The success rate was 95%, whereas visual clearance of the axis was performed by creating an opening in the central part of the opaque posterior lens capsule.

This study obtained a significant correlation ($r = 0.264$, $p = 0.000$) between increased BCVA and Nd:YAG laser capsulotomies in patients diagnosed with PCO. The regression test results also showed a significant effect between capsulotomy Nd:YAG laser with increased BCVA ($p = 0.000$ and $R^2 = 0.070 = 7\%$). In the following research by Bhargava et al.^[19], one of the things that played a role in the success of therapy with Nd:YAG lasers was the energy level used, in which each type of PCO required a different energy level. Posterior capsule opacification, which tends to be thicker, requires higher energy to clean the visual axis and improve visual acuity.^[3]

Capsulotomy with Nd:YAG laser was a fast, effective, and relatively safe procedure, however, it cannot be denied that it can still cause various complications, one of which was increased IOP.^[5] This study found a statistically significant increase in IOP, where the IOP average before capsulotomy with Nd:YAG laser was 2.23

± 5.09 . However, after capsulotomy with Nd:YAG laser, 147 patients had an IOP average of 14.20 ± 3.27 , with the test results showing a significant difference ($p < 0.05$). Similarly, Ramon et al.^[20] reported that increased IOP was a frequent complication after Nd:YAG capsulotomy, usually transient. IOP increase of more than 10 mmHg has been observed in 15-67% of eyes. The increase in IOP occurred immediately after the Nd:YAG laser, reaching a peak between 3-4 hours after the Nd:YAG laser procedure and usually returning to normal within one week. The increase in IOP after the Nd:YAG laser was associated with a decrease in the outflow of aqueous humor due to debris, acute inflammatory cells, prolapsed vitreous, and laser heat energy blocking the trabecular meshwork. Topical anti-glaucoma was given to prevent an increase in IOP, such as Apraclonidine 1% effective in 99% of cases with an increase in IOP after Nd:YAG. It was given one hour before the Nd:YAG laser was performed.

This study obtained a significant correlation ($r = 0.099$, $p = 0.046$) between increased IOP and Nd:YAG laser capsulotomy procedures in patients diagnosed with PCO. Meanwhile, the regression test results found no significant effect between Nd:YAG laser capsulotomy and increased IOP ($p = 0.091$ and $R^2 = 0.010 = 1\%$). Kumar et al.^[16] study an increase in IOP only occurred in 10% of cases.

Conclusions

It can be concluded that there is a statistically significant improvement in best-corrected visual acuity before and after capsulotomy, where the Nd:YAG laser capsulotomy had a significant effect ($p < 0.05$) on improving BCVA up to 7%. The results of the analysis also show that Nd:YAG laser capsulotomy has a significant effect on increasing intraocular pressure. However, Nd:YAG laser capsulotomy has no significant effect on intraocular pressure because it only has a negligible effect (1%).

The research advantage is that the researcher uses a diverse and relevant theoretical basis according to the case taken so that the results of this study can be used as a reference for further research on a larger scale.

Limitations of this study are that the sample is small and the follow-up time is short. As the suggestion for the following study, the study needs a larger sample of patients who underwent surgery outside the Lamongan Eye Clinic, which can also be used to compare PCO cases from other places. The subsequent study also needed a more extended period of follow-up time since this study did not record all PCO cases, especially thin PCO (grade 1), This study only records PCO patients who underwent laser (grade 2 or higher), so it does not describe the overall profile of PCO cases.

Recording patient data should be done with a better recording system for patients who come to Lamongan,

Eye Clinic especially in the cataract and refractive surgery division, so that collected data is complete and can be used for further research.

References

- [1] Steinert RF. Nd:YAG Laser Posterior Capsulotomy. *Am Acad Ophthalmol* 2013. <https://www.aao.org/current-insight/ndyag-laser-posterior-capsulotomy-3> (accessed July 1, 2022).
- [2] Schaumberg DA, Dana MR, Christen WG, Glynn RJ. A systematic overview of the incidence of posterior capsule opacification. *Ophthalmology* 1998;105:1213–1221. [https://doi.org/10.1016/S0161-6420\(98\)97023-3](https://doi.org/10.1016/S0161-6420(98)97023-3).
- [3] Raj SM, Vasavada AR, Johar SRK, Vasavada VA, Vasavada VA. Post-operative capsular opacification: A review. *Int J Biomed Sci* 2007;3:237–250.
- [4] Khambhiphant B, Liumsirijarern C, Saehout P. The effect of Nd:YAG laser treatment of posterior capsule opacification on anterior chamber depth and refraction in pseudophakic eyes. *Clin Ophthalmol* 2015;9:557–561. <https://doi.org/10.2147/OPHTH.S80220>.
- [5] Karahan E, Er D, Kaynak S. An overview of Nd:YAG laser capsulotomy. *Med Hypothesis, Discov Innov Ophthalmol J* 2014;3:45–50.
- [6] Manandhar LD, Gurung N, Shrestha K, Bhattarai B, Godar M, Shrestha R. Study of intraocular pressure following Neodymium Yttrium Aluminium Garnet laser capsulotomy with the use of Brimonidine: A descriptive cross-sectional study. *JNMA J Nepal Med Assoc* 2021;59:15–18. <https://doi.org/10.31729/jnma.5130>.
- [7] Wren SME, Spalton DJ, Jose R, Boyce J, Heatley CJ. Factors that influence the development of posterior capsule opacification with a polyacrylic intraocular lens. *Am J Ophthalmol* 2005;139:691–695. <https://doi.org/10.1016/j.ajo.2004.12.013>.
- [8] Ayuningtyas SP, Gondhowiardjo TD. Incidence and associated factors of posterior capsule opacification in pseudophakic patients at Cipto Mangunkusumo Hospital. *Med J Indones* 2015;24:176–182. <https://doi.org/10.13181/mji.v24i3.1199>.
- [9] Hashemi H, Mohammadi S-F, Majdi M, Fotouhi A, Khabazkhoob M. Posterior capsule opacification after cataract surgery and its determinants. *Iran J Ophthalmol* 2012;24:3–8.
- [10] Yie LP, Budiman B, Prajitno IP. Visual acuity of patients after Neodymium:Yttrium-Aluminium-Garnet laser at Cicendo Eye Hospital in 2013–2014. *Althe Med J* 2016;3:99–102.
- [11] Konopinska J, Młynarczyk M, Dmuchowska DA, Obuchowska I. Posterior capsule opacification: A review of experimental studies. *J Clin Med* 2021;10. <https://doi.org/10.3390/jcm10132847>.
- [12] Cooksley G, Lacey J, Dymond MK, Sandeman S. Factors affecting posterior capsule opacification in the development of intraocular lens materials. *Pharmaceutics* 2021;13. <https://doi.org/10.3390/pharmaceutics13060860>.
- [13] Gu X, Chen X, Jin G, Wang L, Zhang E, Wang W, et al. Early-onset posterior capsule opacification: Incidence, severity, and risk factors. *Ophthalmol Ther* 2022;11:113–123. <https://doi.org/10.1007/s40123-021-00408-4>.
- [14] Ursell PG, Dhariwal M, O'Boyle D, Khan J, Venerus A. 5 year incidence of YAG capsulotomy and PCO after cataract surgery with single-piece monofocal intraocular lenses: A real-world evidence study of 20,763 eyes. *Eye* 2020;34:960–968. <https://doi.org/10.1038/s41433-019-0630-9>.
- [15] Fong CS-U, Mitchell P, Rochtchina E, Cugati S, Hong T, Wang JJ. Three-year incidence and factors associated with posterior capsule opacification after cataract surgery: The Australian prospective cataract surgery and age-related macular degeneration study. *Am J Ophthalmol* 2014;157:171–179. e1. <https://doi.org/10.1016/j.ajo.2013.08.016>.
- [16] Jiang J, Shihan MH, Wang Y, Duncan MK. Lens epithelial cells initiate an inflammatory response following cataract surgery. *Invest Ophthalmol Vis Sci* 2018;59:4986–4997. <https://doi.org/10.1167/iovs.18-25067>.
- [17] Kwon YR, Hwang YN, Kim SM. Posterior capsule opacification after cataract surgery via implantation with hydrophobic acrylic lens compared with silicone intraocular lens: A systematic review and meta-analysis. *J Ophthalmol* 2022;2022:3570399. <https://doi.org/10.1155/2022/3570399>.
- [18] Kumar J, Kumar P, Tiwari T. Post operative visual outcomes after cataract surgery in Tertiary Care Eye Hospital: Observational study. *IOSR J Dent Med Sci* 2020;19:33–39.
- [19] Bhargava R, Kumar P, Phogat H, Chaudhary KP. Neodymium-yttrium aluminium garnet laser capsulotomy energy levels for posterior capsule opacification. *J Ophthalmic Vis Res* 2015;10:37–42.
- [20] Ramón-Concepción A, Chávez-Gutiérrez K, Chávez-Gutiérrez R, Sital-Gastelum S, Romo-García E, Ramos-Espinoza K, et al. Secondary ocular hypertension as a complication of posterior capsulotomy with Nd YAG laser in glaucoma suspect. *Rev Mex Oftalmol (English Ed)* 2019;93:83–88. <https://doi.org/10.24875/RMOE.M19000054>.