

## SYSTEMATIC REVIEW

# Comparison of Autologous Blood Coagulum (ABC) and Suture at Recurrence Rate and Graft Stability of Postoperative Primary Pterygium Using Conjunctival Autograft: A Meta-Analysis From Randomized Controlled Trial

**Authors:**Amelia Rahmah Kartika<sup>1</sup>Made Angga Putra<sup>2</sup>Delfitri Lutfi<sup>3</sup>**Affiliations:**Department of Ophthalmology,  
Faculty of Medicine, Universitas  
Airlangga–RSUD Dr. Soetomo  
Surabaya, Indonesia.**Corresponding author:**

Delfitri Lutfi

delfitri-l@fk.unair.ac.id

**Dates:**

Received: 01 October 2021

Revised: 30 May 2022

Accepted: 06 June 2022

Published: 20 July 2022

**DOI:**[https://doi.org/10.20473/  
vsehj.v1i3.2022.58-66](https://doi.org/10.20473/vsehj.v1i3.2022.58-66)**Copyright:**© 2022 Author(s). Open  
access under Creative  
Commons Attribution-Share  
Alike 4.0 International  
Licence (CC-BY-SA).**Abstract**

**Introduction:** The main challenge of pterygium management is the postoperative recurrence rate. Currently, the use of surgical sutures for conjunctival autograft fixation, which has prolonged surgery duration, has a risk of increased inflammation and infection. Recently, some reports about autologous blood coagulum (ABC) for conjunctival autograft fixation. This technique has a minimal cost and minimal risk of infection. **Purpose:** The study aimed to evaluate the postoperative recurrence rate and graft stability after using ABC and sutures. **Methods:** A systematic research was done on Pubmed, Cochrane Library, and Science Direct online databases for all relevant randomized controlled trials (RCTs) up to 18 July 2020. The collected RCTs were independently screened and identified to match the inclusion criteria. The relevant data were compiled in population, intervention, control, outcomes (PICOs) format and analyzed with Review Manager 5.3 software. **Results:** Nine RCTs involving a total of 764 patients were assessed. The primary outcome indicates that ABC significantly reduced the recurrence rate compared to sutures (RR = 0.51, 95% CI 0.27 to 0.98, p = 0.04). Meanwhile, in graft stability, the suture was statistically better than ABC (RR = 1.95, 95% CI 1.27 to 3.01, p = 0.002). As a secondary outcome, the duration of surgery was significantly shorter in ABC than in sutures (MD -15.22, 95% CI -22.57 to -7.88, p < 0.0001). **Conclusions:** Although the graft is less stable, ABC may be a promising approach after pterygium excision. The use of autologous blood for conjunctival autograft fixation in primary pterygium was associated with a lower recurrence rate and shorter duration of surgery.

**Keywords:** autologous blood coagulum (ABC); conjunctival autograft; primary pterygium

**Introduction**

Pterygium is a fibrovascular proliferative disorder characterized by a triangular wedge-shaped growth from the bulbar conjunctiva to the cornea. It can cause eye irritation, slight heaviness or repeated redness, cosmetic problems, and astigmatism.<sup>[1]</sup> The prevalence of pterygium varies from 0.3% to 37.46% in different regions worldwide. The prevalence of pterygium varies widely with age, sex, and socioeconomic background.<sup>[2]</sup> Ultraviolet (UV) rays are the most well-known risk factor. Both the intensity and duration of UV radiation exposure are associated with morbidity.<sup>[3]</sup> Previous research<sup>[4],[5]</sup> has found that the prevalence of pterygium is higher in rural areas than in urban areas because rural residents are more likely to engage in outdoor activities. In addition, increasing age was positively correlated with the prevalence of pterygium, and the higher the latitude, the lower the prevalence. It is known that lower latitudes receive more sunlight.

A critical step in the treatment of pterygium is the removal of the hyperplastic tissue. However, simple excision without a graft is associated with a high recurrence rate.<sup>[6]</sup> Current treatments for pterygium recurrence include

beta rays, excimer lasers, argon lasers, thiotepa and antimetabolites, conjunctival autografts, and amniotic membrane transplantation.<sup>[7]</sup> Autologous conjunctival transplantation with or without limbal stem cells is a popular surgical treatment for pterygium because of its low recurrence rate and no complications.<sup>[8]</sup>

The most commonly used method of autologous conjunctival fixation is a suture, however, it has disadvantages such as long operation time, infection, inflammation, suture abscess, and postoperative patient discomfort.<sup>[9]</sup> The latest autologous conjunctival fixation method is autologous blood coagulum (ABC). With this technique, the bleeding vessels are not coated, which allows a thin layer of blood to form on the sclera. The graft is then pressed against this thin layer, allowing the natural blood clot to hold.<sup>[10]</sup> The advantages of using ABC techniques are that the material is available to the patient, has the lowest cost, causes minimal infection, involves no risk of blood-related disease, and avoids complications associated with the use of sutures. Graft fixation using an ABC reduces patient discomfort and shortens operative time.<sup>[11]</sup>

Ophthalmologists in various countries have developed randomized controlled trials (RCTs) studies of this method to evaluate its safety and efficacy. To determine the overall effectiveness of the existing RCTs, this study would like to summarize the RCT results regarding the effectiveness of the ABC on the conjunctival autograft technique in pterygium surgery compared to sutures in a meta-analysis study. This study evaluates the postoperative recurrence rate and graft stability after using ABC and sutures.

## Methods

### Data search method

This systematic review was based on the Cochrane Handbook for Systematic Reviews of Intervention guidelines and PRISMA guidelines.<sup>[12],[13]</sup> A computer-based data search was carried out independently by each author. Two investigators (AK and MP) performed the literature screening independently and determined the eligibility of the studies. Any disagreements between independent investigators were resolved by discussion and/or consultation with the senior investigator (DL). We searched for relevant studies for ten years, from January 2010 to December 2020. We limit the study because the ABC studies have been relatively new in the last ten years. Using keywords with the relevant Medical Subject Headings (MeSH) format that consist combining of (“primary pterygium”) or (“pterygium”) and (“conjunctival autograft”) or (“autologous graft conjunctival”) or (“conjunctival graft”) and (“autologous blood coagulum”) or (“blood coagulum”) were inputted

in search engines, including Pubmed, Cochrane Library, and ScienceDirect. We use Boolean operators to improve search results. Data pooling was done from June 2020 to July 2020.

### Eligibility criteria

The inclusion criteria of this study were RCTs, with the study population consisting of male and female patients aged 18-75 years with primary pterygium who underwent pterygium excision procedures and reconstruction using conjunctival autograft with ABC fixation or suturing technique. The process of blood coagulum intervention in each study is shown in Table 1. Suturing technique was used as a comparison while ABC as an intervention in this study. In addition, the exclusion criteria were irretrievable full text, incompatible language, unrelated topic, incorrect study method, and incorrect population, intervention, control, outcomes (PICOs), also patients with recurrent or atrophic pterygium, pseudopterygium, Sjogren syndrome, dry eye disease, previous intraocular surgery, other ocular disorders, coagulopathies and patients on anticoagulation therapy. Acquired studies were initially screened to exclude non-human studies, non-RCTs, unrelated study topics, and studies published in languages other than English and Indonesian. The search results of the journals we get from the database we collect in a folder in the Zotero application, then we eliminate the same journals from different databases. This study aims to determine the postoperative recurrence rate and graft stability following ABC and sutures. Standards and variations of procedures for using an ABC are listed in Table 1—the postoperative recurrence rate and graft stability as primary outcomes and duration of surgery as secondary outcomes. Graft stability was assessed in terms of the number of patients with graft retraction, displacement, dehiscence, or graft loss.

### Data synthesis and bias assessment

Authors identified RCTs regarding the effectiveness of the ABC on the conjunctival autograft technique in pterygium surgery compared to sutures. Data were extracted in a table. Collected studies were then reviewed to ensure synchronous outcomes and enable comparison. Data extraction was based on author and year of publication, study design and setting, number of samples, recurrence rate, graft stability, and duration of surgery. This study followed the PRISMA flow diagram. The author used Cochrane Collaboration Tools to assess the risk of bias using seven specific portions: random sequence generation, allocation concealment, blinding participants and personnel, blinding of outcome assessment, incomplete outcome data, selective outcome reporting, and another source of bias. The overall effect

**Table 1.** Characteristics of included studies.

Author	Country	Population	Number of patients (T/C)	Intervention	Control	Process of ABC
Mahmud et al., 2019	India	Pterygium	76/100	Fixation with ABC	Suture with 10/0 nylon	The ABC method allowed the bare sclera to bleed freely for around 3-4 minutes. The conjunctival autograft is then removed, and the bare sclera is replaced. The surgeon waited around ten minutes before gently pressing the graft to promote fibrin production.
Celik, 2018	Turkey	Pterygium	15/15	Fixation with ABC	Suture with 10/0 nylon	For around 3-4 minutes, the bare sclera was allowed to bleed naturally. The conjunctival autograft is then removed, and the bare sclera is replaced. The surgeon waited around ten minutes for fibrin production and adhesion. Apply minimal pressure over the graft to assist in compliance.
Phani, 2017	India	Pterygium	50/50	Fixation with ABC	Suture with 8/0 nylon	A thin layer of fresh blood must be applied over the bare sclera to give autologous fibrin. Hemostasis was allowed to occur spontaneously without using cautery to supply autologous fibrin for naturally attaching the conjunctival autograft in place without tension. The graft was fixed in place for ten minutes with mild pressure applied over the graft.
Ashok et al., 2015	India	Pterygium	25/25	Fixation with ABC	Suture with 10/0 nylon	For ten minutes, the graft was kept in the place of the scleral bed using mild pressure applied with fine non-toothed forceps. There is usually a tiny amount of serum oozing in the scleral bed following a minor bleed, which acts as an adhesive. The significant hemorrhage causes the graft to be lifted from the scleral bed, resulting in problems and should be tamponade before placement.
Singh et al., 2020	India	Pterygium	40/40	Fixation with ABC	Suture with 8/0 vicryl	After excising the pterygium, an autograft was placed over the oozing blood. The autograft was pressed with the assistance of an iris reposer to ensure good adhesion to the bare sclera. Excess blood was cleaned up around the graft with sterile cotton swabs. Fibrin in the oozed blood functions as a glue to hold the graft in place.
Tanie et al., 2017	India	Pterygium	15/15	Fixation with ABC	Suture with 8/0 vicryl	The episcleral vessels were stimulated to bleed to generate a coagulum. If there was significant bleeding, it was stopped until there was enough to form a coagulum. For ten minutes, mild pressure was applied to this graft with McPherson forceps to ensure that the graft was attached to the underlying sclera through the blood coagulum.
Bin et al., 2019	China	Pterygium	39/34	Fixation with ABC	Suture with 10/0 nylon	They were applying mild pressure to the autograft to expel blood and exudate. Transient hemorrhages were controlled during the operation using direct compression with sponges. When hemorrhages persisted, precaution was taken.
Telang et al., 2017	India	Pterygium	25/25	Fixation with ABC	Suture with 10/0 nylon	Few punctures were made on the bare sclera with a 26 G needle to provide autologous fibrin on small perforating veins and capillaries to encourage a thin layer of blood to cover the bare sclera. The conjunctival limbal graft was slid into the recipient bed, maintaining a limbus to limbus orientation. The graft was placed on a bare sclera. Care was taken to ensure no residual bleeding to re-lift the graft, and direct compression was applied until the hemostasis was achieved, usually ten minutes.
Suryawanshi et al., 2020	Oman	Pterygium	35/90	Fixation with ABC	Suture with 8/0 vicryl	A 26-G needle was used to cut a tiny conjunctival blood artery, and blood was allowed to drip over the bare sclera before transplanting.

size estimate was pooled as risk ratio (RR) and mean difference (MD) with 95% CI for binary and continuous outcomes. The fixed-effects model was chosen to synthesize data if the included studies show no or little heterogeneity ( $p > 0.1$ ,  $I^2 < 50\%$ ). We picked the random-effect model when the heterogeneity was significant ( $p < 0.1$  and  $I^2 > 50\%$ ). Review Manager application 5.3 was used for statistical analysis (version 5.3.5, Cochrane Collaboration, Denmark). Statistical significance was defined as a P-value of less than 0.05.

We assessed potential bias in the published literature using funnel plots from the included studies in the Review Manager application. We performed an Egger's test of asymmetric analysis of the funnel plots using the JASP 0.16.1.0 application.

### Sensitivity analysis

Sensitivity analysis in this study were performed by repeating the primary analysis with modified data sets or statistical methods to determine whether these changes

had any effect on the outcome. This analysis is repeated by changing the number of included studies (more often reducing the number of included studies) based on the results of the study bias assessment or study size. In addition, changes to statistical methods are also made by changing between random and fixed effects to see the difference. The results of the sensitivity analysis were presented as a summary table.

## Results

### Study characteristics

The study selection process is shown in Figure 1. RCTs were used in the nine studies<sup>[7],[14],[15],[16],[17],[18],[19],[20],[21]</sup> that matched the inclusion criteria. Table 1 lists the characteristics of the nine studies. In total, 714 patients were included in this meta-analysis, 320 of whom were treated with ABC, and the remaining 394 were control populations with sutures.

All inclusion studies used conjunctival autograft after excision of pterygium. There were five studies in the control group using 10-0 nylon for fixation of the graft, three studies using 8-0 vicryl and one study using 8-0 nylon. All case groups used the patient's blood for conjunctival graft fixation, and almost all studies gave about ten minutes for hemostasis to occur. The process of using ABC from each study is further explained in Table 1.

The primary outcome of this study was the recurrence rate, as defined as fibrovascular growth extending beyond 1.5 mm into the cornea at the site of previously removed pterygium. Another primary outcome measure in this study is graft stability, defined by the number of patients who experienced graft retraction, displacement, dehiscence, or loss, even though only six of the included studies investigated graft stability. Duration of operation is a secondary outcome in this analysis, which included only six studies that analyzed it. It was defined as the

time interval between the start of pterygium dissection and the removal of the lid speculum.

### Risk of bias assessment

The risk of bias in each included study shown in Figure 2. All nine studies did randomization, but six studies<sup>[7],[14],[16],[17],[19],[20]</sup> have a low risk of bias in the “random sequence generation” parameter by elaborating the randomization method. Two studies<sup>[20],[21]</sup> did not explain the randomization method, and one study<sup>[18]</sup> had a high risk of bias assessment in this parameter. Five studies<sup>[14],[16],[17],[19],[20]</sup> have a low risk of bias in the “allocation concealment” parameter. All of the included studies have an unclear risk of bias in the “blinding” parameters because the reviewers did not find the blinding statement in each study. The other reason is reviewers assume that the protocols of each study are difficult to blind; first, the participant must have informed consent so the intervention couldn't be blind to the participant; second, the surgery operator and the outcomes assessor could differentiate and find whether the participant had intervention method or control method quickly. So the reviewers think that blinding assessment in all studies is hard to apply. On the “incomplete outcome data” parameter, eight studies<sup>[7],[14],[15],[16],[17],[18],[19],[20]</sup> have a low risk of bias, while on the “selective reporting” parameter, eight studies<sup>[7],[14],[15],[16],[17],[18],[19],[20]</sup> have a low risk of bias. The risk of bias assessment of the included studies is summarized in Figure 3.

### Sensitivity analysis

In sensitivity analysis, the recurrence results between ABC and suture were not statistically significant (Table 2). Different from the outcome of graft stability, where there was a statistically significant difference between the ABC and suture. In the outcome of the duration of surgery,

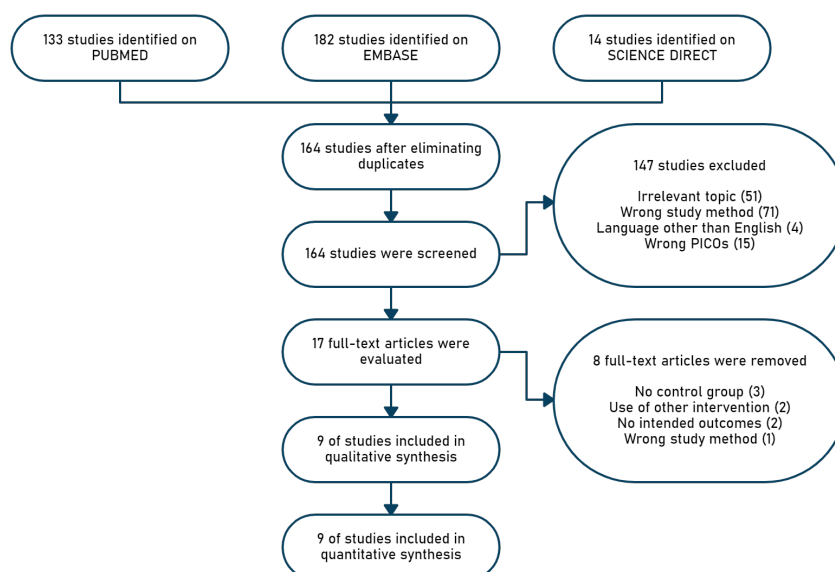


Figure 1. Study selection process.

	Random sequence generation (selection bias)	Allocation concealment (selection bias)	Blinding of participants and personnel (performance bias)	Blinding of outcome assessment (detection bias)	Incomplete outcome data (attrition bias)	Selective reporting (reporting bias)	Other bias
Ashok (2015)	+	+			+	+	
Bin (2019)	+	+			+	+	
Celik (2019)					+	+	
Mahmud (2019)	+	+			+	+	
Phani (2017)	+	+			+	+	
Singh (2020)					+	+	
Suryawanshi (2020)	-	-					
Tanie (2017)	+	+			+	+	
Telang (2017)	+	-			+	+	

Figure 2. Risk of bias assessment of each included studies.

there were also statistically significant differences between ABC and sutures. This sensitivity analysis was performed by excluding two studies<sup>[15],[21]</sup> from the initial primary analysis. Based on our study's bias analysis, both studies included low-quality bias.

**Comparing ABC with sutures for assessing recurrence rate**

From nine included trials, eight trials (644 participants, 644 pterygium operations) evaluated recurrence rates after surgery. A fixed-effect model is used due to significant homogeneity between studies ( $P = 0.88, I^2 = 0\%$ ). There is a statistically significant difference in the recurrence rate (Figure 4) after primary pterygium surgery using the conjunctival autograft method between graft fixation using ABC and sutures ( $RR = 0.51, 95\% CI$

$0.27 - 0.98, p = 0.04$ ), indicating that recurrence rate was lower in ABC than the suture. Egger's asymmetry test on the funnel plot represents no publication bias between studies ( $p = 0.8; p > 0.1$ ) (Figure 5 and Table 3).

**Comparing ABC with sutures for assessing graft stability**

From nine included trials, six trials (614 participants, 614 pterygium operations) evaluated graft stability after surgery. A fixed-effect model is used due to significant homogeneity between studies ( $P = 0.36, I^2 = 9\%$ ). There is a statistically significant difference in graft stability (Figure 6) after primary pterygium surgery using the conjunctival autograft method between graft fixation using ABC and sutures ( $RR = 1.82, 95\% CI 1.14 - 2.90, p = 0.01$ ), indicating that suture provided better graft stability than ABC.

**Comparing ABC with sutures for assessing the duration of surgery**

From nine included trials, six trials (433 participants, 433 pterygium operations) evaluated the duration of surgery. The random group model is used due to significant heterogeneity between studies ( $P < 0.00001, I^2 = 99\%$ ). There is a statistically significant difference in duration of surgery (Figure 7) after primary pterygium surgery using the conjunctival autograft method between graft fixation using ABC and sutures ( $RR -15.72, 95\% CI -22.86 - 8.58, p < 0.00001$ ), indicating that ABC provided a shorter duration of surgery than the suture.

**Discussion**

Nine studies found that the recurrence rate was significantly lower in ABC than in sutures. Based on the statistical analysis of this study, ABC has an efficacy value in reducing the risk of recurrence by 51% compared to sutures (the incidence of blood coagulum recurrence is 1/2 times lower than sutures). This finding is different from the meta-analysis by Zein et al.<sup>[22]</sup> where from these, studies, the recurrence rate did not differ significantly between blood coagulum and suture. This could be because the number of studies that were used was less.

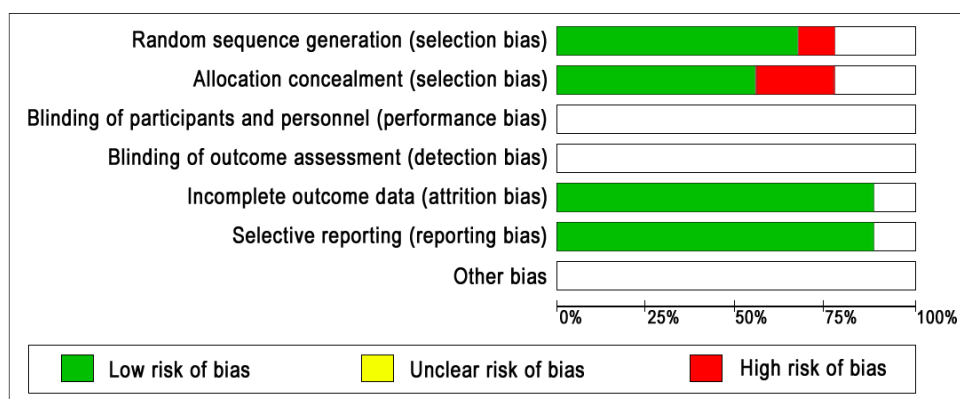


Figure 3. Summary of risk of bias assessment based on each parameter.



Table 2. Sensitivity analysis.

Outcomes	Number of studies	Number of case		RR (95% CI)	Test of homogeneity		P-value
		Blood coagulum	Suture		I <sup>2</sup> (%)	p-value	
Reccurence	6	9/245	18/264	0.54 (0.26 – 1.10) <sup>a</sup>	0	0.87	0.09
Graft Stability	6	34/245	14/264	2.32 (1.32 – 4.06) <sup>a</sup>	31	0.2	0.003

Outcomes	Number of studies	Number of participants		Mean difference (95% CI)	Test of homogeneity		P-value
		Blood coagulum	Suture		I <sup>2</sup> (%)	p-value	
Duration of surgery	5	179	174	-11.45 (-14.01 s.d -8.90) <sup>b</sup>	94	<0.00001	<0.00001

Note: <sup>a</sup>Fixed effect model and <sup>b</sup>Random effect model.

Zein et al.<sup>[22]</sup> used four studies from 2013 to 2015; and this study used nine references from 2015 to 2020. The more studies included as material for analysis, the more valid the analysis results; on the other hand, the newer study will also increase the study's validity. The procedure of ABC was bare sclera allowed to bleed spontaneously for about 3–4 minutes. Then conjunctival autograft was replaced with the bare sclera. The surgeon waited about ten minutes by applying gentle pressure over the graft to adhere to fibrin formation.

Recurrence following successful excision presents a concern in pterygium surgery. In a research conducted by Huda and Khaleque<sup>[14]</sup>, using the ABC technique can minimize the recurrences; not one pterygium recurred after three months of surgery. The occurrence of recurrences in the pterygium is multifactorial. Numerous studies have demonstrated that postoperative inflammation promotes the proliferation of blood vessel cells and fibroblasts, as well as subconjunctival fibroblast tissue, and the overexpression of matrix metalloproteinases leads to pterygium invasion.<sup>[23]</sup> The lower recurrence rate with the ABC is due to decreased postoperative inflammation.<sup>[24]</sup> Moreover, using silk or nylon sutures might lead to inflammation and migration of Langerhans cells to the cornea.

In the study conducted by Wit et al.<sup>[25]</sup>, there were no recurrences in 15 eyes at a mean follow-up of 9.2 months. Using an ABC produces pressure over the entire graft surface. There is no direct pressure on the edges of the graft, which minimizes scar formation on the subconjunctival. The presence of sutures can cause a long healing process and fibrosis.<sup>[25]</sup>

In terms of graft stability, statistical analysis showed a significant difference between the ABC and the suture, where the suture provided better graft stability than the ABC. In this study, graft stability was a combination of the incidence of graft retraction, graft displacement, and graft loss. In the meta-analysis by Zein et al. (2018)<sup>[22]</sup>, not combining these parameters and separating, graft retraction and graft displace lower with sutures than the coagulum blood. Although this study combines one parameter, namely graft stability, the statistical analysis results are the same as those of Zein et al.<sup>[22]</sup>, where the stability of the graft is more stable in the suture than in the blood coagulum.

In the study of Singh et al.<sup>[2]</sup>, graft displacement cases were higher in the group with ABC (7.1%) compared to the suture group. It is thought that a graft displacement may occur when the patient rubs the eye operated on inappropriately due to a foreign body sensation.

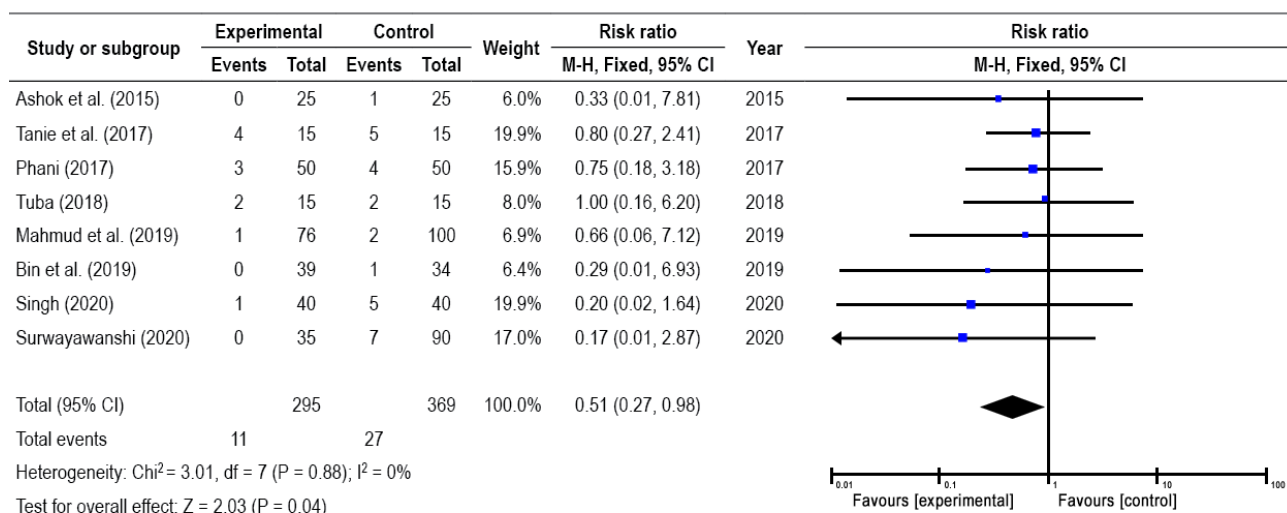


Figure 4. Forest plot for subgroup analysis comparing ABC with sutures for assessing recurrence rate.

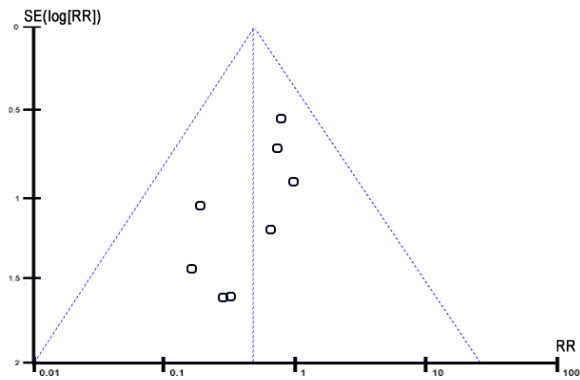


Figure 5. Funnel plot recurrence of ABC versus suture group.

This is supported by Zein et al.<sup>[22]</sup>, which state that In ABC, the risk of graft displacement is fivefold that of sutures. Graft displacement occurred due to the graft's large size, removal of the bandage before 48 hours postoperatively, trauma, friction in the eye, and insertion of the tenon capsule into the graft. Meanwhile, graft retraction in the ABC has a three times higher risk than in sutures. The causes of graft retraction reported are large grafts, graft edema, chemosis, and inclusion of tenon capsules in the graft. In addition, the movement of the graft due to the movement of the eyelids can cause graft displacement.<sup>[26]</sup> The disadvantage of having an ABC is challenging to manage the amount of blood in the sub

Table 3. Egger's test from the funnel plot (regression test for funnel plot asymmetry).

	z	p
Sei	-0.251	0.802

graft; when more blood flows, a large clot is expected to form under the graft, and the contractions are caused by the clot results in the graft being released.<sup>[11]</sup>

In terms of duration of surgery, statistical analysis showed a significant difference between the use of blood coagulum and suture, where coagulum blood provided a shorter duration of surgery than the suture. This is also to a meta-analysis study by Zeng et al.<sup>[22]</sup>, where the blood coagulum provides a shorter duration of surgery. Suture-based graft fixation involves additional surgical procedures and a more extended period of operation, whereas autologous blood coagulum fixation is generally quick and straightforward. Surgery is performed in less time, leading to cheaper operating expenses, more patient satisfaction, and a decreased risk of infection.

However, The data analysis on autologous blood and sutures showed a high degree of heterogeneity. One explanation is that surgeons' abilities differ. Additionally, the duration of surgery was defined inconsistently between studies.<sup>[6]</sup> In addition, the method of each

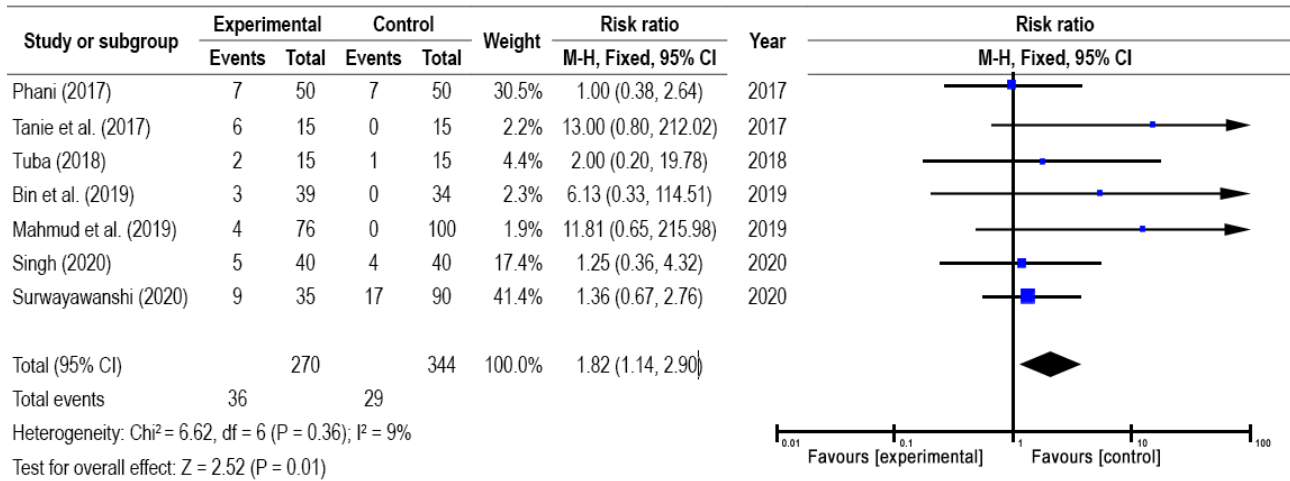


Figure 6. Forest plot for subgroup analysis comparing ABC with sutures for assessing graft stability.

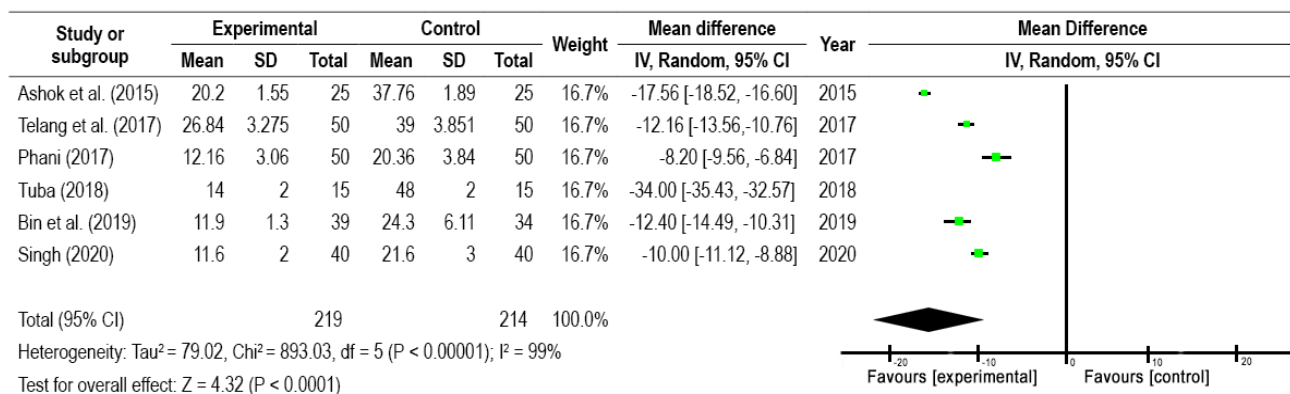


Figure 7. Forest plot for subgroup analysis comparing ABC with sutures for assessing duration of surgery.

journal does not blind the participants, personnel, and outcomes, so it is difficult for us to take the risk of biased parameters. Suggestions in this study were conducted in a multicenter RCTs study to get results with a larger population. Also made guidelines regarding ABC to have a uniform technique.

## Conclusions

In conclusion, although the graft is less stable, autologous blood coagulum may be a promising approach after pterygium excision. The use of autologous blood for conjunctival autograft fixation in primary pterygium was associated with a lower recurrence rate and shorter duration of surgery.

## References

- [1] Kumar A, Gupta D. Sutureless, glue-free conjunctival-limbal autograft in the management of primary pterygium. *Indian J Appl Res* 2019;9:7–9.
- [2] Singh H, Laad S, Pattebahadur RS, Saluja P, Ramnani P. A comparative study of postoperative outcome after pterygium excision using autologous blood and sutures. *J Evid Based Med Healthc* 2017;4:6022–6027.
- [3] Chen T, Ding L, Shan G, Ke L, Ma J, Zhong Y. Prevalence and racial differences in pterygium: A cross-sectional study in Han and Uygur adults in Xinjiang, China. *Invest Ophthalmol Vis Sci* 2015;56:1109–1117. <https://doi.org/10.1167/iov.14-15994>.
- [4] Lin AD, Miles K, Brinks M V. Prevalence of pterygia in Hawaii: Examining cumulative surfing hours as a risk factor. *Ophthalmic Epidemiol* 2016;23:264–268. <https://doi.org/10.3109/09286586.2015.1119284>.
- [5] Li Z, Wu S, Mai J, Xu K, Sun Y, Song Z, et al. Prevalence of and risk factors for pterygia in a rural Northern Chinese population. *Ophthalmic Epidemiol* 2014;21:378–383. <https://doi.org/10.3109/09286586.2014.967359>.
- [6] Zeng W, Dai H, Luo H. Evaluation of autologous blood in pterygium surgery with conjunctival autograft. *Cornea* 2019;38.
- [7] Telang OJ, Joshi MS, Parekh B. Comparison between pterygium excision with conjunctival autograft with autologous blood vs. sutures. *J Evid Based Med Healthc* 2017;4:5991–5997.
- [8] Hacioglu D, Erdöl H. Developments and current approaches in the treatment of pterygium. *Int Ophthalmol* 2017;37:1073–1081. <https://doi.org/10.1007/s10792-016-0358-5>.
- [9] Boucher S, Conlon R, Teja S, Teichman JC, Yeung S, Ziai S, et al. Fibrin glue versus autologous blood for conjunctival autograft fixation in pterygium surgery. *Can J Ophthalmol* 2015;50:269–272. <https://doi.org/10.1016/j.jcjo.2015.04.011>.
- [10] Choudhury S, Dutta J, Mukhopadhyay S, Basu R, Bera S, Savale S, et al. Comparison of autologous in situ blood coagulum versus sutures for conjunctival autografting after pterygium excision. *Int Ophthalmol* 2014;34:41–48. <https://doi.org/10.1007/s10792-013-9790-y>.
- [11] Singh PK, Singh S, Vyas C, Singh M. Conjunctival autografting without fibrin glue or sutures for pterygium surgery. *Cornea* 2013;32:104–107. <https://doi.org/10.1097/ICO.0b013e31824bd1fb>.
- [12] Higgins JPT, Green S, editors. *Cochrane Handbook for Systematic Reviews of Interventions*. 1st ed. New Jersey: Wiley; 2008.
- [13] Page MJ, McKenzie JE, Bossuyt PM, Boutron I, Hoffmann TC, Mulrow CD, et al. The PRISMA 2020 statement: An updated guideline for reporting systematic reviews. *BMJ* 2021;372. <https://doi.org/10.1136/bmj.n71>.
- [14] Huda MMU, Khaleque SA. Comparison between Sutureless and Glue Free versus Sutured Limbal Conjunctival Autograft in Primary Pterygium Surgery. *Med Today* 2019;31:1–8. <https://doi.org/10.3329/medtoday.v31i1.40313>.
- [15] Celik T. In Situ Blood Coagulum versus Sutures for Autograft Fixation after Pterygium Excision. *Curr Eye Res* 2018;43:977–980. <https://doi.org/10.1080/02713683.2018.1470247>.
- [16] Sarkar P. A comparative study of suturing and sutureless/glue free limbal conjunctival autograft for primary pterygium surgery: A hospital based study. *IOSR J Dent Med Sci* 2017;16:30–37.
- [17] Sharma A, Raj H, Gupta A, Raina AV. Sutureless and glue-free versus sutures for limbal conjunctival autografting in primary pterygium surgery: A prospective comparative study. *J Clin Diagn Res* 2015;9:NC06–NC09. <https://doi.org/10.7860/JCDR/2015/15689.6789>.
- [18] Singh S, Sonwani P, Shrivastava M. Comparison of conjunctival autograft technique using autologous blood as glue versus suture technique in pterygium surgery. *Ophthalmol Res An Int J* 2020;12:7–14. <https://doi.org/10.9734/or/2020/v12i130137>.
- [19] Natung T, Kreditsu A, Shullai W, Goswami PK. Sutureless, glue-less conjunctival autograft versus conjunctival autograft with sutures for primary, advanced pterygia: An Interventional Pilot study. *J Clin Diagn Res* 2017;11:NC04–NC07. <https://doi.org/10.7860/JCDR/2017/23839.10419>.
- [20] Yan B, Peng L, Peng H, Zhou S, Chen B. Modified sutureless and glue-free method versus conventional sutures for conjunctival autograft fixation in primary pterygium surgery: A randomized controlled trial. *Cornea* 2019;38:1351–1357. <https://doi.org/10.1097/ICO.0000000000002137>.
- [21] Suryawanshi MP, Isaac R, Suryawanshi MM. Pterygium excision with conjunctival autograft fixed with sutures, glue, or autologous blood. *Oman J Ophthalmol* 2020;13:13–17. [https://doi.org/10.4103/ojo.OJO\\_113\\_2019](https://doi.org/10.4103/ojo.OJO_113_2019).
- [22] Zein H, Ismail A, Abdelmongy M, Elsherif S, Hassanen A, Muhammad B, et al. Autologous blood for conjunctival autograft fixation in primary pterygium surgery: A



- systematic review and meta-analysis. *Curr Pharm Des* 2018;24:4197–4204. <https://doi.org/10.2174/1381612824666181001161352>.
- [23] Nadarajah G, Ratnalingam VH, Mohd Isa H. Autologous blood versus fibrin glue in pterygium excision with conjunctival autograft surgery. *Cornea* 2017;36:452–456. <https://doi.org/10.1097/ICO.0000000000001106>.
- [24] Maiti R, Mukherjee S, Hota D. Recurrence rate and graft stability with fibrin glue compared with suture and autologous blood coagulum for conjunctival autograft adherence in pterygium surgery: A meta-Analysis. *Cornea* 2017;36:1285–1294. <https://doi.org/10.1097/ICO.0000000000001270>.
- [25] de Wit D, Athanasiadis I, Sharma A, Moore J. Sutureless and glue-free conjunctival autograft in pterygium surgery: A case series. *Eye (Lond)* 2010;24:1474–1477. <https://doi.org/10.1038/eye.2010.75>.
- [26] Peeush P, Sarkar P. A comparative study of pterygium excision using autologous blood versus Sutures: A study from remote Eastern Bihar, India. *Ophthalmol Res An Int J* 2014;3:28–32. <https://doi.org/10.9734/OR/2015/12466>.