



## CASE REPORT

## Comprehensive Management of Preseptal Cellulitis with Massive Palpebral Abscess in 72-year-old Man

**Authors:**Ruth Anastasia\*<sup>ORCID</sup>Ismi Zuhria<sup>ORCID</sup>Susy Fatmariyanti<sup>ORCID</sup>**Affiliations:**

Department of Ophthalmology,  
Faculty of Medicine, Universitas  
Airlangga–RSUD Dr. Soetomo  
Surabaya, Indonesia.

**Corresponding author:**

Ruth Anastasia  
ruth.anastasia-2020@  
fk.unair.ac.id

**Dates:**

Received: 17 March 2022

Revised: 23 September 2022

Accepted: 03 October 2022

Published: 10 November 2022

**DOI:**

[https://doi.org/10.20473/  
vsehj.v2i1.2022.1-5](https://doi.org/10.20473/vsehj.v2i1.2022.1-5)

**Copyright:**

© 2022 Author(s). Open  
access under Creative  
Commons Attribution-Share  
Alike 4.0 International  
Licence (CC-BY-SA).

**Abstract**

**Introduction:** Infectious inflammation of the periorbital and orbital soft tissue can be classified as preseptal (periorbital) or postseptal (orbital) cellulitis. Eyelid abscess, an accumulation of pus in the palpebral tissue, can occur in isolation or in association with preseptal cellulitis. Preseptal cellulitis is nearly three times more common than orbital cellulitis. **Case Presentation:** The patient, in this case, was admitted with a complaint of swollen left eyelid ten days before being admitted. Swollen eyelid with the inability to open the left eye was accompanied by pus discharge five days before coming to the hospital. Current complaints include eyelid pain, swelling, and discharge of thick yellow fluid. Massive abscess with active pus and crust was present in the left superior and inferior eyelid and frontotemporal area. A head CT scan revealed a soft tissue mass in the left sub galea soft tissue, left frontal region, left orbit, and left temporal region. Multi-department consultations and several workups were done to reveal the etiology and plan the appropriate management of this condition. **Conclusion:** A comprehensive assessment must be done to distinguish preseptal and orbital cellulitis. Ophthalmology examination and imaging are crucial to detect any extension of the palpebral abscess beyond the orbital septum. Examining an immunocompromised state and focal infection is crucial in determining proper treatment.

**Keywords:** preseptal cellulitis; palpebral abscess; comprehensive assessment

**Introduction**

Infectious inflammation of the periorbital and orbital soft tissue caused by bacteria can be classified as preseptal (periorbital) or postseptal (orbital) cellulitis.<sup>[1]</sup> The incidence rate of cellulitis is about 24.6/1.000 persons, with a higher incidence among males and individuals aged 45-64. This condition is a potentially severe infection caused by bacteria. This pathogen infiltrates the deep layers of skin and subcutaneous tissue.<sup>[2]</sup> Symptoms of cellulitis include erythema, warmth, swelling, tenderness, fever, and formation of blisters and abscesses.<sup>[3]</sup> Preseptal cellulitis involves structures anterior to the orbital septum, while orbital cellulitis involves posterior structure to the orbital septum and presents more severe manifestations.<sup>[4]</sup>

Preseptal cellulitis is nearly three times more common than orbital cellulitis. There is no gender predilection in preseptal cellulitis, while orbital cellulitis has male predominance and is also more common in winter because of its association with the upper respiratory tract and paranasal infections. Management of preseptal cellulitis includes a proper diagnostic approach and appropriate antibiotic therapy.<sup>[5]</sup>

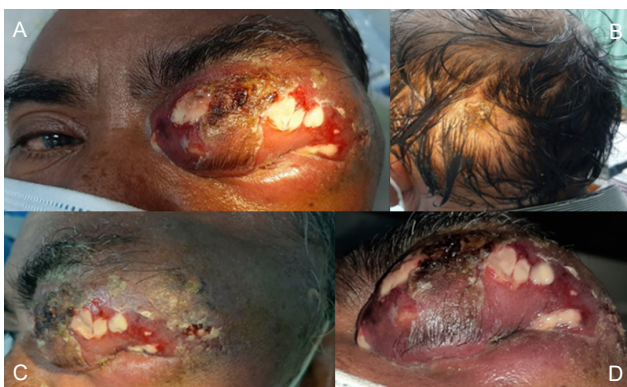Lid abscess is the accumulation of pus in the palpebra, generally caused by trauma, local spread of infection from surrounding adnexa such as internal hordeolum, sinusitis, and endogenous spread through blood. Staphylococcus aureus, Staphylococcus epidermidis, Group A Beta-Hemolytic Streptococci, and anaerobes microorganisms are the most common organisms associated with this manifestation.<sup>[3]</sup>

## Case presentation

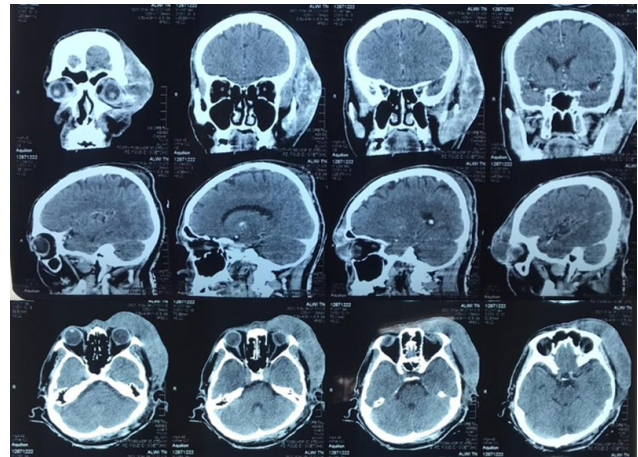
A 72-year-old male came to the emergency room complaining of swollen left eyelid ten days before being admitted. Swollen eyelids with the inability to open the left eye were accompanied by pus discharge five days before. Current complaints include eyelid pain, swelling, and discharge of thick yellow fluid. Two months ago, the patient complained of a small wound on the back of his head that was followed by the presence of a boil, and pus came out of the boil often. This condition has not improved yet, and the boil has never been treated. A history of thick yellow discharge from the nose and discharge from the ear, ear pain, cavities, prolonged cough, tuberculosis treatment, thrush, and significant weight loss was not found. The patient occupation was a manual laborer (scavenger). The patient denied a history of diabetes mellitus and hypertension. History of trauma was denied.

The general condition was moderately ill, however, the patient's vital signs were stable. The left eye's visual acuity was challenging to evaluate, while the right eye's 5/8 pinhole was not improved. The intraocular pressure of the left eye also could not be evaluated, while the right eye was normal palpation. The examination of the anterior segment of the left eye revealed edema and cystic mass temporally measuring about 40 mm with pus, necrotic tissue, bleeding, crusting, and erythema preset on the eyelid. The left eye's conjunctiva, cornea, anterior chamber, iris, pupil, and lens could not be evaluated. In the right eye, anterior segment conjunctival and pericorneal hyperemia were found. The posterior segment of the right eye was within normal limits (Figure 1).

Laboratory study found leukocytosis (17.750/uL) and hyperglycemia (398 mg/dl). The chest X-ray revealed pulmonary inflammation with thickening of the upper and lower right pleura. Fibrotic appearance in the right superior hilar and left paracardial regions, possibly overlapping with active lesions, have not been ruled out. The head CT scan revealed a soft tissue mass with



**Figure 1.** Clinical presentation of the patient; (A),(C-D) large abscess measuring about 4 mm on palpebra that continued laterally with active pus, necrotic tissue, crusting, bleeding, and erythema; and (B) on the temporal region, an abscess with crusting extended to the anterior area.



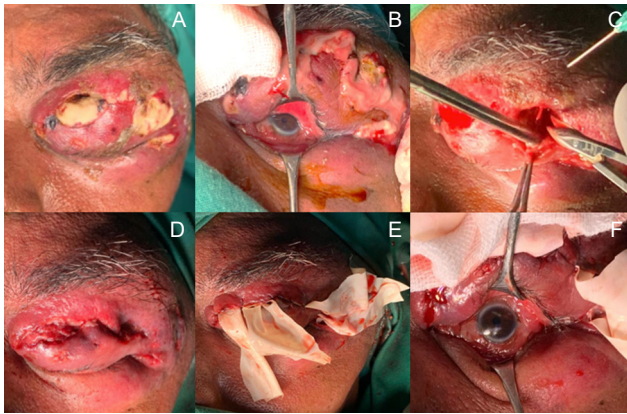
**Figure 2.** A Head CT scan showed soft tissue mass in the left sub-galeal, left frontal region, and left orbit to the left temporal that did not exceed the orbital septum indicating preseptal cellulitis.

thick fluid density with firm boundaries, irregular edges measuring 10.04 x 2.68 x 9.88 cm in the left sub galea soft tissue, left frontal region, left orbit to the left temporal that does not exceed orbital septum indicating preseptal cellulitis. No visible infarction, bleeding, infectious process, or mass was shown in the brain parenchyma (Figure 2).

The patient was planned to undergo a drainage incision with general anesthesia (joint operation with the head and neck surgery department). Monitoring the patient's blood glucose levels and examining the blood culture, pus, and antibody sensitivity were crucial in containing and managing the patient's infection. Injection of ceftriaxone 1 gr twice daily and metronidazole 500 mg three times daily were given to the patient as initial antibiotics. The patient was diagnosed with a left orbital abscess suspect. Multi-department consultations were sent to head and neck surgery; ear, nose, and throat (ENT); oral surgery; pulmonology; internal medicine; anesthesia; and the cardiology department.

Exploration showed necrotic tissue, crusts, and organized pus along the superior eyelid. The left superior palpebral area was debrided until the superior palpebral rupture due to the abscess was identified. There was a left palpebral abscess as deep as the superior orbital rim that extended to the brow area, medial and lateral canthus, and inferior palpebra that connected to the left temporal, occipital region with active pus. The conjunctiva was hyperaemic, and chemosis was present in the inferior bulbar conjunctiva. No conjunctival abscess was found, and the cornea was clear with a deep anterior chamber and cloudy lens. Drainage was carried out, then the area was irrigated with NaCl, and a handschoen drain was installed in seven locations. Eye movement evaluation with forced duction test revealed no obstruction and restriction. The head and neck surgery department continued abscess evacuation in the frontal-parietal area. The patient was assessed with left superior and





**Figure 3.** (A-B) Exploration of superior palpebra and anterior segment; (C-D-E) debridement of necrotic tissue, abscess evacuation, and instillation of handschoen drainage in the superior palpebra; (F) a reexamination of the anterior segment.

inferior palpebral abscess with immature senile cataract and left frontal-parietal abscess (Figure 3). Ceftriaxone 1 g IV q12hr, metronidazole 500 mg IV q8hr, analgetic, and gentamicin eye drop every four hours for the left eye were given as postsurgical therapy. After drainage, the patient's complaints, visual acuity, and anterior and posterior segment evaluations were monitored daily while in recovery in the ward. Advanced laboratory results showed a high level of HbA1c (13%), high fasting blood glucose, and two-hour postprandial glucose level (322 mg/dl, 350 mg/dl, respectively). The internal medicine department established the diagnosis of type 2 diabetes mellitus, and the patient was treated with insulin to control their blood sugar level.

Deep pus culture and gram stain were positive with coccus +2 (Staphylococcus aureus), PMN +4, and anaerobic bacteria were not found. The patient was sensitive to gentamicin, ceftriaxone, cotrimoxazole, chloramphenicol, erythromycin, clindamycin, ciprofloxacin, levofloxacin, and moxifloxacin according to antibiotic sensitivity test. Blood culture, sputum culture, and gene expert were found negative. Focal infection was not found from ENT, dental and pulmonology examinations.

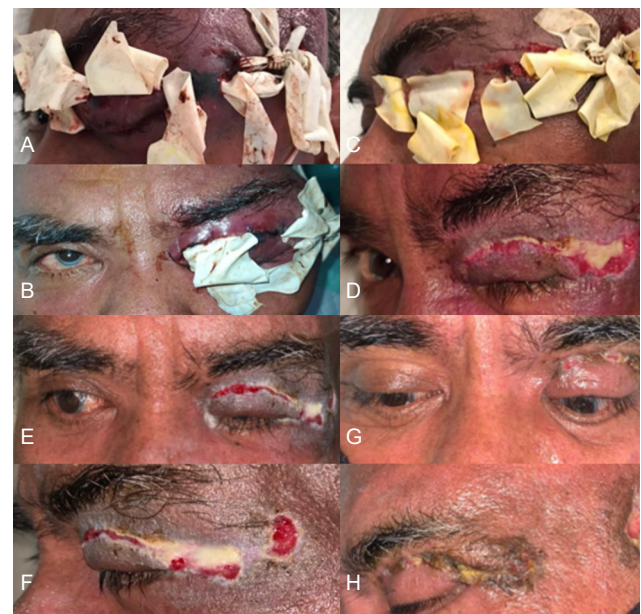Within five days of hospitalization, the size of the abscess reduced from its initial size to 3 x 2 x 1.5 cm. The visual acuity of the left eye was 5/12 pinhole no improvement (PHNI), and the right eye was 5/8 PHNI; cataract was present in both eyes. Normal ocular motility was found without any orbital pain or pupillary defect. The patient was discharged from the hospital, directed to the nearest health care for daily wound care, and scheduled for a follow-up at the eye clinic after two weeks. In the following examination (two weeks and one month control), the wound size shrunk to 3 x 1 x 0.2 cm with granulated tissue, no mass and undulation were found, and the palpebral function was improved (Figure 4).

## Discussion and conclusions

Eyelid abscess accumulation of pus in the palpebral tissue can be isolated or associated with preseptal

cellulitis. Preseptal cellulitis, also known as periorbital cellulitis, is an infection of the eyelid and superficial soft tissue without the involvement of the orbit and globe and typically presents with eyelid edema and erythema.<sup>[6]</sup> When the infection process extends beyond the orbital septum, the term orbital cellulitis is used. Both of these conditions are more common in children than in adults. Staphylococcus aureus and Group A Beta-Hemolytic Streptococci are the most common organisms associated with this manifestation.<sup>[6],[7]</sup>

There are three primary sources of bacterial and pathogen infection of the orbit, and periorbital soft tissue, which is direct inoculation such as insect bites or accidental cutaneous trauma, these kinds of infections are usually caused by streptococcus aureus. The following source is adjacent ocular adnexal infections, such as acute episodes of sinusitis, dacryocystitis, or hordeolum, which spread to the preseptal or postseptal spaces. Infection can also spread through hematogenous routes from a distant source of infection, such as otitis media or pneumonia.<sup>[4],[6]</sup> In this patient, the source of infection is most likely due to direct inoculation after trauma in the scalp area that spread through the subcutaneous connective tissue to the palpebral area. Several tests and consultations have been done to find other focal infections such as sinusitis, dental cavities, tuberculosis to tuberculosis necrotizing toxin (TNT), oral surgery, and pulmonology department, however, all proven negative. The risk of infection in the trauma site was significantly higher and became progressive due to untreated diabetes mellitus in the patient. The elevated level of serum glucose causes direct cell damage, indirect impairment through



**Figure 4.** Post-surgery follow-up; (A-B) one day after surgery, the wound size was 4 x 2 x 2 cm, erythema and pain in the eyelid were still presented; (C-D) five days after surgery, the handsoen drainage was carried out; (E-F) 13 days after surgery, edema, erythema, and pain in the palpebra have already been harmful, palpebral function has improved; (G-H) 43 days after surgery, the wound size has decreased to 3 x 1 x 0.2 cm with granulated tissue; no undulation was found.

advanced glycation end products (AGEs), dysfunction in vasodilation through inhibition of nitric oxide, promotes reactive oxygen species and causes oxidative stress that makes infection more progressive and severe.<sup>[6]</sup> Based on the culture results, *Staphylococcus aureus* was found in the pus. *Staphylococcus aureus* is a gram-positive bacterium that is a normal flora of the skin and, in certain circumstances, can be involved in folliculitis, abscesses, and other skin infections. In the case of recurring pyogenic skin infections, it was necessary to examine the presence of diabetes.<sup>[6]</sup>

It is essential to determine the source of the infection and proceed with the diagnosis. Preseptal cellulitis involves structures anterior to the orbital septum so that even though the inflammation is severe, the globe and deep orbital tissue remain uninvolved.<sup>[4]</sup> Nevertheless, distinguishing between the two conditions remains a challenge. In evaluating susceptible preseptal cellulitis, assessing for any orbital involvement is essential. The assessment should be a comprehensive ophthalmology examination such as visual acuity, pupillary response, tonometry, anterior segment, and ophthalmoscopy. As preseptal cellulitis involves structure anterior to the orbital septum, the standard visual acuity without limitation of ocular motility, proptosis, orbital pain, relative afferent pupillary defect (RAPD), and posterior segment involvement should be presented.<sup>[8]</sup> In this patient, visual acuity in both eyes was slightly decreased due to bilateral cataracts, however, ocular motility, pupillary reaction, and globe position were not disturbed. According to the clinical presentation, preseptal cellulitis was most likely the diagnosis. The CT scan of the orbit and sinuses remains the standard initial and definitive modality in diagnosing sinusitis and orbital extension. This modality is recommended for marked eyelid swelling, fever, leucocytosis, and suspected abscess.<sup>[3]</sup> From the CT scan result in the patient, the density, size, boundaries of the mass, and orbital involvement was visible and could facilitate the following patient management.

Patients with preseptal cellulitis usually do not require surgery except in the presence of a palpebral abscess.<sup>[9]</sup> Surgical incision with pus and debris drainage is the most proper treatment for abscesses. Additional antibiotic therapy can be helpful in insufficient drainage.<sup>[6]</sup> The treatment of this condition differs depending on the severity of the disease, and the age of patients.<sup>[10]</sup> True preseptal cellulitis responds rapidly to oral or intravenous antibiotics; initial antibiotic selection is based on the history, clinical findings, and laboratory studies. In adults, preseptal cellulitis is usually caused by an external source and responds to oral antibiotics and warm compresses. In older adults like our patients, response to antibiotics might be delayed, and surgical management to excise necrotic tissue might be necessary to clear the

infection. Especially in immunocompromised patients with uncontrolled diabetes mellitus, prompt treatment with intravenous antibiotics such as ceftriaxone or vancomycin, early hospitalization, and blood sugar level control are recommended.<sup>[4],[11]</sup> Infection in immunocompromised patients can progress posteriorly into the orbit, potentially leading to significant visual and cerebral complications.<sup>[3],[12]</sup> Complications can develop even with prompt treatment. According to Chandler's<sup>[13]</sup> classification of the orbital complications staging system, the possible orbital complications are inflammatory orbital edema, subperiosteal abscess, orbital abscess, and life-threatening cavernous sinus thrombosis. Continuous examination of complication signs should be done carefully. The prognosis of preseptal cellulitis is good, with prompt diagnosis and treatment.<sup>[14]</sup> The response to antibiotic therapy and incision drainage was excellent in this patient; the mass size was much reduced and wound healing was fast with adequate wound care and blood sugar control.

Preseptal cellulitis is an infection of the eyelid and superficial soft tissue without the involvement of the orbit and globe that can be associated with a palpebral abscess and is caused by several aetiologies. A comprehensive assessment must be done to distinguish preseptal and orbital cellulitis. Thorough ophthalmology examination and imaging are crucial to detect any extension of the palpebral abscess beyond the orbital septum. Assessing an immunocompromised state and focal infection is critical in determining proper treatment. Prompt initiation of appropriate antibiotic therapy is the primary management in treating preseptal cellulitis. Surgical drainage and debridement are recommended in the presence of a palpebral abscess. Culture and sensitivity results should be used to guide the therapy.

## References

- [1] Sagiv O, Thakar SD, Kandl TJ, Kontoyiannis DP, Debnam JM, Esmali B. Clinical course of preseptal and orbital cellulitis in 50 immunocompromised patients with cancer. *Ophthalmology* 2018;125:318–320. <https://doi.org/10.1016/j.ophtha.2017.10.006>.
- [2] Yamamoto M, Wakayama N, Hamajima Y, Miyata K, Takahashi H, Kobayakawa S. A rare case of palpebral cellulitis, a variation of Pott's puffy tumor. *Case Rep Ophthalmol* 2020;11:106–111. <https://doi.org/10.1159/000506225>.
- [3] Razali NR, Choo YM. Acute ptosis as a presentation of preseptal cellulitis leading to cerebral abscess in a patient with uncontrolled diabetes. *Malaysian Fam Physician Off J Acad Fam Physicians Malaysia* 2021;16:136–138. <https://doi.org/10.51866/cr1010>.
- [4] Korn BS, Burkat CN, Carter KD, Perry JD, Setabutr P, Steele EA, et al., editors. *Oculofacial Plastic and Orbital Surgery*. Basic Clin. Sci. Course, San Francisco: American Academy of Ophthalmology; 2021, p. 43–46.

- [5] Santos JC, Pinto S, Ferreira S, Maia C, Alves S, da Silva V. Pediatric preseptal and orbital cellulitis: A 10-year experience. *Int J Pediatr Otorhinolaryngol* 2019;120:82–88. <https://doi.org/10.1016/j.ijporl.2019.02.003>.
- [6] Lima AL, Illing T, Schliemann S, Elsner P. Cutaneous manifestations of diabetes mellitus: A review. *Am J Clin Dermatol* 2017;18:541–553. <https://doi.org/10.1007/s40257-017-0275-z>.
- [7] Bagheri A, Tavakoli M, Aletaha M, Salour H, Ghaderpanah M. Orbital and preseptal cellulitis: A 10-year survey of hospitalized patients in a tertiary eye hospital in Iran. *Int Ophthalmol* 2012;32:361–367. <https://doi.org/10.1007/s10792-012-9574-9>.
- [8] Lee S, Yen MT. Management of preseptal and orbital cellulitis. *Saudi J Ophthalmol Off J Saudi Ophthalmol Soc* 2011;25:21–29. <https://doi.org/10.1016/j.sjopt.2010.10.004>.
- [9] Lim LT, Miller D, Ah-Kee EY, Ferguson A. Preseptal cellulitis or orbital cellulitis? *West Indian Med J* 2015;65:304–307. <https://doi.org/10.7727/wimj.2015.179>.
- [10] Apakama AI, Uozie CC, Nnubia CA. Preseptal cellulitis: 13 years review in a tertiary hospital South-Eastern Nigeria. *Ophthalmol Res An Int J* 2020;13:10–17. <https://doi.org/10.9734/or/2020/v13i430173>.
- [11] Alqaseer B, Al Bin Ali GY. Orbital cellulitis following preseptal cellulitis. *Bahrain Med Bull* 2019;41:48–50.
- [12] Bulbul L, Akkus CH, Hatipoglu N, Palabiyik FB, Yazici ZM, Hatipoglu SS. Evaluation of pediatric preseptal cellulitis cases diagnosed with meningitis by magnetic resonance imaging. *Sisli Etfal Hastan Tip Bul* 2020;54:497–501. <https://doi.org/10.14744/SEMB.2019.54289>.
- [13] Hegde R, Sundar G. Orbital cellulitis: A review. *TNOA J Ophthalmic Sci Res* 2017;55:211–219. [https://doi.org/10.4103/tjosr.tjosr\\_9\\_18](https://doi.org/10.4103/tjosr.tjosr_9_18).
- [14] Mahalingam S, Luke L, Pundir J, Pundir V. The role of adjuvant systemic steroids in the management of periorbital cellulitis secondary to sinusitis: A systematic review and meta-analysis. *Eur Arch Oto-Rhino-Laryngology Off J Eur Fed Oto-Rhino-Laryngological Soc Affil with Ger Soc Oto-Rhino-Laryngology - Head Neck Surg* 2021;278:2193–2201. <https://doi.org/10.1007/s00405-020-06294-z>.