





CASE REPORT

Secondary Glaucoma After Blunt Ocular Trauma

Authors:

¹Ega Sekartika 
¹Priya Taufiq Arrachman 
¹Mutia Khanza 
²Dewi Rosarina* 

Affiliations:

¹Internship Doctors, Rumah Sakit Mata Undaan, Surabaya, Indonesia.

²Department of Glaucoma, Rumah Sakit Mata Undaan, Surabaya, Indonesia.

Corresponding author:

Dewi Rosarina
 rosarinadewi@yahoo.com

Dates:

Received: 17 April 2022
 Revised: 26 July 2022
 Accepted: 27 July 2022
 Published: 31 July 2022

DOI:

<https://doi.org/10.20473/vsehj.v1i3.2022.86-89>

Copyright:

© 2022 Author(s). Open access under Creative Commons Attribution-Share Alike 4.0 International Licence (CC-BY-SA).



Abstract

Introduction: Ocular trauma is an important cause of unilateral visual impairment and blindness. Among several agents of ocular trauma, blunt trauma is the most common and can lead to secondary glaucoma. Secondary glaucoma due to blunt ocular trauma can be unnoticed and undetected until the formation of glaucomatous optic neuropathy (GON) occurs. This case might not be neglected. Delay in treatment can lead to the progression of GON. **Case Presentation:** A 68-year-old woman presented to the outpatient clinic in Undaan Eye Hospital complaining of decreased vision and pain in the left eye after blunt trauma to the eye. Her left eye vision was limited to detecting hand motions (1/300) and the intraocular pressure (IOP) was 37.8 mmHg. On the slit lamp biomicroscopic examination, the left pupil was mid-dilated, lens opacification and phacodonesis were detected. The cup-to-disc ratio (CDR) of the left eye increased (0.8-0.9) through the funduscopy examination. Secondary glaucoma due to subluxated lens was diagnosed for the left eye. The patient was given topical and oral antiglaucoma medications and was evaluated after one week of drug use. Since the IOP remained elevated after medical therapy, left eye trabeculectomy was conducted. Bleb was formed postoperatively and the IOP was getting normal without oral glaucoma medications. **Conclusion:** Blunt ocular trauma can lead to secondary glaucoma. Thorough examinations and immediate treatments should be conducted to preserve patient's vision and prevent further optic nerve damage.

Keywords: secondary glaucoma; blunt ocular trauma; case report

Introduction

Ocular trauma is a significant cause of avoidable monocular vision loss.^{[1],[2]} Fifty-five million cases of ocular trauma are estimated to occur annually, and 34% of the cases lead to vision loss or blindness.^[3] The extensive socioeconomic burden may follow the incidence of ocular trauma; however, it is often neglected.^[4]

Several studies reported that blunt ocular trauma predominates the mechanism of ocular trauma.^{[2],[4],[5],[6]} It is responsible for approximately 40% of eye injuries.^[7] It may lead to vision-threatening problems, such as traumatic glaucoma. Traumatic glaucoma has become a concern as glaucoma alone is the most common cause of irreversible blindness worldwide.^{[7],[8]} Studies have mentioned^{[7],[9]} the prevalence of traumatic glaucoma after blunt ocular trauma to be around 11% in India and trauma was the most common cause of secondary glaucoma in China (28%).

The development of glaucoma induced by the elevation of intraocular pressure (IOP) as a result of the injury by blunt objects occurs through the damage of each part of the eye including cornea, sclera, anterior chamber, trabecular meshwork, lens, vitreous, choroid, and the orbit.^[10]

This study reports a case of secondary glaucoma due to a subluxated lens following blunt ocular trauma. In this case, the patient had only used a topical antiglaucoma agent for two months before she got referred. The delay in surgical and referral management of the patient seemed to take effect in the long-term increase of IOP that led to the continuous development of glaucoma. Due to this reason, filtering surgery was conducted before considering the extraction of the

subluxated lens. Immediate and precise management of this situation may prevent the development of vision-threatening glaucoma.

Case presentation

A 68-year-old woman presented to the outpatient clinic in Undaan Eye Hospital complaining of decreased vision and pain in the left eye for two months. She stated that a sapodilla had fallen right onto her left eye before she had those complaints. She had been to an ophthalmologist in her local area and was diagnosed as traumatic glaucoma with subluxated lens. She was treated with topical glaucoma medication, timolol 0.5% eye drop two times a day for her left eye. After being evaluated, her left eye's IOP remained elevated so that she was referred to Undaan Eye Hospital Surabaya.

She had a history of hypertension. She had amlodipine and candesartan to control her hypertension, 10 mg and 8 mg once a day, respectively. There were no complaints of swelling or laceration on the eyelid or the globe, no redness of the eye, and no blood inside the anterior chamber. There was no history of glaucoma in her family.

On the clinical examination, her blood pressure was high (170/90 mmHg) and the pain in her left eye was scaled three on the Wong Baker scale. Her right eye's visual acuity (VA) was 1/10 and the IOP was 11 mmHg. Clinical findings on the right eye's anterior segment evaluation were leucoma on the cornea and lens opacification (Figure 1). On the funduscopy examination, the cup-to-disc ratio (CDR) of the right eye was 0.3. Her left eye's VA was limited to detecting hand motions (1/300) and did not improve with refraction and the IOP was 37.8 mmHg. Clinical findings on the left eye's anterior segment evaluation were mid-dilated pupil, lens opacification, and phacodonesis (Figure 1). On the funduscopy examination, the CDR of the left eye was between 0.8-0.9. Gonioscopic evaluation was not done due to the mid-dilated pupil. Based on these findings, the patient was diagnosed with corneal leucoma and senile cataract of the right eye and secondary glaucoma due to subluxated lens of the left eye.

We treated her with topical and oral medications and planned to evaluate her after a week of drug use. She got timolol 0.5% eye drop two times a day for her left eye, acetazolamide 3 x 250 mg orally, and potassium

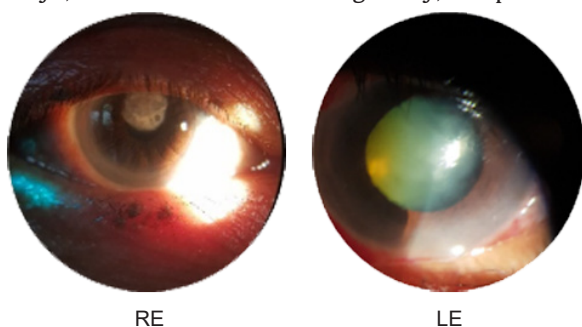


Figure 1. Preoperative anterior segment condition.

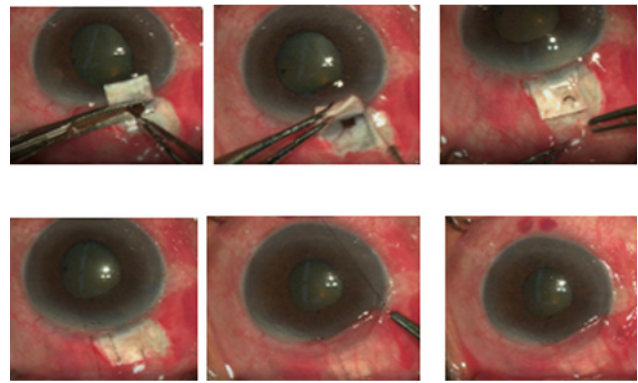


Figure 2. Clinical photographs of trabeculectomy.

chloride 1 x 600 mg orally. After a week, she came back to our hospital and got evaluated. The left eye's VA was 1/300 and the IOP was still elevated (43.4 mmHg). Other examinations from the anterior chamber and the posterior segment remained the same. Therefore, trabeculectomy for her left eye was planned. She was still prescribed with topical and oral glaucoma medications before the surgery.

The surgery was done two weeks later. Before the surgery, her left eye's IOP was 27.2 mmHg. Some parts of the trabeculectomy procedure done for the patient (Figure 2). The surgery was performed by folding back the conjunctiva and creating a flap part-way through the sclera. A hole is made through the limbus and a small part of the iris was removed. Antimetabolite mitomycin C was applied (not shown in the figure). Then, the flap in the sclera and the conjunctiva was sewn back in place.

The surgery went well without any obstacles. One day after the surgery, the IOP was 19.6 mmHg. The left conjunctiva was quite hyperemic and the formation of bleb was detected (Figure 3). She was given topical antibiotics four times a day for her left eye.

The following postoperative evaluation was done after seven and twenty-three days after surgery. Her IOP decreased from 16 to 14, respectively. The bleb was still formed (Figure 3). She was not prescribed with any topical or oral glaucoma medications after surgery. She was planned to undergo intracapsular cataract extraction (ICCE) for her left subluxated lens afterwards.

Discussion and conclusions

The case described the development of secondary glaucoma due to a subluxated lens following blunt ocular trauma. Some traumatic glaucoma cases might be left unnoticed and undetected until the development of glaucomatous optic neuropathy occurred.^[7] Although this case was not completely neglected, as the patient got treated after the injury took place, adequate treatments seemed to be lacking.

The patient was administered antiglaucoma medication using a topical beta-blocker after the injury.

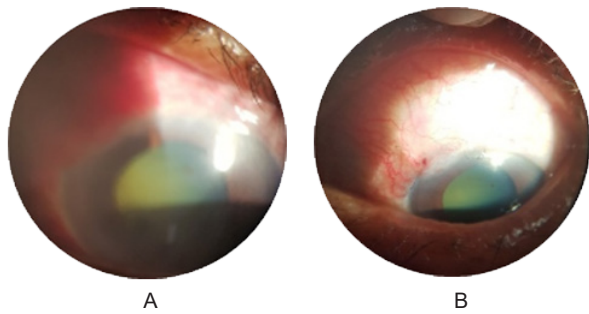


Figure 3. (A) Postoperative condition of patient's left eye day one; and (B) day seven.

Considering the remaining rise of the IOP, the patient got referred two months later. During the first examination in the referral hospital, the IOP was high (37.8 mmHg), the lens was subluxated as phacodonesis was detected, and the CDR was 0.8-0.9. After a week of antiglaucoma medications using a topical beta blocker and an oral carbonic anhydrase inhibitor, the patient got evaluated. The IOP increased (43.4 mmHg) and other examinations remained the same. Due to the long-term increase of IOP, surgical intervention in the form of trabeculectomy was conducted. The IOP lowered, from 19.6 mmHg to 16 mmHg and 14 mmHg in the first, seventh, and twenty-third day post-surgical evaluations.

Direct trauma from blunt objects can induce the increase of IOP which then lead to traumatic glaucoma.^[10] Injury affecting the lens can generate lens subluxation or dislocation. Lens dislocation alone is caused by multifactorial factors, including some kind of congenital abnormalities, such as Marfan syndrome, Weill-Marchesani syndrome, and homocystinuria, zonules-related eye disease, such as high myopia and pseudoexfoliation syndrome, iatrogenic condition, along with blunt trauma.^{[11],[12]} A study reported that the major cause of lens dislocation was trauma.^[12] Blunt trauma causes compression of the eye antero-posteriorly which then cause an expansion of the eye in several directions, laterally, superiorly, and inferiorly. It also leads to stretch and tear of the lens zonules which then results to partial or complete lens dislocation.^{[10],[11],[13]} Elevated IOP following lens subluxation may result from pupillary block.^{[10],[14]}

The symptoms of secondary glaucoma following lens subluxation are blurred vision and pain in the eye^[12], which are in accordance with our patient. Slit lamp biomicroscopic examination may reveal the mobility of the lens (phacodonesis)^{[10],[12]}, which is also detected in our patient's eye. The increase of CDR also indicated the formation of glaucomatous optic neuropathy.^[15]

Treatment of glaucoma is still focussing on lowering the IOP thus far. Initial antiglaucoma medications are to be prescribed for patients with glaucoma. Failure to control IOP after maximum tolerated medications lead to further surgical intervention, such as trabeculectomy.^{[14],[15],[16]}

Trabeculectomy is an incisional procedure to create a bypass for the aqueous humor outflow. It is created by making a passage/fistula between the anterior chamber and the subconjunctival space.^[15] Antimetabolite is used to prevent scar formation to keep the patency of the filtering bleb, hence reducing trabeculectomy failure.^[16] In this case, mitomycin C (MMC) was applied.

Lens extraction is a primary consideration in the case of lens subluxation following blunt ocular trauma. However, in this case, filtering surgery was elected before performing lens extraction due to the long-term increase of IOP as a rise in IOP is associated with functional loss in the visual field and reduction in retinal nerve fiber layer thickness.^[17]

Our patient was successfully treated with trabeculectomy after previous failure to control the IOP using anti-glaucoma medications. It is in line with a study which carried out surgical intervention after failure to control IOP using antiglaucoma medications for two weeks.^{[6],[18]} Avoiding surgical intervention in an uncontrolled IOP condition may lead to permanent vision loss and total blindness.^[6] Intracapsular cataract extraction (ICCE) was planned afterwards to remove the subluxated lens.

Blunt ocular trauma can cause severe damage of vision as it can lead to secondary glaucoma. Thorough examinations and treatments need to be taken appropriately. Surgical intervention should be carried out immediately if anti-glaucoma medications have reached the maximum tolerated dosage with remaining uncontrolled IOP. By lowering the IOP, patient's vision is expected to be preserved and further optic nerve damage can be prevented.

References

- [1] Feng K. Epidemiology of Ocular Trauma. In: Yan H, editor. *Anat. Exam. Ocul. Trauma*. 1st ed., Singapore: Springer; 2019, p. 105–122. https://doi.org/10.1007/978-981-13-0068-4_6.
- [2] Zungu T, Mdala S, Manda C, Twabi HS, Kayange P. Characteristics and visual outcome of ocular trauma patients at Queen Elizabeth Central Hospital in Malawi. *PLoS One* 2021;16:e0246155. <https://doi.org/10.1371/journal.pone.0246155>.
- [3] Bian X, Xu S, Song Y, Wang Y, Zhao B, Zhong Y, et al. Global, national and regional prevalence, and associated factors of ocular trauma: A protocol for systematic review and meta-analysis. *Medicine (Baltimore)* 2020;99:e21870. <https://doi.org/10.1097/MD.00000000000021870>.
- [4] Ababneh LT, Mohidat H, Abdelnabi H, Kana'an MF, Tashtush NA, El-Mulki OS, et al. Hospital-based ocular trauma: Factors, treatment, and impact outcome. *Clin Ophthalmol* 2019;13:2119–26. <https://doi.org/10.2147/OPTH.S223379>.
- [5] Maurya RP, Srivastav T, Singh VP, Mishra CP, Al-Mujaini A. The epidemiology of ocular trauma in Northern India: A

- teaching hospital study. *Oman J Ophthalmol* 2019;12:78–83. https://doi.org/10.4103/ojo.OJO_149_2018.
- [6] Shah C, Sen P, Mohan A, Peeush P, Jain E, Prasad K, et al. Outcomes and risk factors for failure of trabeculectomy with mitomycin C in children with traumatic glaucoma - A retrospective study. *Indian J Ophthalmol* 2022;70:590–596. https://doi.org/10.4103/ijo.IJO_1997_21.
- [7] Maiya A. Traumatic glaucoma in 100 consecutive cases of ocular blunt trauma in a tertiary care center. *Kerala J Ophthalmol* 2020;32:154–158.
- [8] Raj S, Savla LP, Thattaruthody F, Seth NG, Kaushik S, Pandav SS. Predictors of visual impairment in primary and secondary glaucoma in a tertiary institute in North India. *Eur J Ophthalmol* 2020;30:175–180. <https://doi.org/10.1177/1120672118823135>.
- [9] Gong H, Ren J, Zheng B, Huang X, Liao Y, Zhou Y, et al. The profile of secondary glaucoma in China: A study of over 10,000 Patients. *J Glaucoma* 2021;30:895–901. <https://doi.org/10.1097/IJG.0000000000001924>.
- [10] Rameghinejad R, Lin MM, Lee D, Katz LJ, Myers JS. Pathophysiology and management of glaucoma and ocular hypertension related to trauma. *Surv Ophthalmol* 2020;65:530–547. <https://doi.org/10.1016/j.survophthal.2020.02.003>.
- [11] Arthur J, Schubert B, Topp SS. Traumatic ocular lens dislocation. *African J Emerg Med* 2019;9:106–107. <https://doi.org/10.1016/j.afjem.2019.01.001>.
- [12] Jing Q, Chen T, Chen Z, Lan L, Zhao C, Jiang Y. Ocular manifestations of acute secondary angle closure associated with lens subluxation. *Front Med* 2021;8:738745. <https://doi.org/10.3389/fmed.2021.738745>.
- [13] Olm LK, Langer FW, Haygert CJ. Crystalline lens subluxation following blunt head trauma. *Acta Med Port* 2020;33:692. <https://doi.org/10.20344/amp.12418>.
- [14] Kim WI. Traumatic Glaucoma BT - Ophthalmology in Military and Civilian Casualty Care. In: Calvano CJ, Enzenauer RW, Johnson AJ, editors. Cham: Springer International Publishing; 2019, p. 75–87. https://doi.org/10.1007/978-3-030-14437-1_8.
- [15] Girkin CA, Bhorade AM, Crowston JG, Giacony JA, Medeiros FA, Sit AJ, et al., editors. Glaucoma: 2020–2021 Basic and Clinical Science Course, Section 10. San Francisco: American Academy of Ophthalmology; 2020.
- [16] Halili A, Kessel L, Subhi Y, Bach-Holm D. Needling after trabeculectomy - Does augmentation by anti-metabolites provide better outcomes and is Mitomycin C better than 5-Fluorouracil? A systematic review with network meta-analyses. *Acta Ophthalmol* 2020;98:643–653. <https://doi.org/10.1111/aos.14452>.
- [17] Oliveira-Ferreira C, Leuzinger-Dias M, Tavares-Ferreira J, Faria O, Falcão-Reis F. The Relationship between Intraocular pressure and optic nerve structural and functional damage in patients with optic nerve head drusen. *Neuroophthalmology* 2020;44:290–293. <https://doi.org/10.1080/01658107.2019.1691242>.
- [18] Senthil S, Dangeti D, Battula M, Rao HL, Garudadri C. Trabeculectomy with mitomycin-c in post-traumatic angle recession glaucoma in phakic eyes with no prior intraocular intervention. *Semin Ophthalmol* 2022;37:171–176. <https://doi.org/10.1080/08820538.2021.1945116>.