






CASE REPORT

Successful Management of Malignant Glaucoma with Pars Plana Vitrectomy and Glaucoma Drainage Device Implant

Authors:Rosalia Adriani Malika* Noviana K. Vivin Dewi Rosarina **Affiliations:**Rumah Sakit Mata Undaan,
Surabaya, East Java,
Indonesia.**Corresponding author:**Rosalia Adriani Malika
rosaliaadriani@gmail.com**Dates:**

Received: 23 January 2023

Revised: 15 May 2023

Accepted: 30 May 2023

Published: 25 July 2023

DOI:<https://doi.org/10.20473/vsehj.v2i3.2023.70-73>**Copyright:**

© 2023 Author(s). Open access under Creative Commons Attribution-Share Alike 4.0 International Licence (CC-BY-SA).

**Abstract**

Introduction: Malignant glaucoma is a rare condition with challenging management. It is diagnosed by central and peripheral shallowing or flattening of the anterior chamber and increased intraocular pressure (IOP) without posterior segment abnormality (suprachoroidal effusion or hemorrhage of patent iridotomy). It can be managed by pars plana vitrectomy (PPV). **Case Presentation:** A 59-year-old man presented to the emergency unit in Undaan Eye Hospital, Surabaya complaining of pain and blurry vision in his left eye after being hit by a rope. Secondary glaucoma with posterior lens luxation was diagnosed in the left eye. The patient was given topical and oral glaucoma medications. Vitrectomy with endo laser and endo fragmentation was performed three months later with normal IOP. A retinal break was detected at five o'clock, and sulphur hexafluoride (SF6) was given during vitrectomy. Malignant glaucoma was diagnosed by flattening the anterior chamber after vitrectomy with left eye IOP of 31 mmHg. The left eye IOP remained elevated in the following months, and the pain persisted. However, topical and oral anti-glaucoma medications, topical cycloplegics, and steroids were already given. The cornea became hazy due to uncontrolled IOP. A left eye PPV with a glaucoma drainage devices (GDD) implant was conducted. Nevertheless, his left eye visual acuity did not improve (1/300). Besides, his left eye IOP was normal without topical and oral glaucoma medications. **Conclusions:** PPV offers reliable and prompt treatment for malignant glaucoma with a low complication rate. The patient's vision can be preserved by lowering the IOP, preventing further optic nerve damage.

Keywords: malignant glaucoma; pars plana vitrectomy (PPV); glaucoma drainage device

Introduction

Malignant glaucoma is an uncommon disease with challenging management.^[1] Secondary glaucoma with significant complications can appear after intraocular surgery.^{[1],[2]} The characteristic features are showing or flattening the anterior chamber and increasing intraocular pressure (IOP) without posterior segment abnormality (suprachoroidal effusion or hemorrhage of a patent iridotomy).^{[1],[2],[3]} It occurs in 0.6% to 4% of eyes with primary angle closure (PAC), commonly after trabeculectomy or cataract surgery.^[3] Another study reported^[4] that malignant glaucoma incidence has been described as approximately between 1% and 3% postoperatively. It may occur after laser surgery or intraocular surgery, including cataract surgery (with or without implant), scleral buckle, vitrectomy, laser capsulotomy, laser cyclophotocoagulation, laser iridotomy, scleral flap suture lysis, and with the use of miotic agents.^[5] On the other hand, malignant glaucoma can occur spontaneously in unoperated eyes.^[5] Malignant glaucoma is known as a condition with poor visual outcomes, regardless of appropriate treatment.^[6]

Furthermore, aqueous misdirection syndrome, ciliary block glaucoma, ciliolenticular glaucoma, and ciliovitreal block glaucoma are the pathophysiology of it.^[7] There are several management options for malignant glaucoma, such as medical, laser, and surgical. The management of aqueous misdirection is mainly medical, with topical cycloplegics to push the iris-lens diaphragm posteriorly, topical and oral anti-glaucoma medications, and topical and oral steroids.^[8]

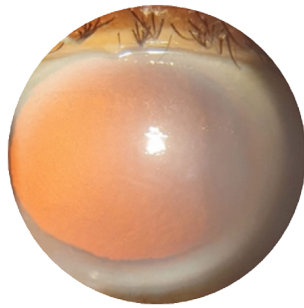

Figure 1. Preoperative anterior segment condition.

Additionally, the YAG laser has been used to connect the anterior vitreous and anterior chamber in the pseudophakic and aphakic malignant glaucoma. Surgery must be advised if the patient does not respond to medical or laser procedures. Vitrectomy is the most effective surgical procedure.^{[9],[10]} Zonulo hyaloid-vitrectomy (ZHV) has been reported as an alternative surgical procedure for pseudophakic malignant glaucoma.^[11]

Glaucoma drainage devices (GDDs) are progressively used to treat glaucoma after ineffective trabeculectomy or laser therapy. GDDs can be inserted into the anterior chamber, sulcus, or pars plana regulated by ocular pathology. The placement of the tube in the anterior chamber should not be recommended in some conditions, such as corneal diseases, iridocorneal angle abnormalities, peripheral anterior synechiae, or other pathologies.^[12]

Studies concerning managing malignant glaucoma or any case reports of malignant glaucoma with pars plana vitrectomy (PPV) in Indonesian patients are still negligible. This study was considered to report successful management of malignant glaucoma with PPV and GDDs implant. This case report can give another approach to treating malignant glaucoma with PPV and GDDs implant, especially in Indonesia.

Case presentation

A 59-year-old male presented to the emergency unit in Undaan Eye Hospital, Surabaya complaining of pain and blurry vision in the left eye (LE). He stated that his LE had been hit by a rope three hours before. His LE visual acuity (VA) was 1/300, and the IOP was 37.2 mmHg. He was diagnosed with secondary glaucoma with posterior lens luxation. He was treated with topical and oral glaucoma medications. He was given timolol 0.5% eye drop, acetazolamide 3 x 250 mg, and potassium chloride 1 x 600 mg. After being evaluated, his LE has IOP still elevated, and he was hospitalized for four days.

After a week, his LE VA was 1/60, improved with pinhole to 4/10, and the IOP was already 19 mmHg. Clinical findings on the LE's anterior segment evaluation were aphakic, and there was vitreous in the anterior chamber. There was a lens in the vitreous cavity on the posterior segment evaluation. Vitrectomy followed by endo laser, and endo fragmentation was performed three

months later. At the time of surgery, a retinal break was detected at five o'clock. Therefore, Sulfur Hexafluoride (SF6) was given for intraocular tamponade during vitrectomy in this patient. First day postoperatively, his LE VA was 1/300, and the IOP was 35 mmHg.

After two months, he quietly complained of pain in the LE, followed by a headache. His LE VA was 1/300, and the IOP was 31 mmHg. On the anterior segment evaluation, the cornea was oedematous and hazy, and the anterior chamber was flat (Figure 1). He was still prescribed topical and oral glaucoma medications, cycloplegics, and steroids.

A few months later, after using topical and oral glaucoma medications, he complained of pain, which became persistent. His LE VA was limited to detecting hand motions (1/300) due to interminable IOP elevation (59 mmHg) and a decrease in LE corneal density (1183 cell/mm²). In addition, PPV with a GDDs implant for his LE was performed after the unresponsiveness with topical and oral glaucoma medications. Topical antibiotics were given six times a day for his LE after surgery.

The following postoperative evaluation was done after one week, two weeks, and a month after surgery. The patient LE VA did not improve (1/300). The IOP came down to 8 mmHg (one week), 11 mmHg (two weeks), and 8 mmHg (one month) without any glaucoma medications, and he did not complain about pain nowadays. Clinical findings on the LE's anterior segment evaluation were oedematous and hazy cornea (Figure 2). Fundus examination of the LE showed not well demarcated optic nerve head, cup disc ratio challenging to be evaluated due to opacity of the anterior segment, and fundus reflex was positive.

Discussion and conclusions

Malignant glaucoma is a rare disease with severe complications. The pathogenesis of malignant glaucoma is still unclear, including misdirection of aqueous humor behind or within the vitreous, direct lens block as a consequence of fluid accumulation in the posterior chamber, the difference between anterior and posterior chamber due to rotation of ciliary processes, or anterior hyaloid face obstruction.^[1] The treatment target is to reduce the ciliolenticular block and replace the misdirection of aqueous humor with the normal aqueous flow.^{[13],[14]} Medication or laser therapy has a low immediate success rate and a high risk of recurrence limit. Surgical procedures (posterior sclerotomy, vitreous puncture, and aspiration via the pars plana and PPV) can reduce the posterior vitreous pressure and restore anterior chamber depth. According to the most recent study^[1] of malignant glaucoma, PPV reported a 100% success rate and 5.2% recurrence rate with PPV.

This case proved the highly impactful and reliable

- [11] Tosi R, Kilian R, Rizzo C, Pagnacco C, Marchini G. A case of bilateral pseudophakic malignant glaucoma treated with a new variant of irido-zonulo-hyaloid-vitreotomy. *Am J Ophthalmol Case Rep* 2022;28:101719. <https://doi.org/10.1016/j.ajoc.2022.101719>.
- [12] Chang EK, Gupta S, Chachanidze M, Miller JB, Chang TC, Solá-Del Valle DA. Combined pars plana glaucoma drainage device placement and vitrectomy using a vitrectomy sclerotomy site for tube placement: A case series. *BMC Ophthalmol* 2021;21:106. <https://doi.org/10.1186/s12886-021-01872-z>.
- [13] Balekudaru S, Choudhari NS, Rewri P, George R, Bhende PS, Bhende M, et al. Surgical management of malignant glaucoma: A retrospective analysis of fifty eight eyes. *Eye* 2017;31:947–955. <https://doi.org/10.1038/eye.2017.32>.
- [14] Tang J, Du E, Li X. Combined surgical techniques for the management of malignant glaucoma. *J Ophthalmol* 2018;2018:1–7. <https://doi.org/10.1155/2018/9189585>.
- [15] Thompson AC, Vu DM, Postel EA, Challa P. Factors impacting outcomes and the time to recovery from malignant glaucoma. *Am J Ophthalmol* 2020;209:141–150. <https://doi.org/10.1016/j.ajo.2019.07.023>.