



Volume 5 Number 1, January 2025

Fungal Meningoencephalitis Masquerading as Metabolic Encephalopathy: A Case Report in a 65-Year-Old Geriatric Patient

Nita Kurniawati¹, Ferdinand Erwin² ¹ Department of Neurology, Faculty of Medicine, Universitas Katolik Widya Mandala Surabaya; Gotong Royong Hospital, Surabaya, Indonesia² Faculty of Medicine, Universitas Katolik Widya Mandala Surabaya; Gotong Royong Hospital, Surabaya, Indonesia

Article info

Article History:

Received Mar 8, 2024

Revised Aug 25, 2024

Accepted Sept 10, 2024

Published Jan 29, 2025

Keywords:

Candidiasis

Elderly

Infectious disease

Meningoencephalitis

ABSTRACT

Introduction: Infectious pathogens or autoimmune disorders can cause meningoencephalitis. Symptoms include headache, fever, altered mental status, seizure, or neurological deficits. Symptoms frequently manifest atypically in the elderly, which can result in delayed treatment. This case emphasizes how important it is to consider meningoencephalitis in elderly patients with altered consciousness, even without typical signs of it.

Case: A 65-year-old female with a history of recurrent hyponatremia and hypokalemia arrived at the emergency room with sudden loss of consciousness, vomiting, and behavioral changes that persisted for a week. The neurological examination and brain CT scan revealed no abnormalities. Severe electrolyte imbalances prompted the initial diagnosis of metabolic encephalopathy. Following progressive electrolyte correction, the patient's mental condition improved. On the second day, she had generalized seizures and developed right-sided hemiparesis. An MRI of the head with contrast showed thicker dura mater and leptomeningeal enhancement in both hemispheres, indicating meningoencephalitis. Ceftriaxone and dexamethasone were administered intravenously, along with levetiracetam, to treat seizures. The next day, cerebrospinal fluid analysis showed *Candida* spores, but cultures were negative. Intravenous fluconazole was then added to the therapy. Throughout her two-week stay, the patient's neurological condition improved consistently.

Conclusion: Fungal causes should be considered in cases with unclear meningoencephalitis in the elderly, even if fever or meningeal signs are not present. Although CSF culture continues to be the gold standard for diagnosing fungal CNS infection, negative results should not delay the start of antifungal therapy. Early initiation of targeted antimicrobial therapy is crucial for successful results in these cases.

Corresponding Author

Ferdinand Erwin

Faculty of Medicine, Universitas Katolik Widya Mandala Surabaya; Gotong Royong Hospital, Surabaya Indonesia

email: ferdinand@ukwms.ac.id

Available at <https://e-journal.unair.ac.id/index.php/aksona>

This work is licensed under a Creative Commons Attribution-ShareAlike 4.0 International License

INTRODUCTION

Meningoencephalitis is a serious inflammatory condition that affects the brain and the membranes surrounding it, known as meninges. Meningoencephalitis has several infectious and non-infectious causes.^{1,2} Viral, bacterial, fungal, and parasitic infections are among the infectious causes of meningoencephalitis. The most prevalent causes are viral infections, such as herpes simplex virus, varicella-zoster virus, and enterovirus. *Streptococcus pneumoniae*, *Neisseria meningitidis*, and *Listeria monocytogenes* are three possible bacterial causes. Fungal and parasitic infections can cause meningoencephalitis, despite their rarity. Non-infectious causes of meningoencephalitis include autoimmune disorders, like autoimmune encephalitis.^{1,3,4}

The 2019 Global Burden of Disease (GBD) Study showed that the global incidence of meningitis has decreased from 3.29 million (2.7–4.0) cases in 1990 to 2.51 million (2.11–2.99) cases in 2019. The report revealed that viral meningitis caused almost one-third of meningitis diagnoses globally.⁵ In Indonesia, there are 21,400 cases per 100,000 people (range: 15,100 to 29,800). Although meningitis-related fatality rates have decreased by 45% between 1990 and 2019, the disease's overall impact remains significant.⁵

The prevalence of central nervous system (CNS) fungal infections has shown an increasing tendency. These infections may manifest clinically as meningitis, meningoencephalitis, abscesses, or vascular disease. Meningoencephalitis appears to be the most common clinical manifestation of candidiasis in the CNS. Other symptoms include endophthalmitis, brain abscesses, vasculitis, intraventricular infection, hydrocephalus, calcifications, and cranial neuropathies. Stroke lesions may also appear in extremely rare cases.^{6,7,8}

Several *Candida* species, such as *C. albicans*, *C. tropicalis*, *C. lusitaniae*, and *C. parapsilosis*, are associated with human illness.⁹ Diverse patient demographics exhibit specific vulnerabilities to different *Candida* infections impacting the central nervous system. The species *C. albicans* is frequently isolated from both immunocompromised and immunocompetent patients. However, its frequency has been decreasing over the last decade.^{6,10} *Candida* meningitis usually occurs in cases of disseminated candidiasis, especially among immunocompromised people, those with underlying immune deficiencies, or patients who have undergone neurosurgical procedures.^{6,9}

Previous studies have indicated that elderly people with bacterial meningitis are a unique patient subgroup with unusual symptoms, unusual bacterial pathogens, and a high rate of adverse outcomes.¹¹ This unusual presentation in elderly patients can lead to

misdiagnosis and treatment. Approximately 6% of those with disseminated candidiasis are estimated to have undetected neuroinfections.⁶ Also, past studies have shown that *Candida* infections of the CNS can present in altered mental status without meningeal symptoms, potentially leading to delayed diagnosis and treatment.¹² Another diagnostic challenge is that CSF cultures have poor diagnostic accuracy in patients with *Candida* meningitis.^{13,14} In elderly patients with altered consciousness, the causes and differential diagnoses are wide-ranging and often atypical. In this case, we provide an atypical presentation of meningoencephalitis to raise awareness among healthcare professionals and encourage prompt and appropriate treatment, which is crucial for improving patient outcomes.

CASE

A 65-year-old female patient with a history of recurrent hyponatremia and hypokalemia was admitted to the emergency room due to sudden loss of consciousness, repeated vomiting, and behavioral changes characterized by increasing restlessness. For a week, the patient's family noticed behavioral changes, such as increased agitation and restlessness. There was no report of fever, headaches, or neck stiffness during this period.

The patient's vitals were normal. In contrast, a Glasgow Coma Scale (GCS) score of 10 (E3V2M5) indicated decreased responsiveness in neurological examination. Although the individual's mental health changed, there were no signs of specific neurological disorders, nor were there any signs of meningeal inflammation, such as neck stiffness or any other meningeal sign. Laboratory tests revealed a significant decrease in sodium (112 mEq/L) and potassium (2.56 mEq/L) levels, leading to the first diagnosis of metabolic encephalopathy.

A non-contrast computed tomography (CT) scan of the brain was immediately performed and showed no abnormalities or cerebral edema. Hospitalization gradually corrects electrolyte imbalances. The patient's mental status and electrolyte levels improved over the first 48 hours. On the second day of hospitalization, something unexpected happened. Patients experience general seizures followed by a period of altered mental status. The test revealed right-sided neurological deficits, including hemiparesis. A subsequent non-contrast brain CT scan revealed no current intracranial abnormalities or indications of hemorrhage or infarction. The patient was then given two doses of levetiracetam, 500 mg each.

Further examination is necessary due to the development of neurological symptoms and an unclear metabolic cause. A contrast-enhanced magnetic

resonance imaging (MRI) scan of the brain revealed thickening dura mater and leptomeningeal enhancement in both hemispheres (Figure 1). These results support the new diagnosis of meningoencephalitis. The patient was promptly put on comprehensive intravenous ceftriaxone (1 gram twice daily), intravenous dexamethasone, and levetiracetam to treat the seizures.

The next day, a lumbar puncture was conducted to confirm the infection's cause. The cerebrospinal fluid (CSF) surprisingly showed no abnormalities in terms of cell count, glucose, or protein levels. In contrast, potassium hydroxide (KOH) staining in CSF revealed the presence of *Candida* spores. Despite the microscopic examinations, bacterial and fungal cultures in the CSF showed no indication of growth. Tests using polymerase chain reaction (PCR) on CSF did not show any signs of common viruses like CMV, H5N1, and H1N1.

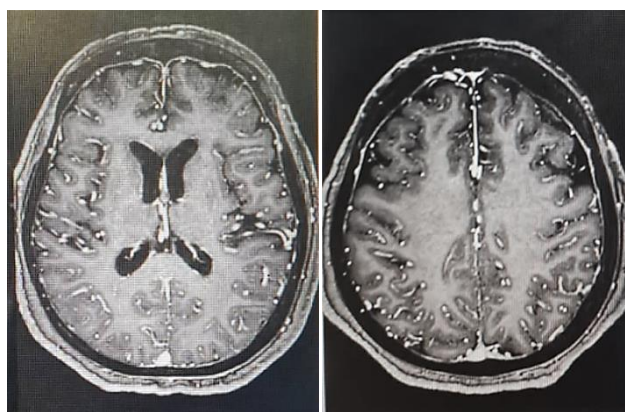


Figure 1. Brain MRI reveals diffuse dural thickening with abnormal leptomeningeal enhancement in both the left and right cerebral hemispheres.

Based on the CSF examination results, intravenous fluconazole 800 mg per day was added as an antimicrobial treatment. Throughout her two-week hospitalization, the patient's neurological condition improved consistently, resulting in an improved mental status, fewer seizures, and the resolution of neurological deficits. MRI showed that the leptomeningeal enhancement had decreased. The patient returned with a comprehensive outpatient follow-up plan to monitor neurologic recovery and treat the effects of these atypical meningoencephalitis symptoms.

DISCUSSION

In this case report, we emphasized the importance of accurately diagnosing the fungal cause of meningitis in older patients, as atypical symptoms can potentially delay diagnosis and treatment. Of the

different types of fungal infections that can happen in the central nervous system (CNS), there are two main groups: those that affect a healthy host, such as *Cryptococcus*, *Coccidioides*, *Histoplasma*, *Blastomyces*, and *Sporothrix* species, and those that affect immunocompromised individuals, such as *Candida*, *Aspergillus*, *Zygomycetes*, and *Trichosporon* species.¹⁵ *Candida* species are commonly found in the normal human flora and rarely cause central nervous system (CNS) diseases unless host defenses are compromised. Several factors lead to the spread of *Candida* into the bloodstream and, potentially, the central nervous system. These factors include prematurity, broad-spectrum antibiotic use, hyperalimentation, malignancy, the presence of indwelling catheters, corticosteroid treatment, neutropenia, surgery, diabetes mellitus, thermal injuries, and intravenous drug misuse.^{2,15} *C. albicans* is the predominant species isolated in cases of *Candida* meningitis, but others, such as *C. tropicalis*, *C. glabrata*, *C. lusitaniae*, and *C. parapsilosis*, have also been reported.^{16,17}

Fungal meningitis has less predictable clinical manifestations than bacterial meningitis. Patients frequently exhibit symptoms of chronic meningitis syndrome, which is defined as meningitis that persists or worsens for at least four weeks. Patients typically exhibit nonspecific clinical observations, such as general weakness or a failure to thrive.^{2,17,18} Fever, headache, lethargy, confusion, nausea, vomiting, stiff neck, or neurological deficits are some of the most common symptoms, although only a subset of these will be present at first. In some cases, patients may have symptoms resembling subacute dementia. Raised intracranial pressure and related symptoms can manifest acutely or gradually as the disease advances.² Fungal meningitis is always a main concern in the differential diagnosis of chronic meningitis syndrome patients. However, it is important to examine various other infectious and noninfectious conditions, including tuberculous or carcinomatous meningitis.^{16,19}

Meningoencephalitis in the elderly can provide particular challenges and complexities. As people age, their immune systems may weaken, making them more susceptible to infections. Furthermore, symptoms of meningoencephalitis in the elderly may be atypical or misdiagnosed as other age-related illnesses, thus delaying diagnosis and treatment. These factors, together with the possibility of more severe outcomes in the elderly population, make meningoencephalitis a major concern in this age range.²⁰ According to previous reports, the clinical presentation of meningoencephalitis in elderly people frequently involves common symptoms such as headaches, neck stiffness, vomiting, and fever. Confusion, impaired mental status, and seizures are among the possible further symptoms.^{20,21}

Researchers have extensively investigated cerebrospinal fluid findings in fungal meningitis. A mononuclear pleocytosis is usually observed, with cell counts between 20 and 500 cells/mm³. Although it varies, the percentage of polymorphonuclear (PMN) leukocytes is often far below 50%. Sometimes, PMN leukocytes are the most common type. Fungi such as *aspergillus*, *Scedosporium*, *Blastomyces*, or the agents of mucormycosis cause meningitis more frequently. Cerebrospinal fluid protein concentrations typically show elevation in cases of fungal meningitis. Glucose concentrations in CSF during fungal meningitis tend to be decreased, although they may occasionally appear normal.^{2,17,19} Although culture examination continues to be the most reliable method for diagnosing fungal meningitis, some cases show negative results in CSF culture tests. According to Voice *et al.*, only 44% of candidiasis meningitis patients showed *Candida* growth during their initial CSF culture examination. Reevaluation of previously negative samples using modified examination techniques resulted in a total of 88% of samples having positive *Candida* cultures.¹⁴

No randomized controlled trials have evaluated the appropriate treatment approach for *Candida* meningitis due to its low morbidity rates. The Infectious Diseases Society of America last updated its clinical practice guidelines for candidiasis management in 2016. For people with *Candida* meningitis, they said that liposomal amphotericin B (AmB) at a dose of 5 mg/kg daily, with or without oral flucytosine at 25 mg/kg four times a day, should usually be the first treatment. However, the optimal duration of this initial treatment has not been thoroughly studied.^{2,12} Fluconazole has shown efficacy as a step-down or alternative therapy, with a common dose of 400–800 mg daily (equal to 6–12 mg/kg), due to its ability to achieve excellent levels in both CSF and brain tissue. The treatment continued until all clinical signs, symptoms, CSF abnormalities, and radiological findings had resolved.¹²

CONCLUSION

Meningoencephalitis presents particular challenges in elderly patients due to the potential of atypical symptoms and the risk of delayed diagnosis. As a result, clinicians must uphold a high level of suspicion for meningoencephalitis in elderly patients, especially if they have diminished consciousness. Prompt recognition and treatment are crucial to avoiding serious results. Even though CSF culture remains the gold standard for diagnosing fungal CNS infections, the initiation of antifungal therapy should not be delayed due to negative CSF culture results. Overall, early recognition, appropriate diagnosis, and prompt treatment are critical in managing fungal

meningitis, particularly *Candida* meningitis, in order to enhance patient outcomes and reduce the risk of complications.

Acknowledgement

The authors would like to express gratitude and appreciation to Gotong Royong Hospital, Surabaya, for the support and to the patient for her willingness to be included in this case report.

Conflict of Interest

The authors have no conflicts of interest to disclose for this report.

Funding

No funding was received for this case report.

Author Contributions

Author: examined the patient, contributed to data collection and manuscript description, and wrote the manuscript.

Co-author: examined the patient together with the author, contributed to data collection, and reviewed the manuscript.

REFERENCES

- Griffiths MJ, McGill F, Solomon T. Management of acute meningitis. *Clin Med (Northfield Il)*. 2018; 18(2):164–9. doi: [10.7861/clinmedicine.18-2-164](https://doi.org/10.7861/clinmedicine.18-2-164)
- Scheld WM, Whitley RJ, Marra CM. Infections of the central nervous system. 4th ed. Philadelphia: Lippincott Williams & Wilkins; 2014. 687 p. [Book]
- Hersi K, Gonzalez F, Kondamudi N. Meningitis. Treasure Island (FL): StatPearls Publishing. 2023. [Book]
- Ghia CJ, Rambhad GS. A systematic literature review on the prevalence and etiology of meningitis among critically ill and hospitalized patients in India. *Ther Adv Infect Dis*. 2021; 8:204993612110464. doi: [10.1177/20499361211046453](https://doi.org/10.1177/20499361211046453)
- Wunrow HY, Bender RG, Vongpradith A, Sirota SB, Swetschinski LR, Novotney A, et al. Global, regional, and national burden of meningitis and its aetiologies, 1990–2019: a systematic analysis for the Global Burden of Disease Study 2019. *Lancet Neurol*. 2023; 22(8):685–711. doi: [10.1016/S1474-4422\(23\)00195-3](https://doi.org/10.1016/S1474-4422(23)00195-3)
- Góralaska K, Blaszkowska J, Dzikowiec M. Neuroinfections caused by fungi. *Infection*. 2018; 46(4):443–59. doi: [10.1007/s15010-018-1152-2](https://doi.org/10.1007/s15010-018-1152-2)
- Panackal AA, Williamson PR. Fungal Infections of the Central Nervous System. *Contin Lifelong Learn Neurol*. 2015; 21:1662–78. doi: [10.1212/CON.0000000000000241](https://doi.org/10.1212/CON.0000000000000241)
- Gavito-Higuera J, Mullins CB, Ramos-Duran L, Olivas Chacon CI, Hakim N, Palacios E. Fungal Infections of the Central Nervous System: A Pictorial Review. *J Clin Imaging Sci*. 2016; 6:24. doi: [10.4103/2156-7514.184244](https://doi.org/10.4103/2156-7514.184244)
- Nathan CL, Emmert BE, Nelson E, Berger JR. CNS fungal infections: A review. *J Neurol Sci*. 2021; 422:117325. doi: [10.1016/j.jns.2021.117325](https://doi.org/10.1016/j.jns.2021.117325)
- Drummond RA. What fungal CNS infections can teach us about neuroimmunology and CNS-specific immunity. *Semin Immunol*. 2023; 67:101751. doi: [10.1016/j.smim.2023.101751](https://doi.org/10.1016/j.smim.2023.101751)
- Choi C. Bacterial Meningitis in Aging Adults. *Clin Infect Dis*. 2001; 33(8):1380–5. doi: [10.1086/322688](https://doi.org/10.1086/322688)

12. Pappas PG, Kauffman CA, Andes DR, Clancy CJ, Marr KA, Ostrosky-Zeichner L, et al. Clinical Practice Guideline for the Management of Candidiasis: 2016 Update by the Infectious Diseases Society of America. *Clin Infect Dis*. 2016; 62(4):e1–50. doi : [10.1093/cid/civ933](https://doi.org/10.1093/cid/civ933)
13. Bloch KC, Bailin SS. Update on fungal infections of the central nervous system: emerging pathogens and emerging diagnostics. *Curr Opin Infect Dis*. 2019; 32(3):277–84. doi : [10.1097/QCO.0000000000000541](https://doi.org/10.1097/QCO.0000000000000541)
14. Voice RA, Bradley SF, Sangeorzan JA, Kauffman CA. Chronic Candidal Meningitis: An Uncommon Manifestation of Candidiasis. *Clin Infect Dis*. 1994; 19(1):60–6. doi : [10.1093/clinids/19.1.60](https://doi.org/10.1093/clinids/19.1.60)
15. Chen M, Chen C, Yang Q, Zhan R. Candida meningitis in neurosurgical patients: a single-institute study of nine cases over 7 years. *Epidemiol Infect*. 2020; 148:e148. doi : [10.1017/S0950268820001144](https://doi.org/10.1017/S0950268820001144)
16. Sánchez-Portocarrero J, Pérez-Cecilia E, Corral O, Romero-Vivas J, Picazo JJ. The central nervous system and infection by Candida species. *Diagn Microbiol Infect Dis*. 2000; 37(3):169–79. doi : [10.1016/S0732-8893\(00\)00140-1](https://doi.org/10.1016/S0732-8893(00)00140-1)
17. Blatzer M, Lanternier F, Latgé J, Beauvais A, Bretagne S, Chrétien F, et al. Fungal Infections of the CNS. In: *Infections of the Central Nervous System*. Wiley; 2020. p. 419–36. doi : [10.1002/9781119467748.ch44](https://doi.org/10.1002/9781119467748.ch44)
18. Khaba MC, Ngale TC, Makhado NA. Fungal infection of the central nervous system: Autopsy analysis of six cases. *SAGE Open Med Case Reports*. 2022 ; 10:2050313X2211224. doi : [10.1177/2050313X221122419](https://doi.org/10.1177/2050313X221122419)
19. Turgut M, Challa S, Akhaddar A. Fungal Infections of the Central Nervous System. *Handbook of Clinical Neurology*. Cham, Switzerland: Springer International Publishing; 2019. doi : [10.1007/978-3-030-06088-6](https://doi.org/10.1007/978-3-030-06088-6)
20. Wang AY, Machicado JD, Khoury NT, Wootton SH, Salazar L, Hasbun R. Community-Acquired Meningitis in Older Adults: Clinical Features, Etiology, and Prognostic Factors. *J Am Geriatr Soc*. 2014; 62(11):2064–70. doi : [10.1111/jgs.13110](https://doi.org/10.1111/jgs.13110)
21. Delorme S, Castro S, Viallon A, Boutoille D, Bendahou M, Riou B, et al. Meningitis in elderly patients. *Eur J Emerg Med*. 2009; 16(5):273–6. doi : [10.1097/MEJ.0b013e3283101866](https://doi.org/10.1097/MEJ.0b013e3283101866)